

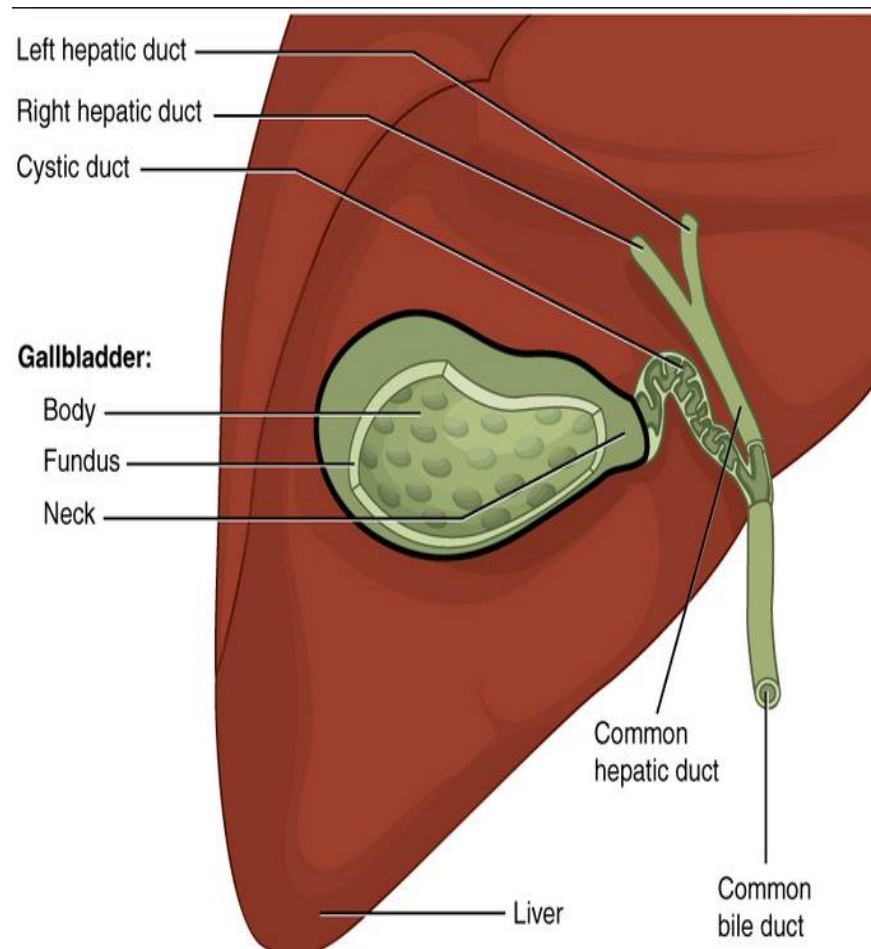
# Gallbladder Disease

Sha-Ron Jackson-Johnson, MD

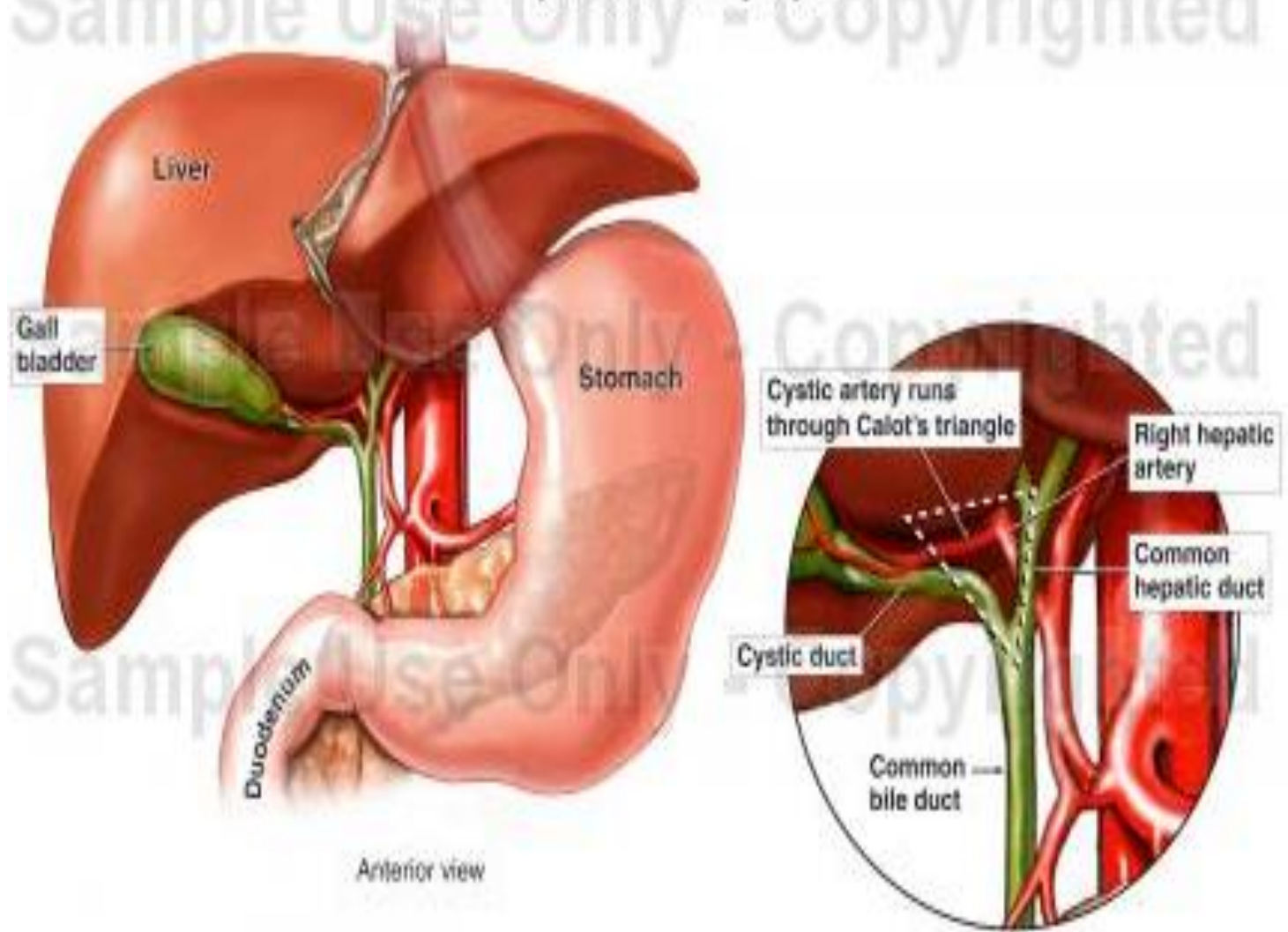
Clinical Instructor of Surgery

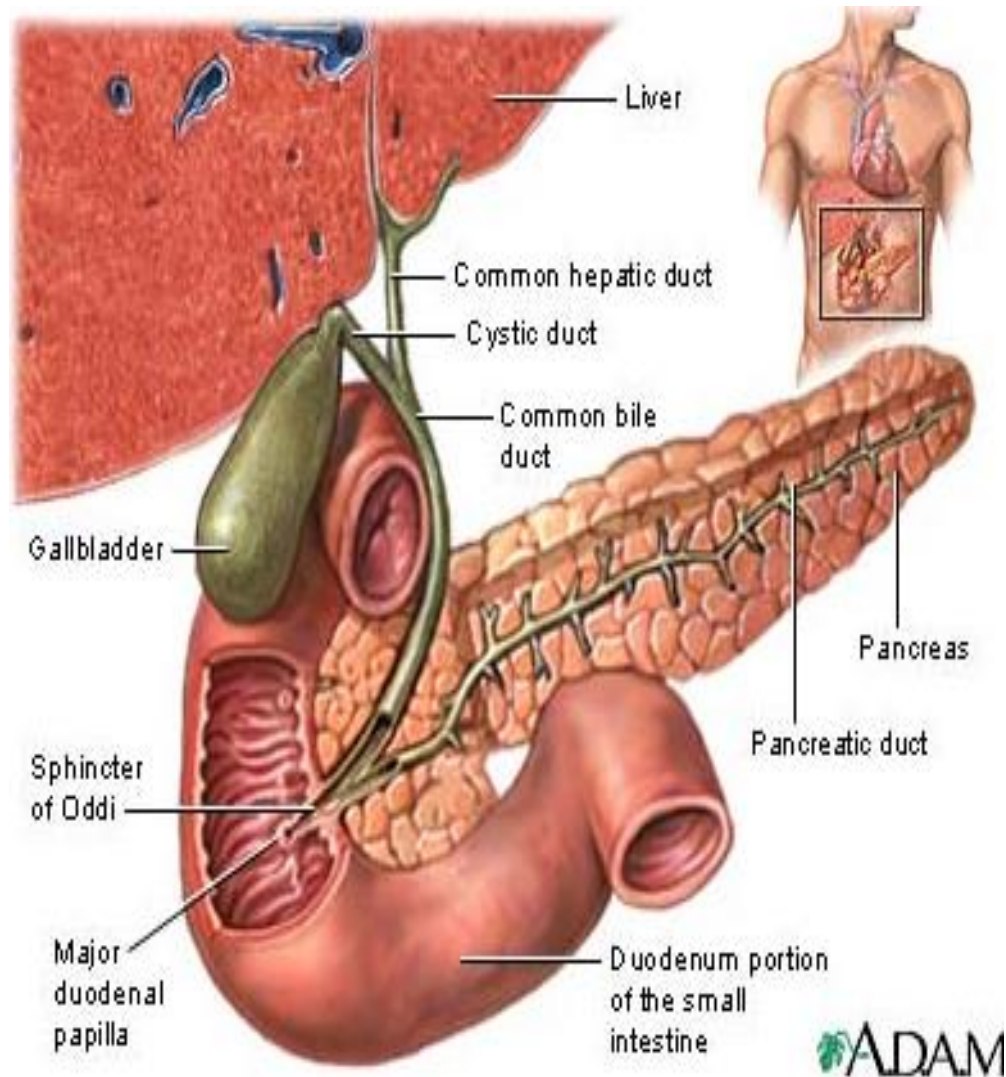
University of Cincinnati

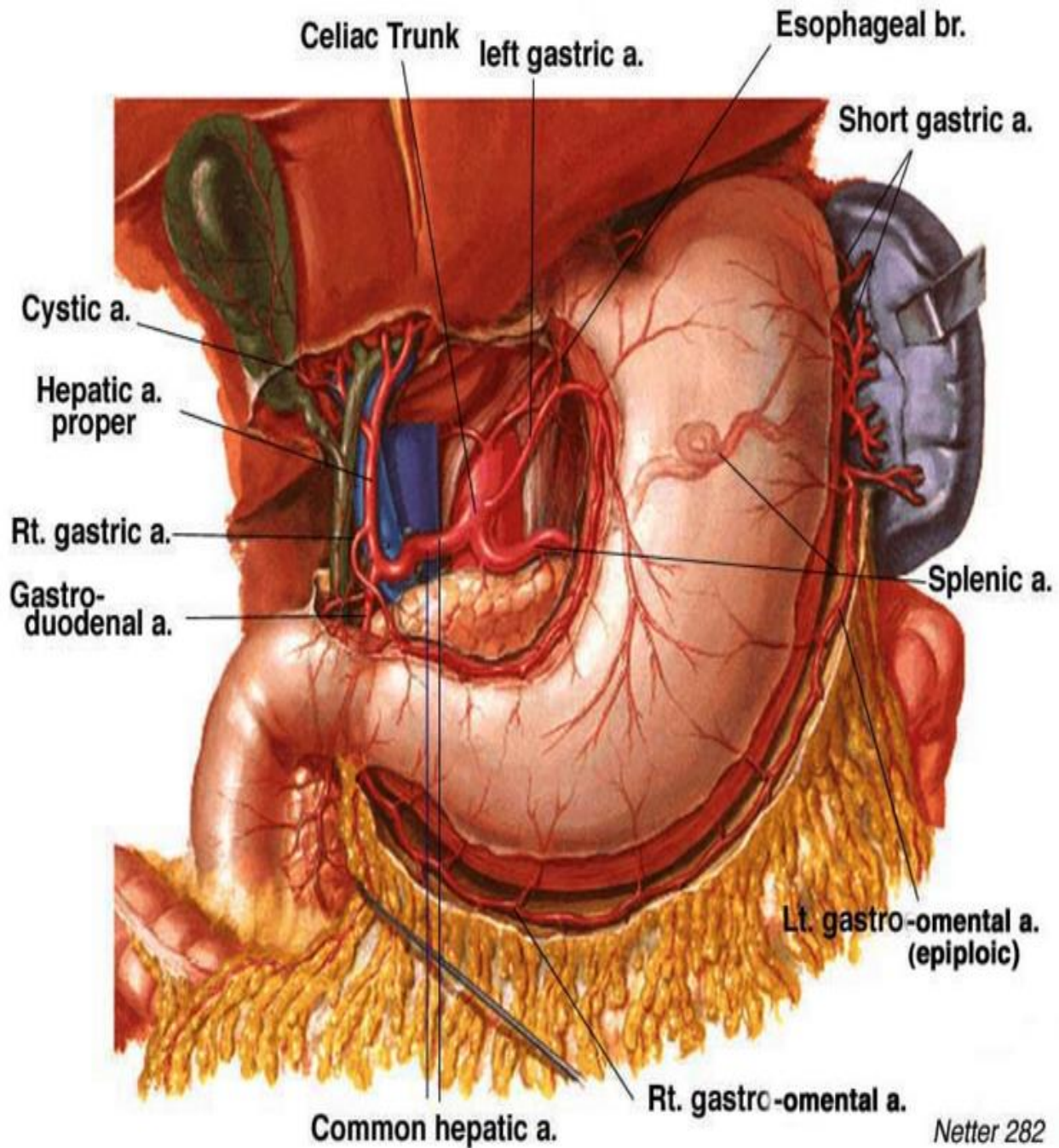
# Anatomy



# Anatomy of the Biliary System





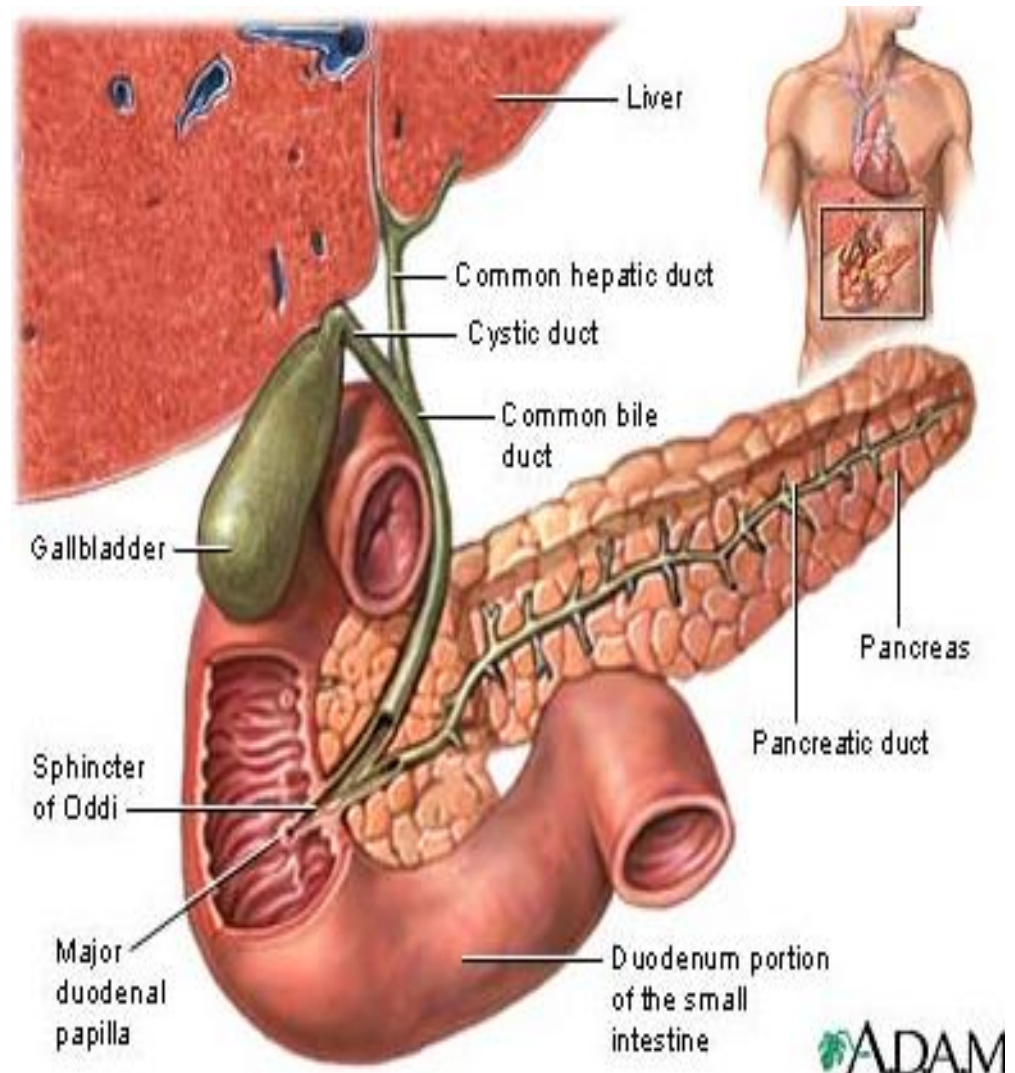


# Epidemiology

- Prevalence of gallstones from 11-36% in cadaver studies
- 1/3 will be symptomatic
- Women 3x more likely to form stones
- 1<sup>st</sup> degree relatives 2x more likely to form stones
- Obesity
- Pregnancy
- Dietary factors
- Crohn's Disease
- Terminal ileal resection
- Hereditary spherocytosis, SSD and thalassemia

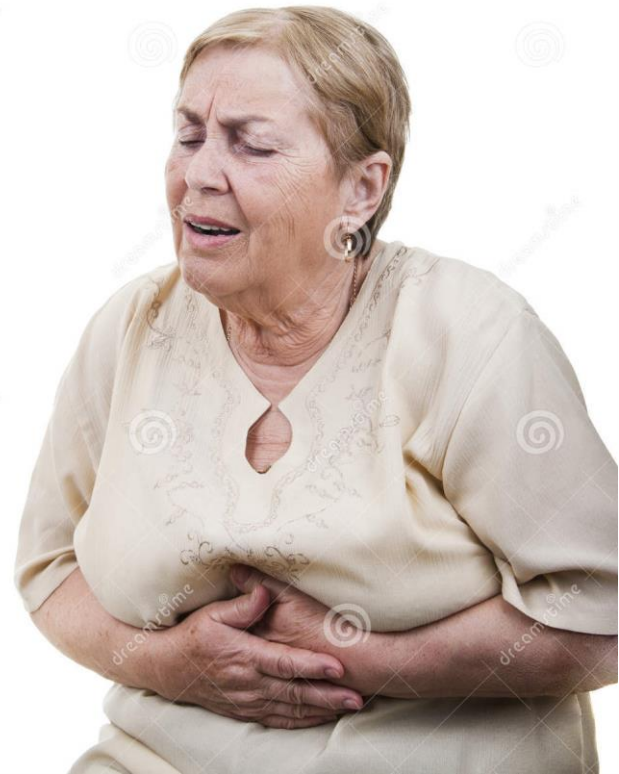
# Pathology

- Biliary Colic
- Acute Cholecystitis
- Acalculous Cholecystitis
- Choledocholithiasis
- Ascending Cholangitis
- Biliary Dyskinesia
- Gallstone Pancreatitis
- Mirizzi syndrome
- Choledochal Cysts\*
- Gallbladder Cancer
- Gallstone Ileus



# Case Presentation

- Senora Martinez; 70 year old woman
- Multiple medical problems
- 30 hours RUD abdominal pain and subjective fever
- Numerous prior episodes of postprandial RUQ pain
- Temp 38.5, normal VS
- Soft adomen, well healed midline scar, RUQ TTP with cessation of inspiration



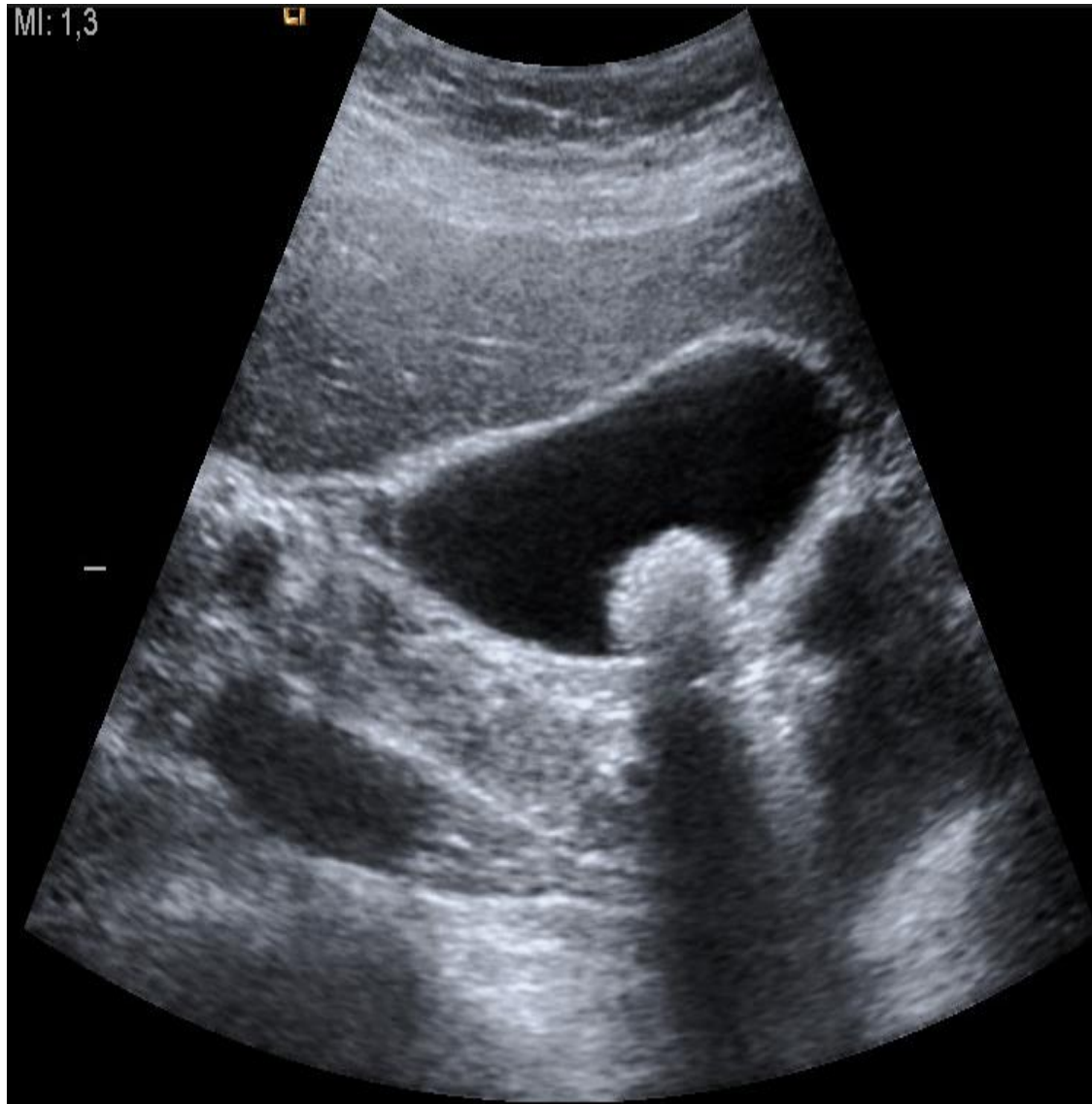


# Right Upper Quadrant Pain

Work up:

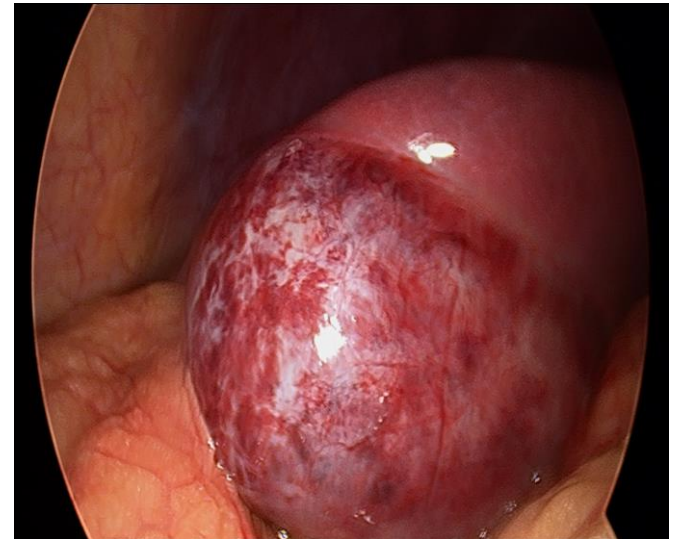
- WBC with differential, CMP, AST, ALT, Alkaline phosphatase, bilirubin, Lipase
- US
  - Gallbladder wall thickening ( $> 4\text{mm}$ )
  - Pericholecystic fluid
  - Evaluation of the Common Bile Duct

US



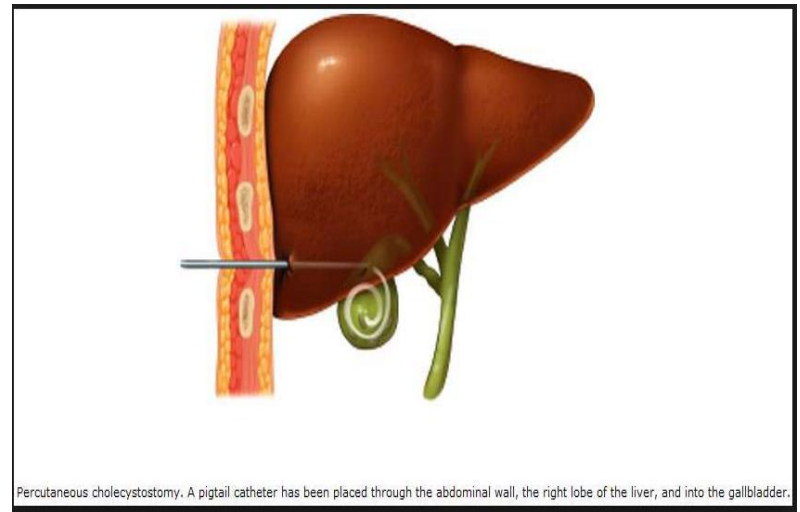
# Acute Cholecystitis

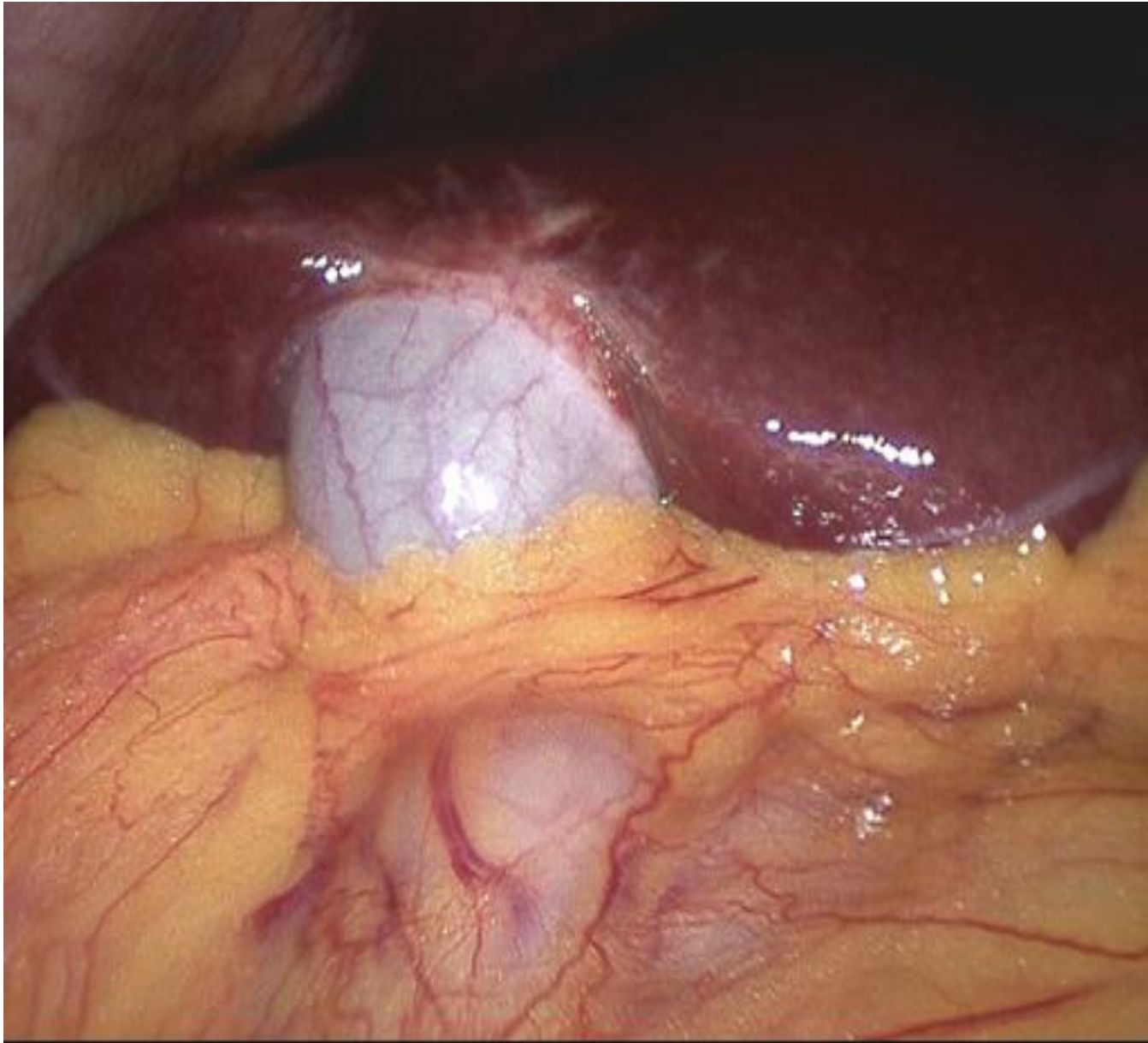- Most common organisms
  - E. Coli
  - Enterococcus
  - Klebsiella
- When to do the surgery
  - Early vs Delayed
  - Within 72 hours of onset of symptoms

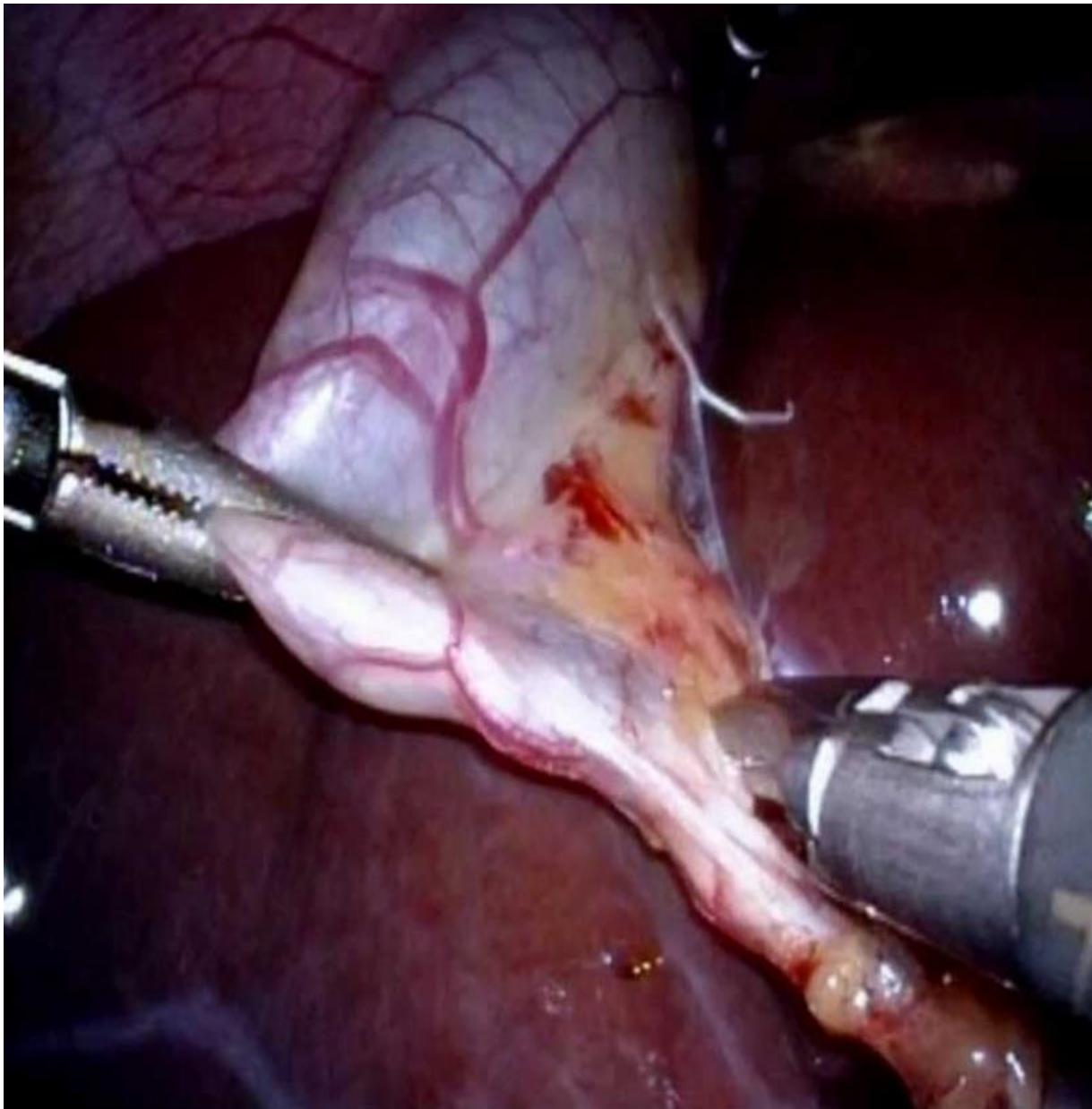


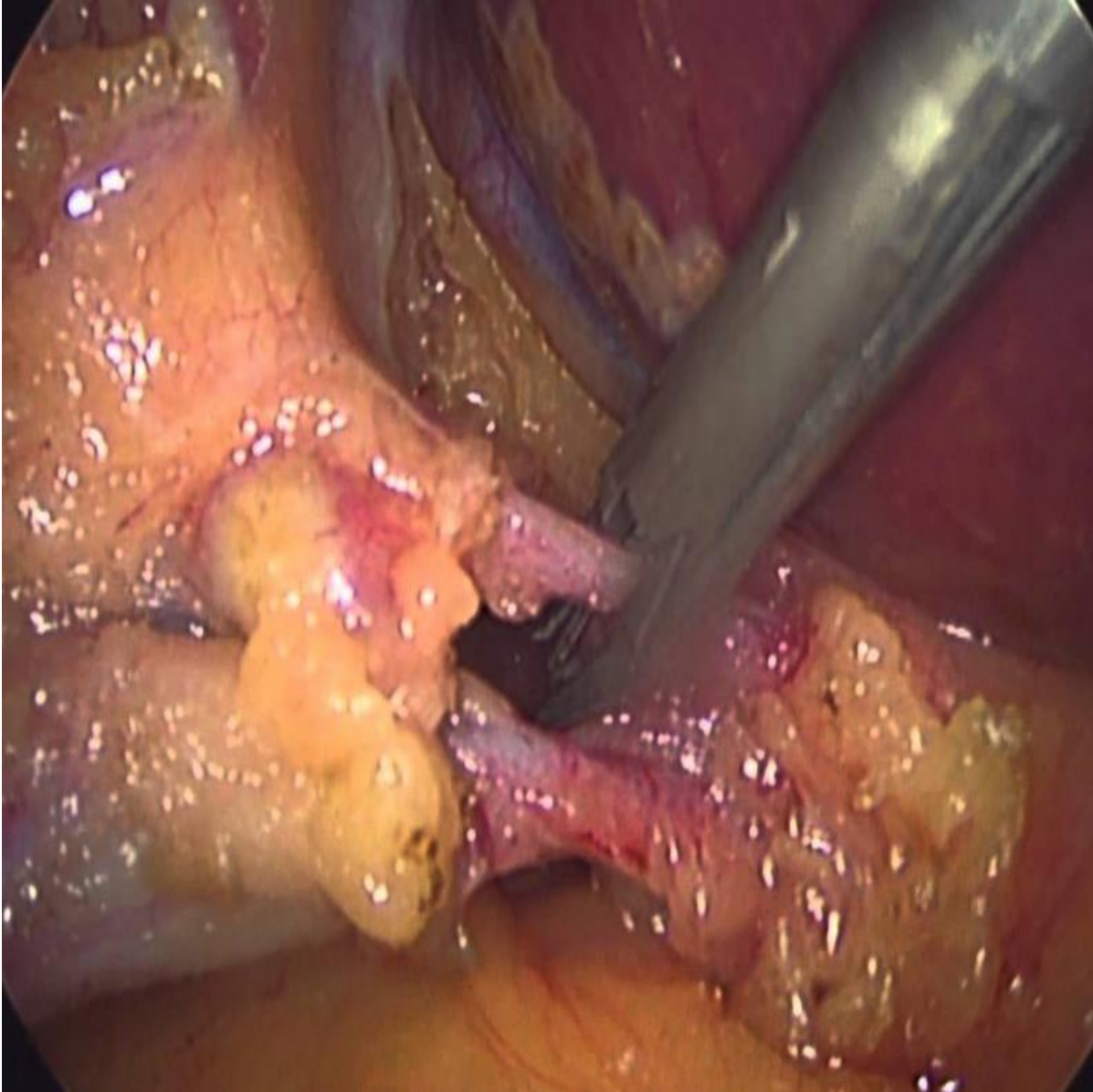
# Treatment

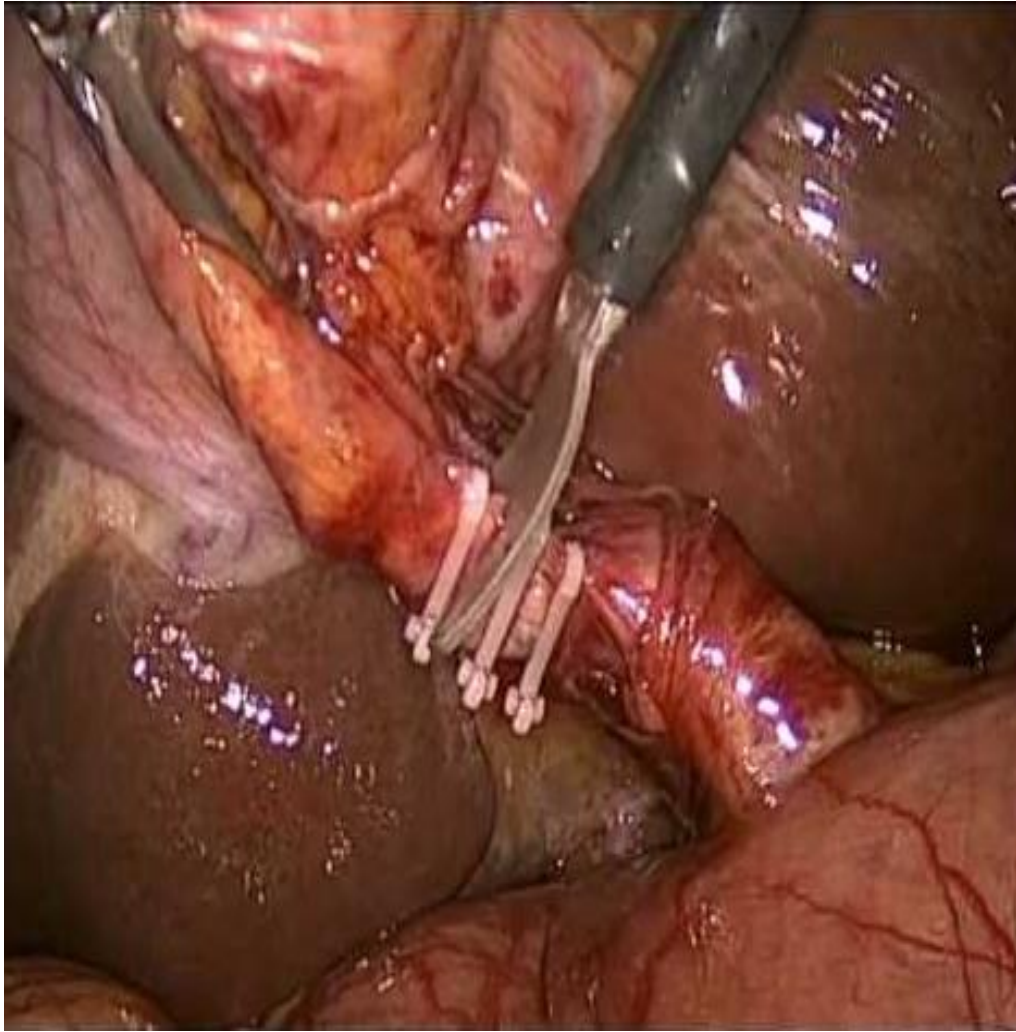
- Laparoscopic Cholecystectomy
- Open Cholecystectomy
- Cholecystostomy Tube







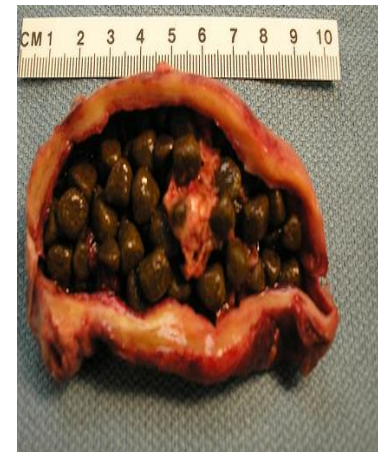
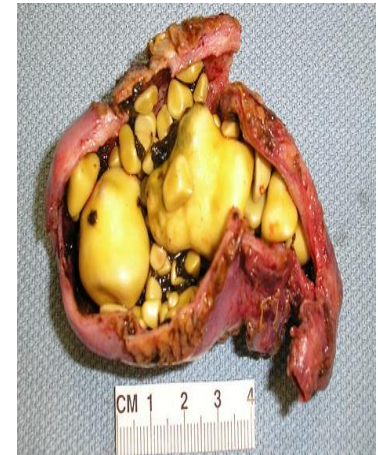




# Types of Gallstones

- Primary Stones
  - BROWN –
    - Infection
      - Stasis, E coli+, parasites in Asia
    - In the Common Bile Duct (strictures, stones)
- Secondary Stones
  - Light –
    - Cholesterol based, supersaturation
    - Large
  - Dark (pigmented)
    - Bilirubin
    - Small
    - Associated with hemolytic disorders

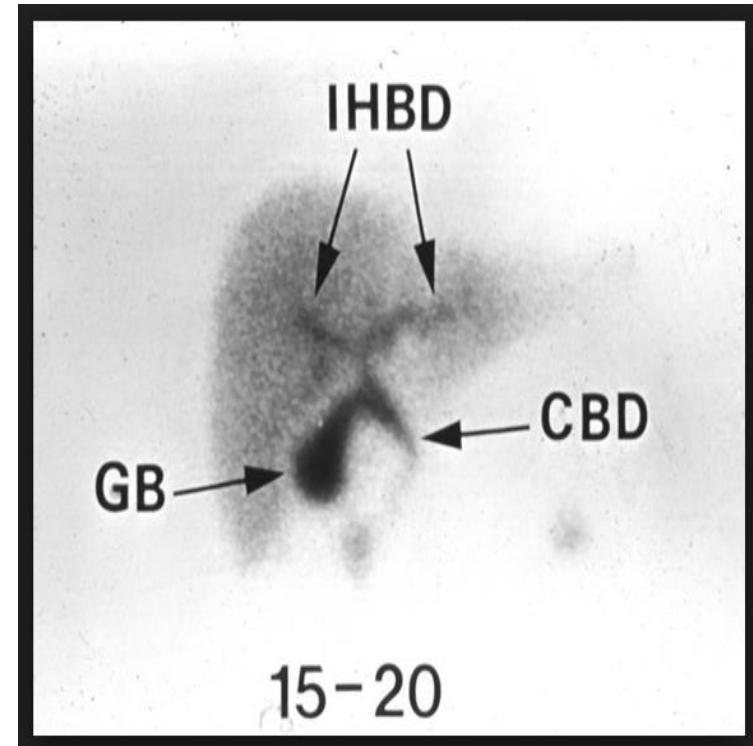



# On the other hand...

- Senora Martinez has no gallbladder wall thickening or pericholecystic fluid on ultrasound, but her history and physical supports your diagnosis. Is there another test that might help?



# HIDA Scan – Hepatobiliary Iminodiacetic Acid Ejection Fraction



Non filling of the gallbladder is approximately 95 % sensitive and specific for acute cholecystitis.

# Alternatively...

- Senora Martinez is admitted to the hospital on Saturday in preparation for the OR Monday. Her morning labs demonstrate a newly elevated bilirubin, she is persistently TTP in the RUQ, and despite antibiotics her WBC is now 19K. She is confused and mildly hypotensive. What's the diagnosis and best next step?




# Ascending Cholangitis

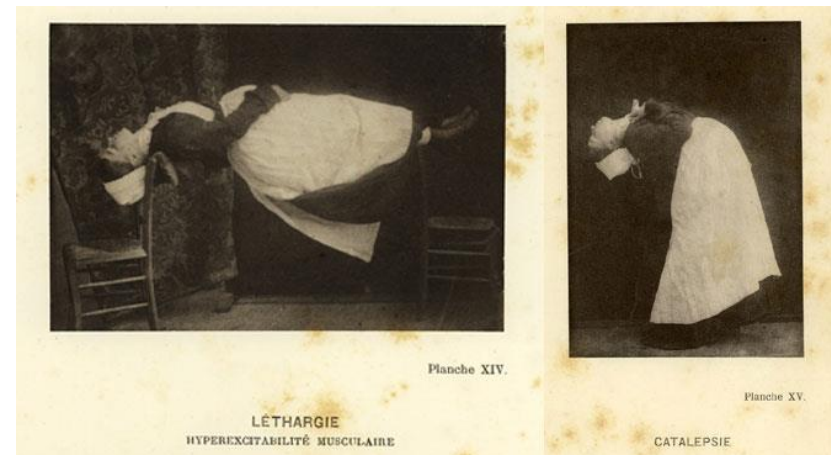
- Charcot's Triad
  - Jaundice
  - Fever
  - RUQ abdominal pain
- Reynold's Pentad
  - Altered mental status
  - Shock

## Treatment

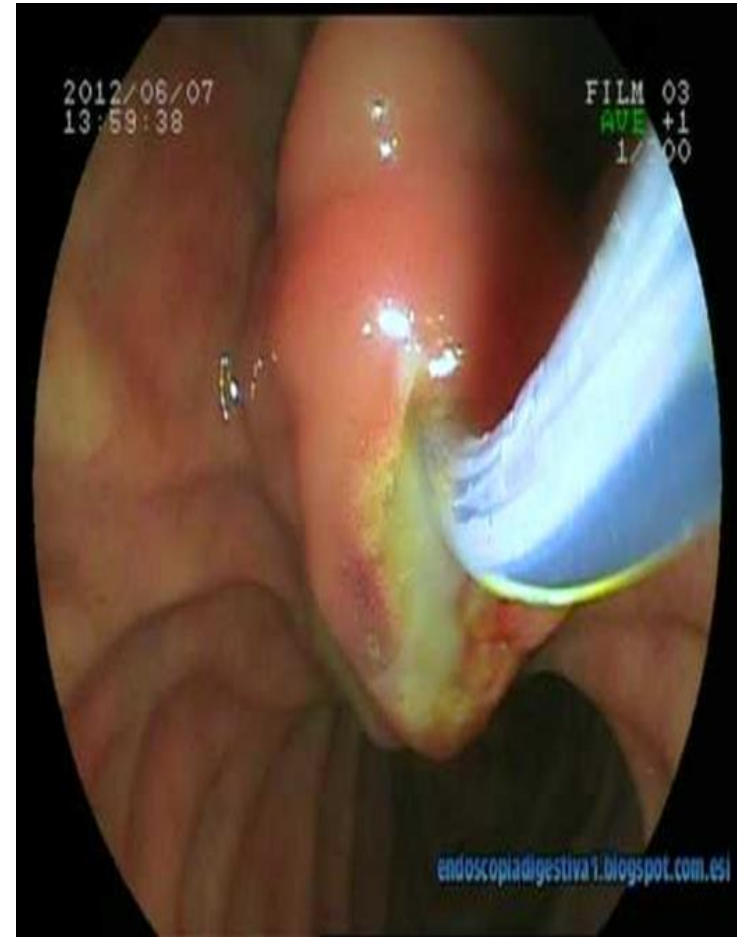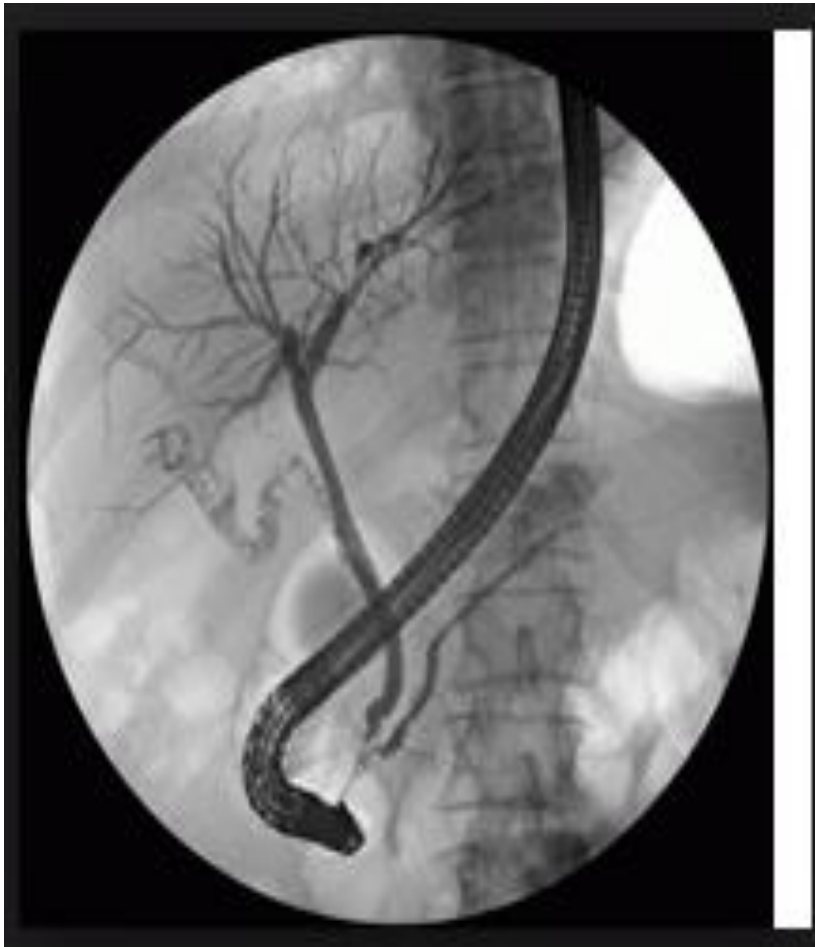- Resuscitation in ICU setting
- Antibiotics
- **Immediate** Biliary Drainage
  - ERCP with stent or sphincterotomy
  - PTC (percutaneous transhepatic drainage) in poor procedural candidate



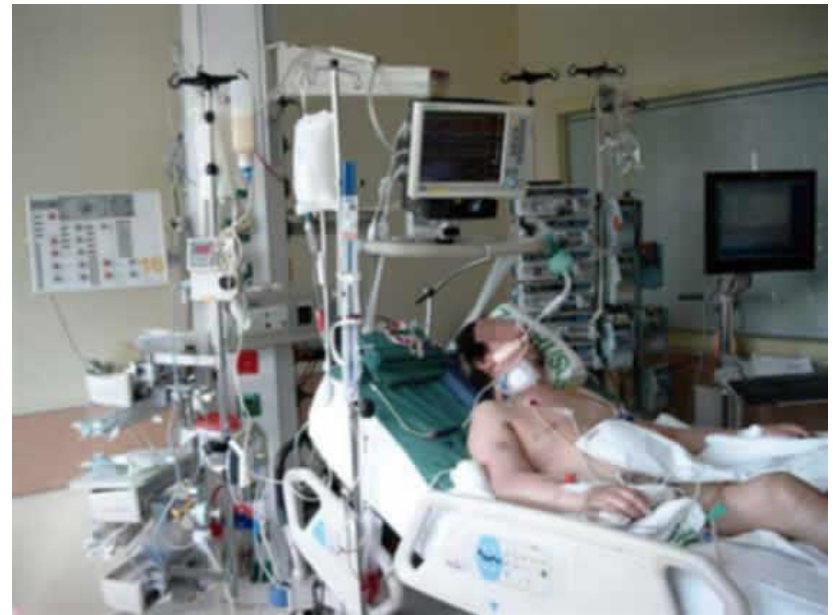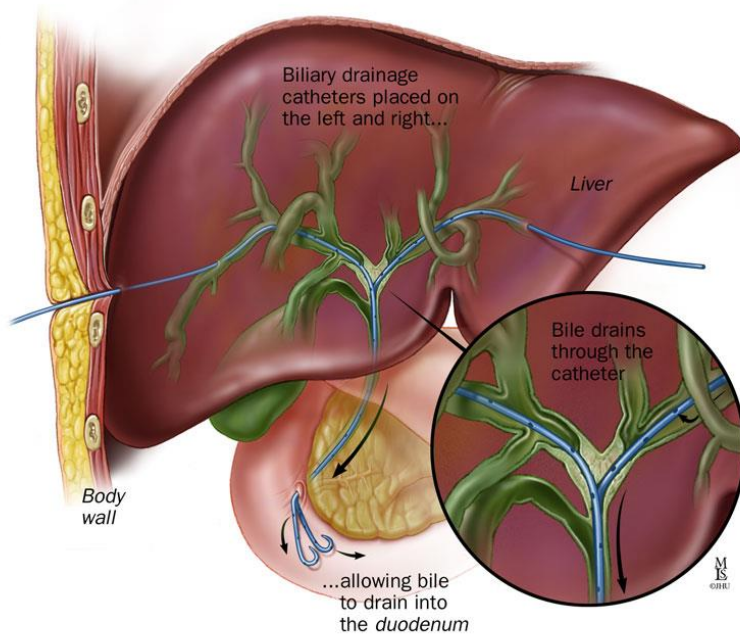
Jean-Martin Charcot French Neurologist



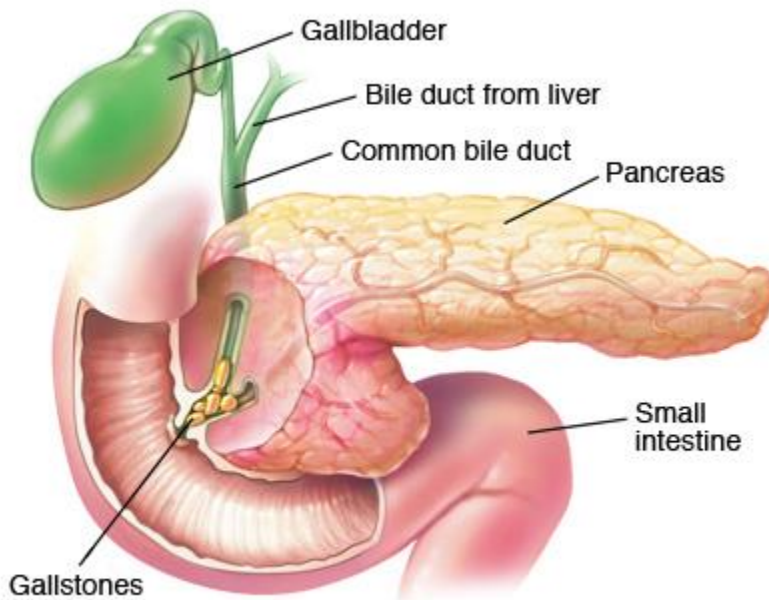
# ERCP – Endoscopic Retrograde Cholangiopancreatography



# PTC – Percutaneous Transhepatic Cholangiography



# Gallstone pancreatitis



© MAYO FOUNDATION FOR MEDICAL EDUCATION AND RESEARCH. ALL RIGHTS RESERVED.

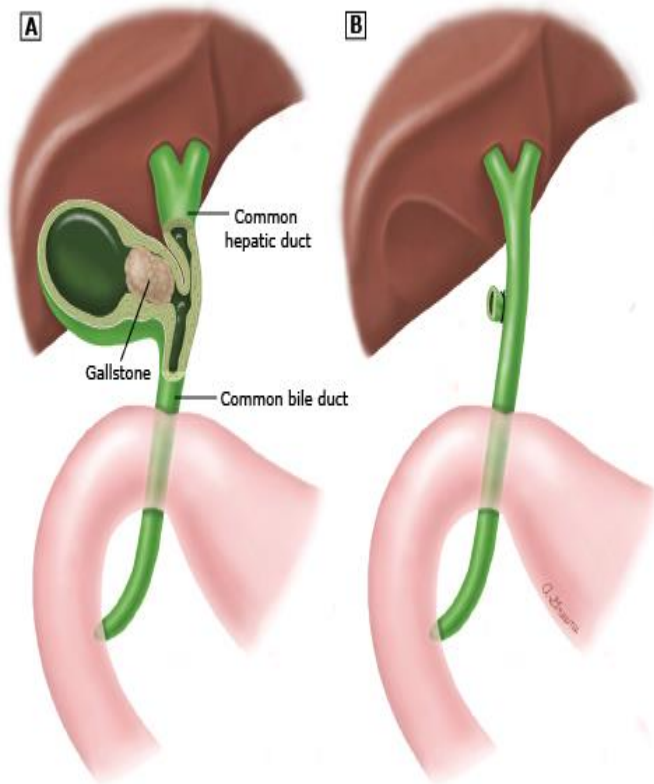
- One of the most common causes of pancreatitis in US (40-60% of cases)
- Mild pancreatitis
  - Lap chole during same admission
  - ERCP if not surgical candidate
- Severe pancreatitis
  - ICU admission for optimal medical management



# Mirizzi syndrome

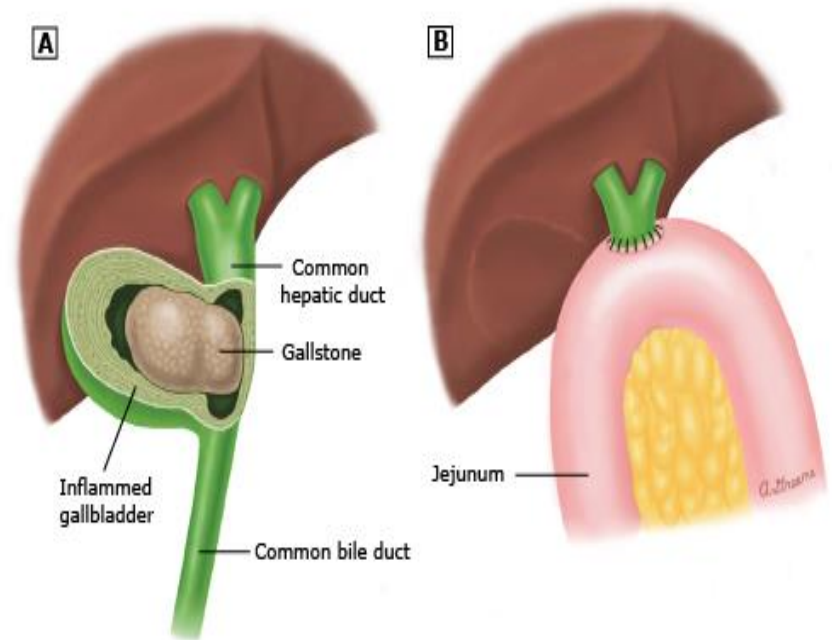
Mirizzi syndrome with compression of the common hepatic duct by an impacted stone

---



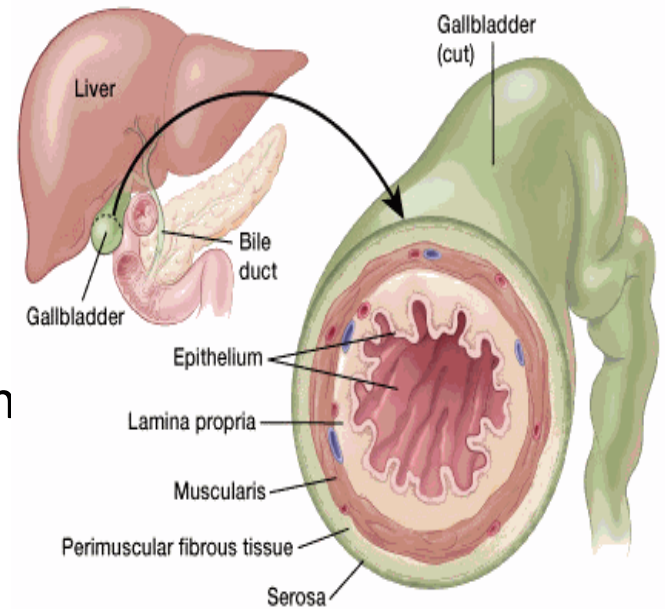
Mirizzi syndrome with erosion of the stone into the common hepatic duct

---



# Gallbladder Cancer

- **T0:** There is no evidence of primary tumor.
- **Tis:** Cancer cells are only found in the epithelium
  - *carcinoma in situ.*
- **T1:**
  - **T1a:** Tumor has grown into lamina propria.
  - **T1b:** Tumor has grown into the muscularis.
- **T2:** Perimuscular fibrous tissue.
- **T3:** The tumor has grown through the serosa
- **T4:** The tumor has grown into one of the main blood vessels leading into the liver or Tumor has grown into a structure other than the liver.

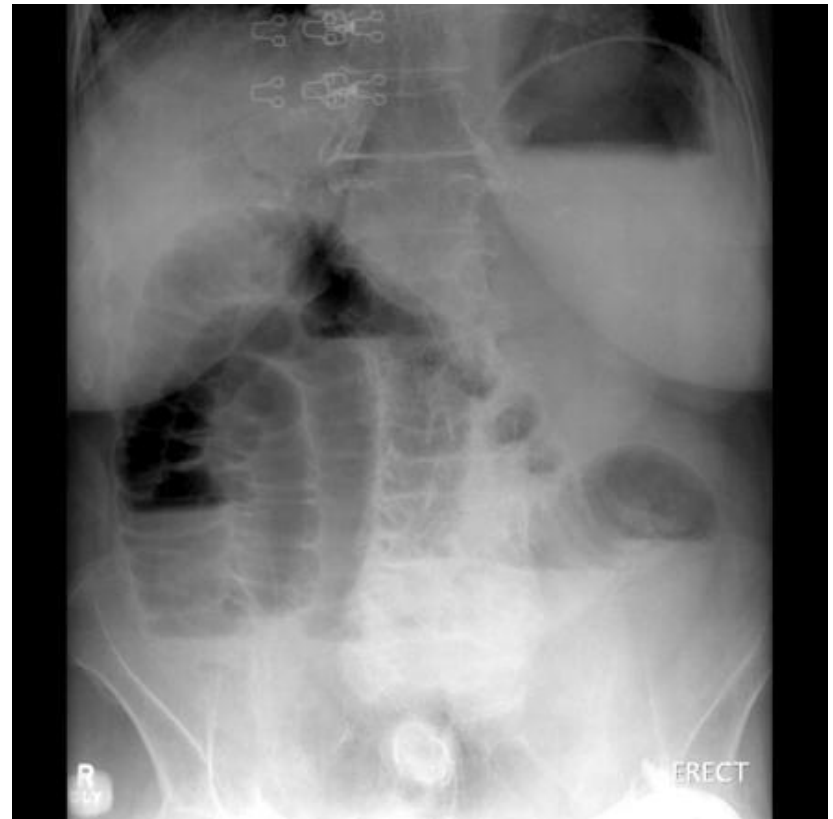


# Gallbladder Cancer

- Overall 5-year survival is <5%
- Treatment -
  - **T1a – Cholecystectomy – 5 year survival 78%**
  - T1b – Cholecystectomy +/- Radical liver resection
  - T2 – Cholecystectomy + Radical Liver resection and lymphadenectomy
- If margins positive need to resect
  - Gallbladder wall
  - Cystic Duct
- Node positive – Radiation +/- Chemotherapy
- Metastatic Disease – Chemotherapy and Radiation have little effect

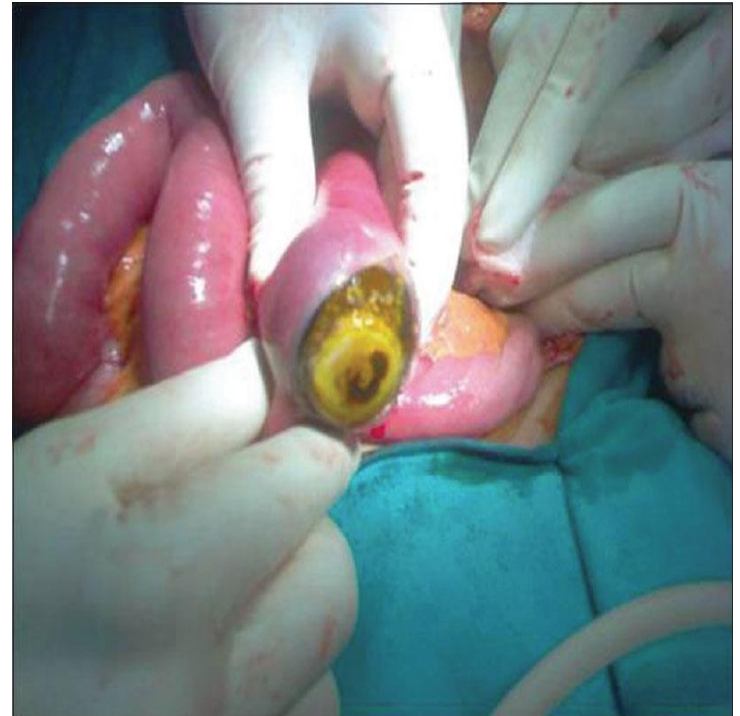# A final interesting case...

- 75 year old woman presents with nausea, vomiting, and abdominal pain.
- PMHx includes “gallbladder issues”, HTN, GERD and irritable bowel syndrome. No surgeries.
- ED obtains this film and calls for a surgical consult.



# Gallstone Ileus

- Fistula from the Gallbladder into the bowel lumen.
- Resuscitate.
- Laparotomy and stone extraction via an enterotomy just proximal to point of obstruction.
- Close enterotomy transversely.
- Interval cholecystectomy



# Questions?

