

Anorectal Disease

Cincinnati Colon and Rectal Surgeons


May 23, 2012

Or: It's my hemorrhoids, Doc

-- NOT!

LONDON'S TIMES ©2000

RICK LONDON/DALE SIMPSON



NOT NEARLY AS POPULAR AS ITS
PREDECESSOR, MR POTATO BUTT
DEBUTED AND DIED SHORTLY THEREAFTER.

In What Way Are Your Hemorrhoids Bothering You?

- Pain
- Bleeding
- Itching/burning
- Swelling
- Drainage
- Incontinence/leakage

Has anything you've done made it better?

- Hot soaks
- Ice
- Laxatives
- Creams
- Hygiene
- Sitting on a tennis ball

Inspection: Look First!

- Quality of the skin
- Skin color
- Contours
- Lumps/bumps
- Tears/ulcers

Examination of the Perineum

- External thrombosis
- Prolapse
- Abscess
- Sentinel Tag and Fissure
- Warts
- Cancers
- Pruritus
- Incontinence

Palpation

Explain what you're going to do

Spread skin/evert anus first

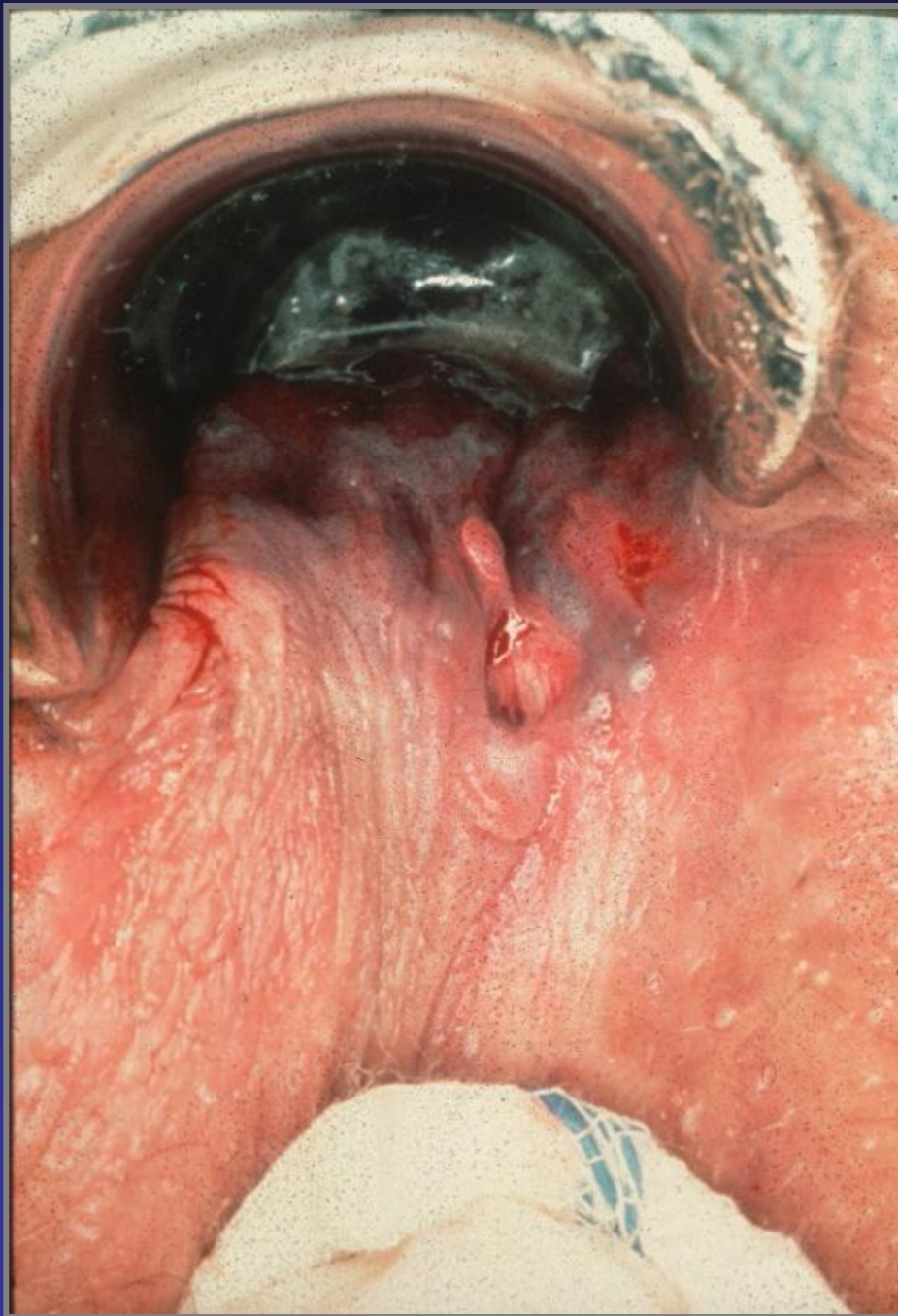
Then... and only then... insert a
finger

Gently!

Auscultation

24 y.o. anxious female

- Pain with bowel movements
- Blood on tissue
- I keep pushing the hemorrhoid up, and it just comes back down
- My hemorrhoids are blocking my bowels
- Stool is hard

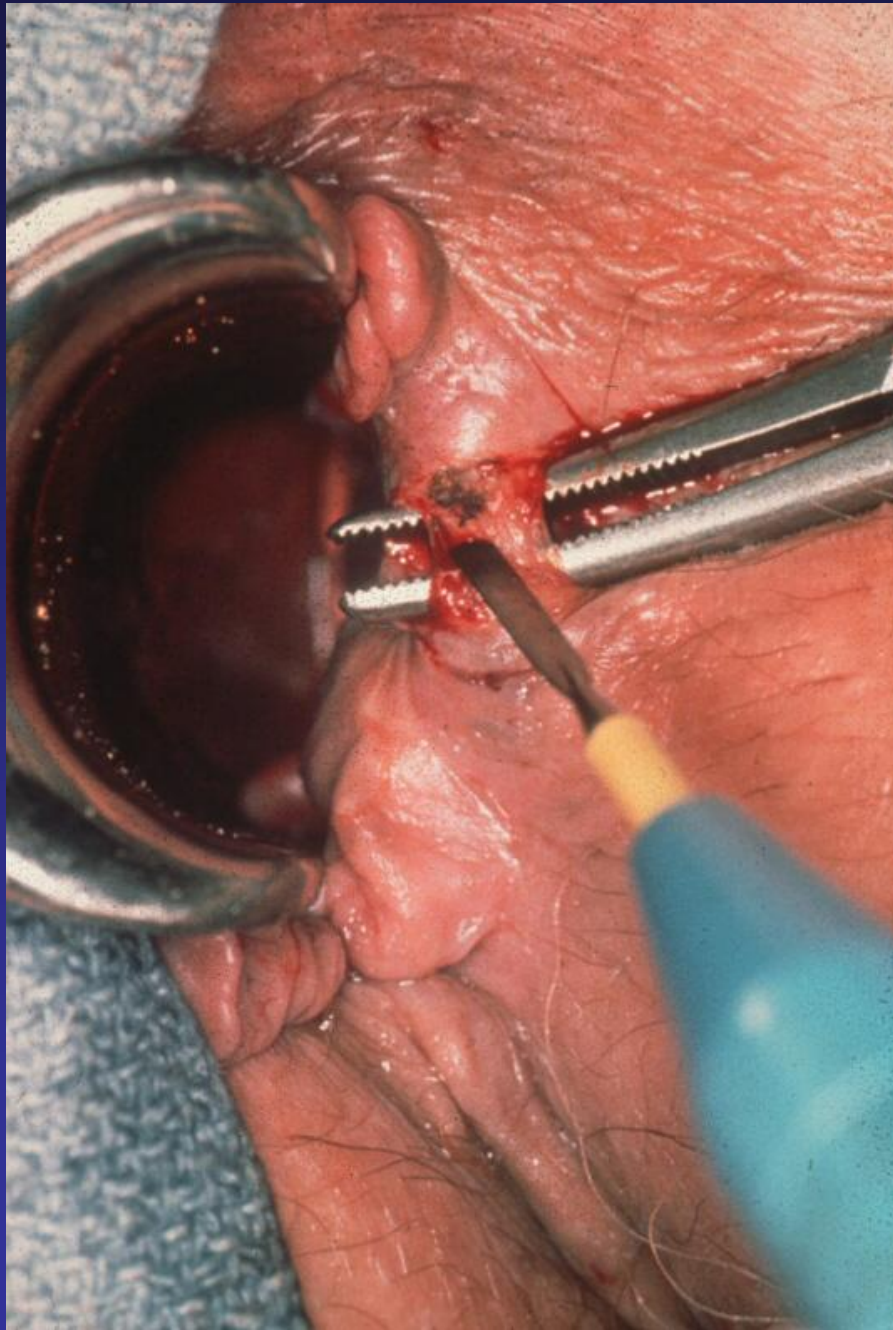


Anal fissure: Etiology

- Trauma
 - Hard stool
 - Diarrhea
 - Chronic straining
- Hypertonic or spastic internal sphincter
- Increased intra-anal pressure
- Decreased blood flow anterior/ posterior
- Ischemic ulcer

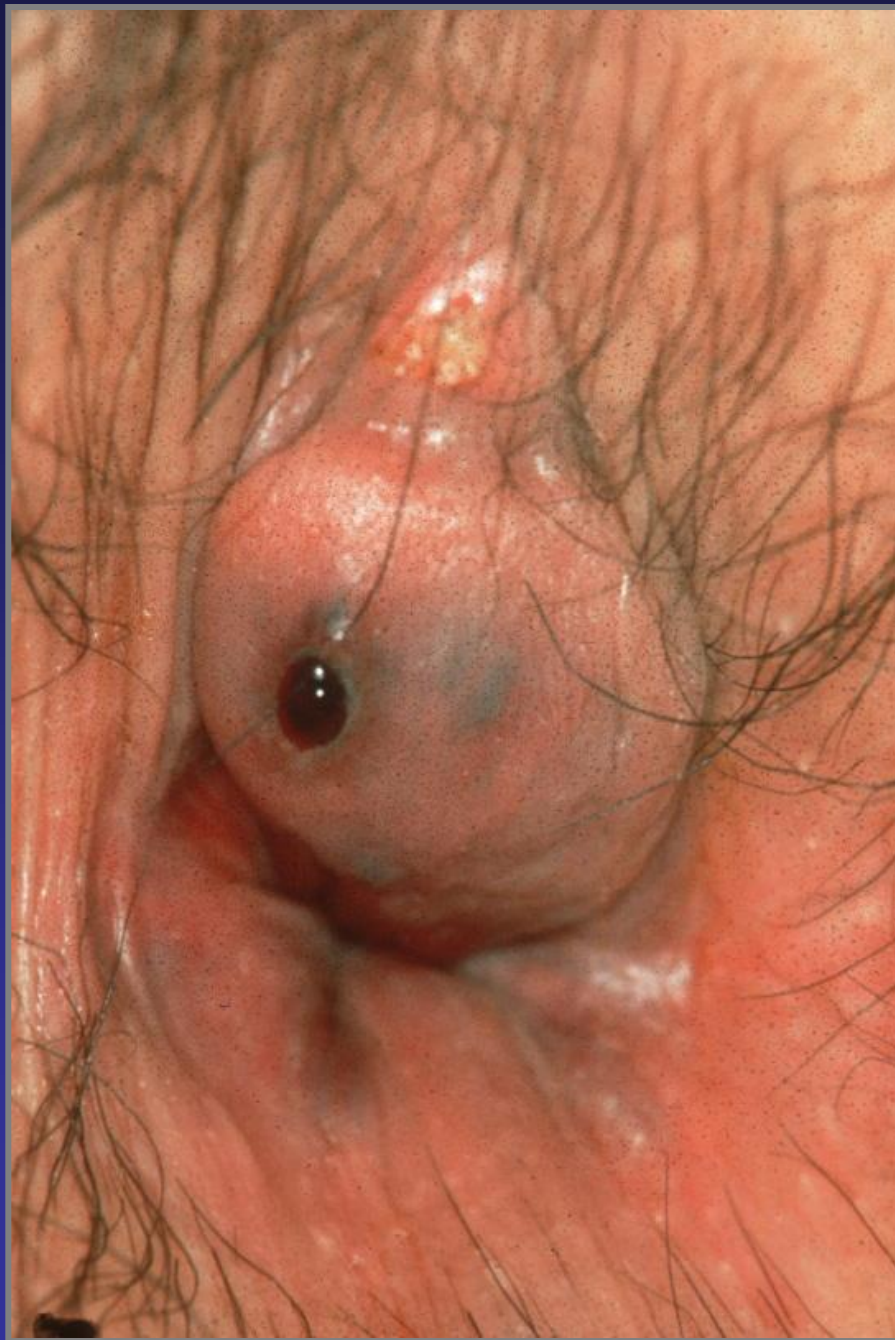Management of Anal Fissure

- Fiber supplement
- Warm tub soaks
- Anal nitroglycerine (0.2%)
- Topical nifedipine
- Botox
- Lateral internal sphincterotomy

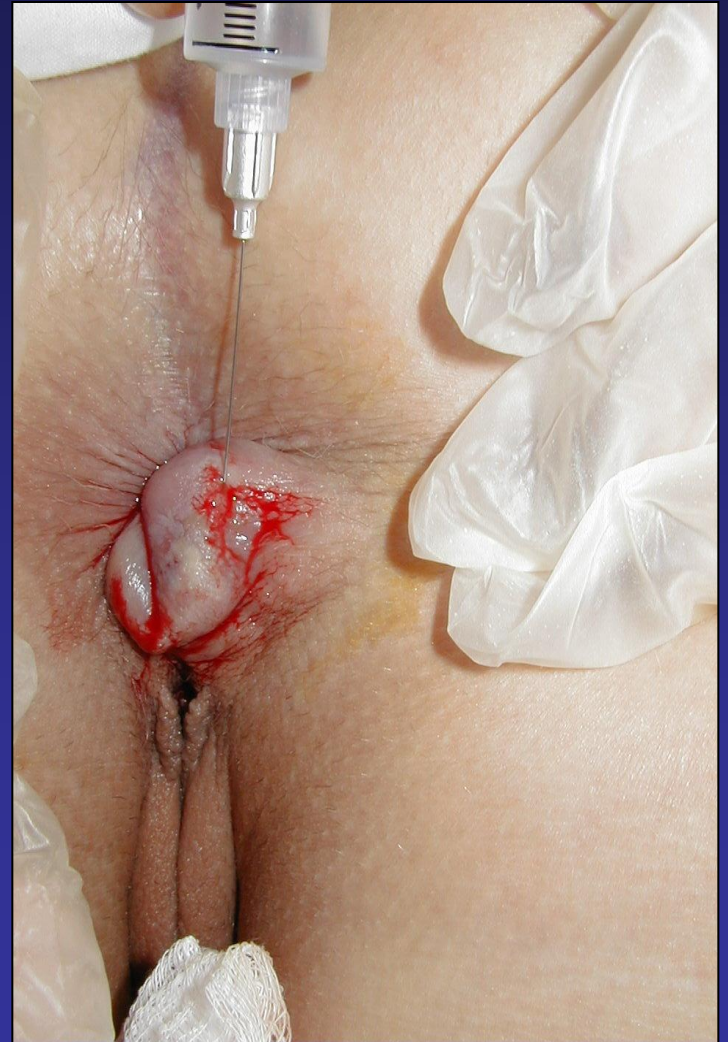
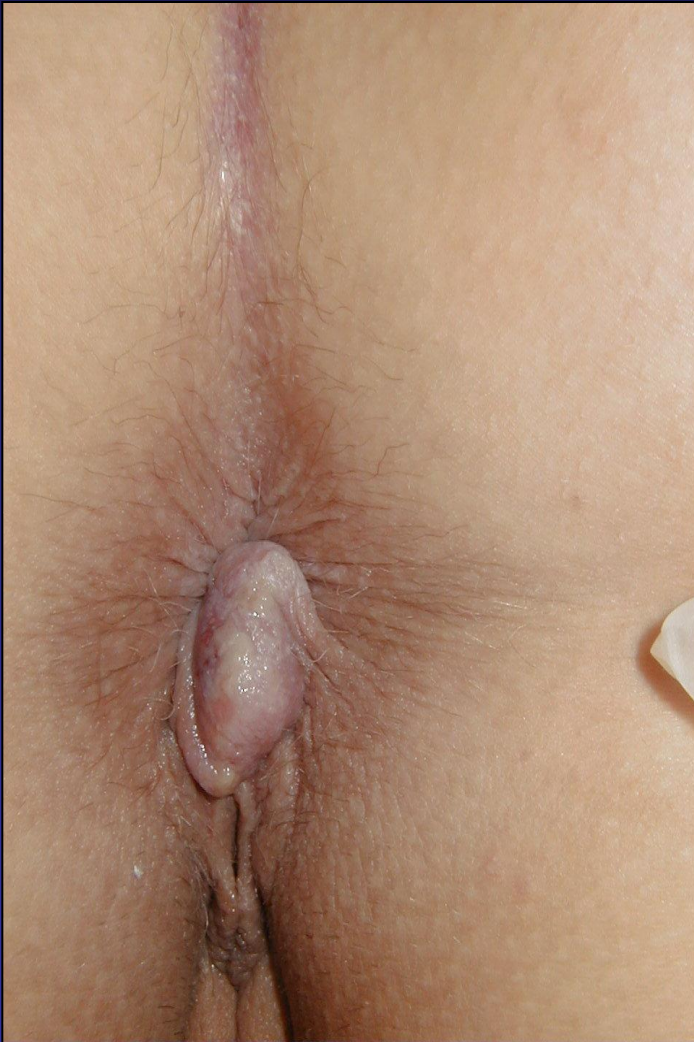
45 y.o. female

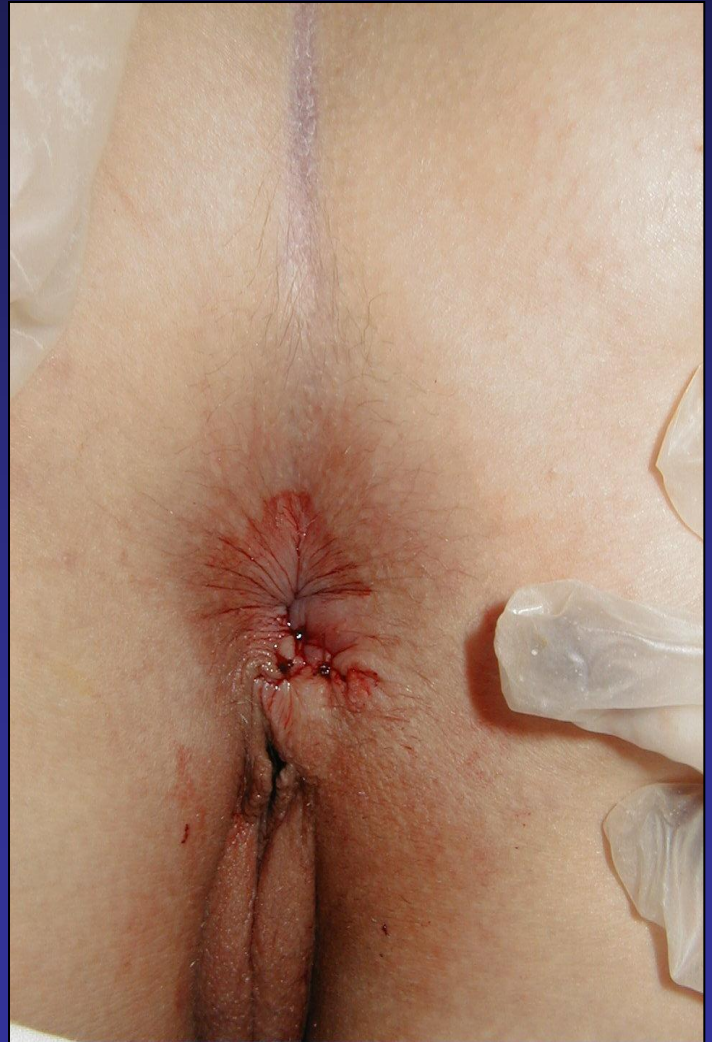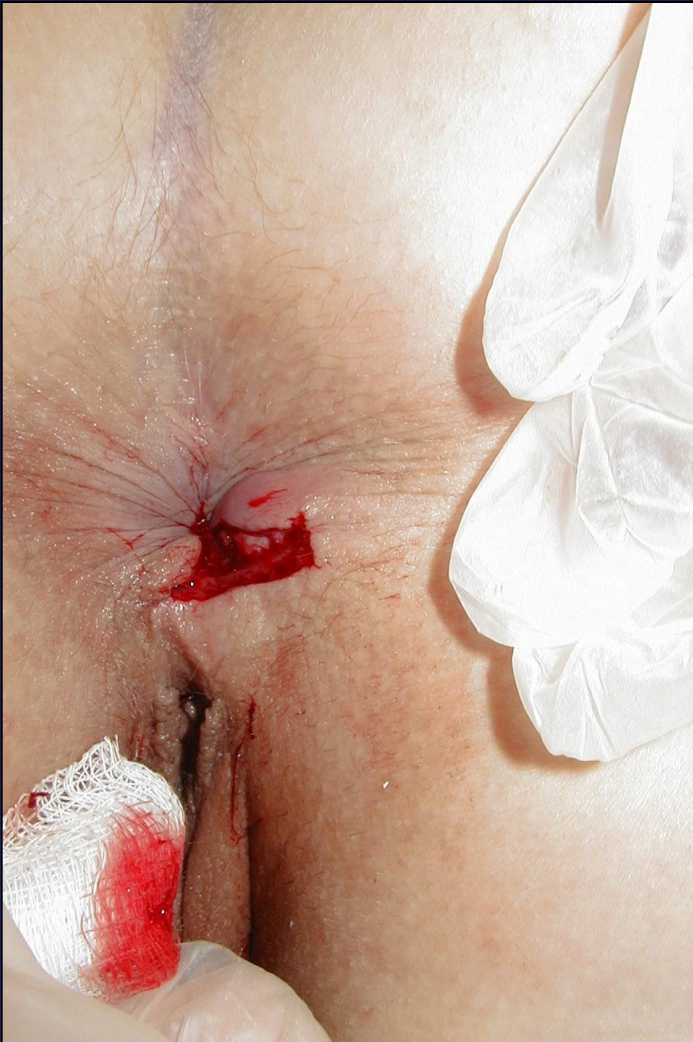- Spent Saturday raking leaves, planting bulbs
- Sunday morning woke with painful anal swelling
- Prep H hasn't helped.



Thrombosed External



Thrombosed External

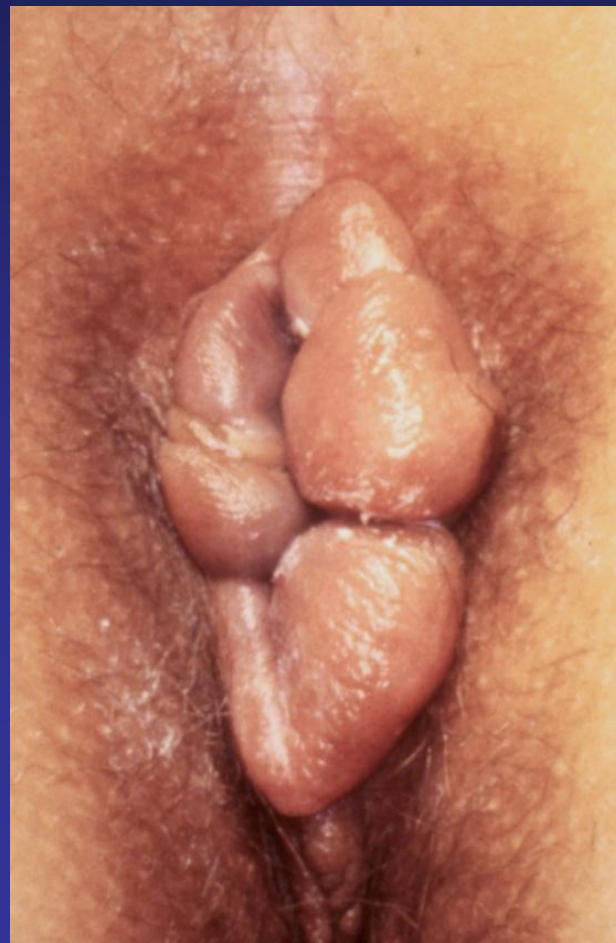

Acute Thrombosis: Management

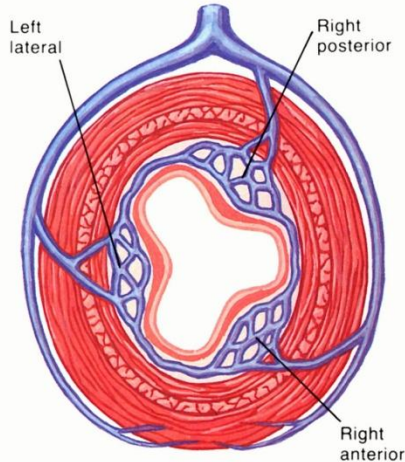
- Expectant
- Excision not incision
- Avoid mucocutaneous junction
- Warn of potential for non-healing wound or abscess

65 y.o. rectal bleeding

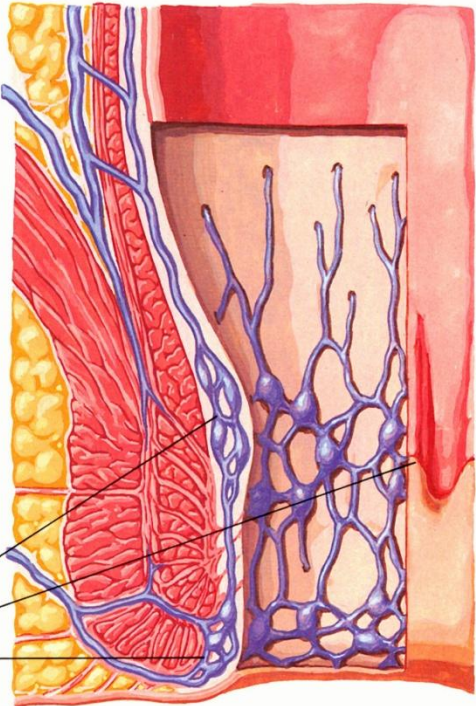
- 30 year history of protrusions with bowel movements
- Pushes the tissue back up each time
- Bleeding is painless
- Colonoscopy negative



Hemorrhoids

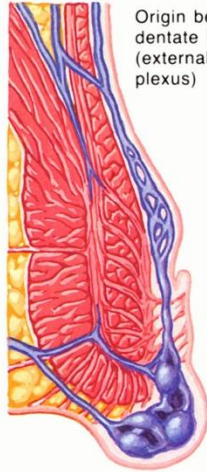


Usual position of internal hemorrhoids, or anal cushions

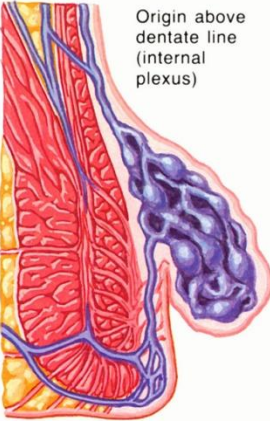


JOHN A. CRAIG M.D.
© CIBA

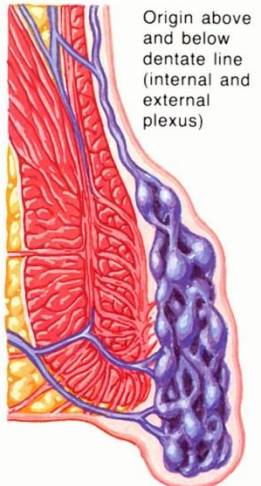
Types of hemorrhoids



External hemorrhoid



Internal hemorrhoid



Mixed hemorrhoid

Classification of Hemorrhoids

- Location
 - Internal
 - Sliding vascular pad
 - External
 - blood clot beneath skin
 - Mixed
- Vascular
 - Bleed not prolapse
- Mucosal
 - Protrude and prolapse

Internal Hemorrhoids

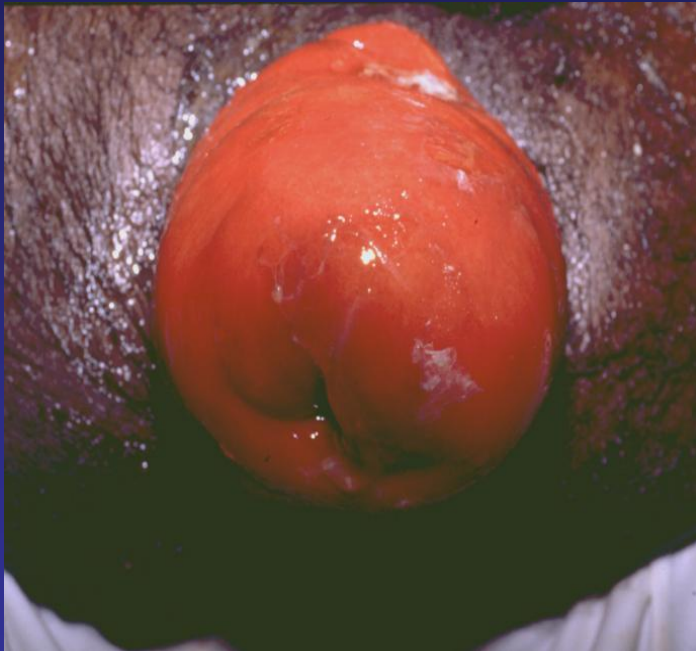
- 1° Bleeding
- 2° Bleeding and prolapse – Spontaneous reduction
- 3° Bleeding and prolapse – manual reduction
- 4° Irreducible prolapse

Must differentiate from Rectal Prolapse

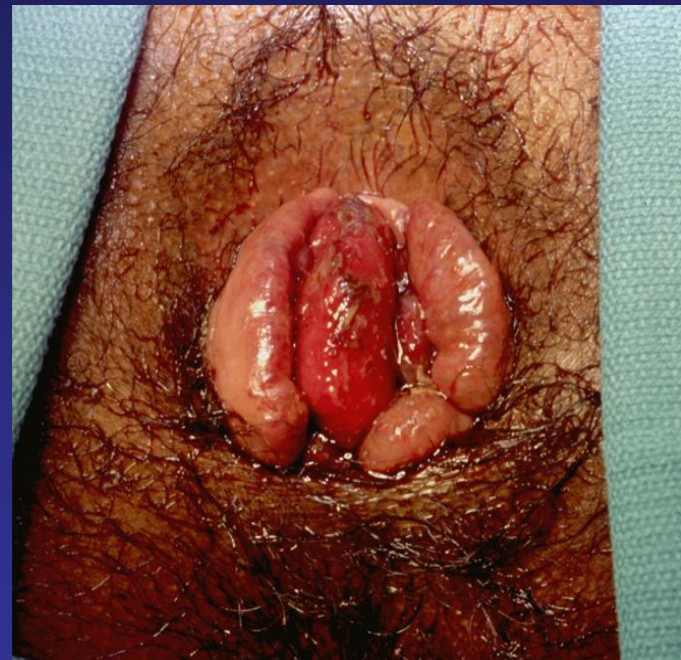
Common Anorectal Disorders

Rectal Prolapse *Evaluation*

Prolapse



Hemorrhoids



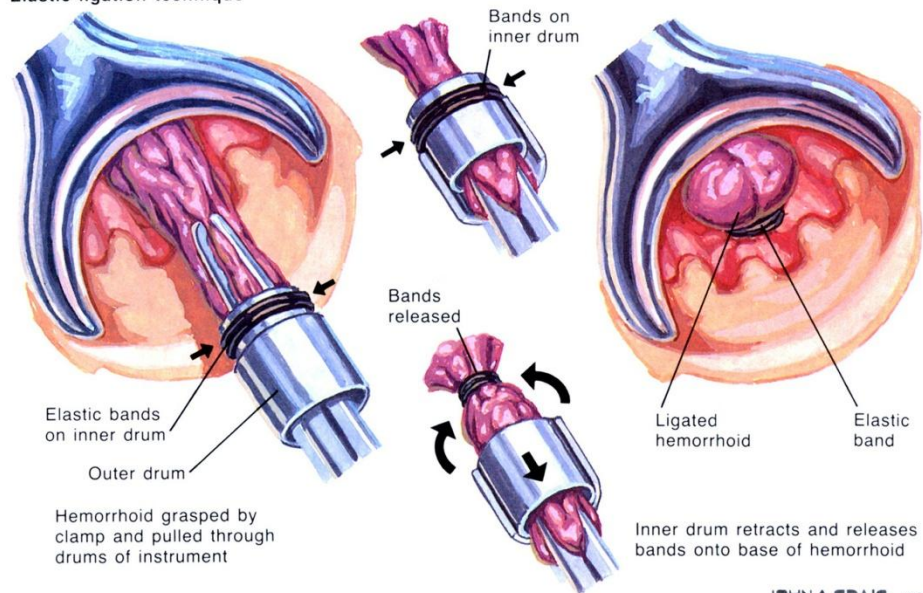
Examination on the commode may be crucial

Management

1° Hemorrhoids	Bowel regimen Sclerotherapy IRC
2° Hemorrhoids	Elastic ligation Excision (especially in patients on anticoagulation)
3° Hemorrhoids	Excision (traditional vs. new) Stapled hemorrhoidopexy
4° Hemorrhoids	Urgent surgical excision

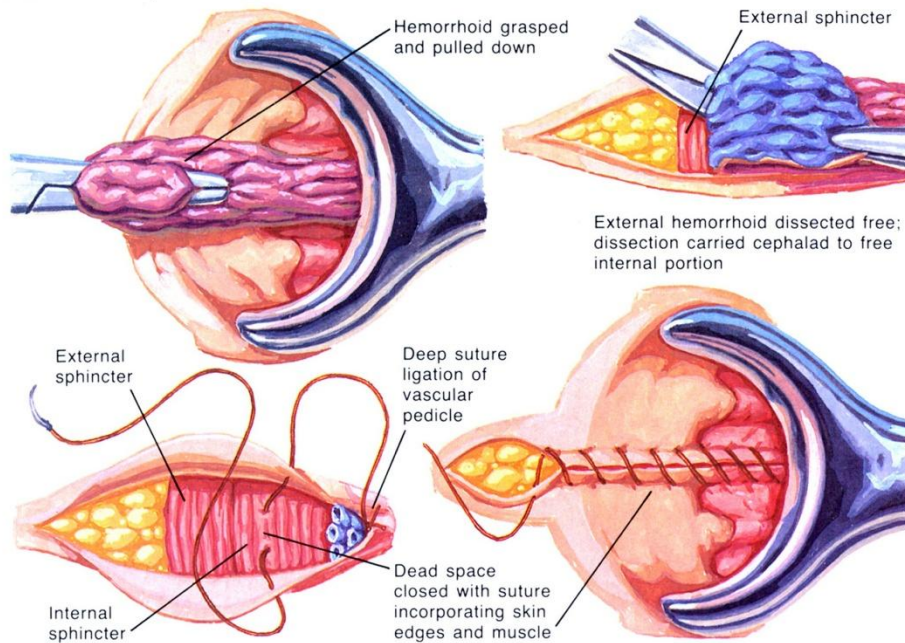
Surgical Management of Internal Hemorrhoids

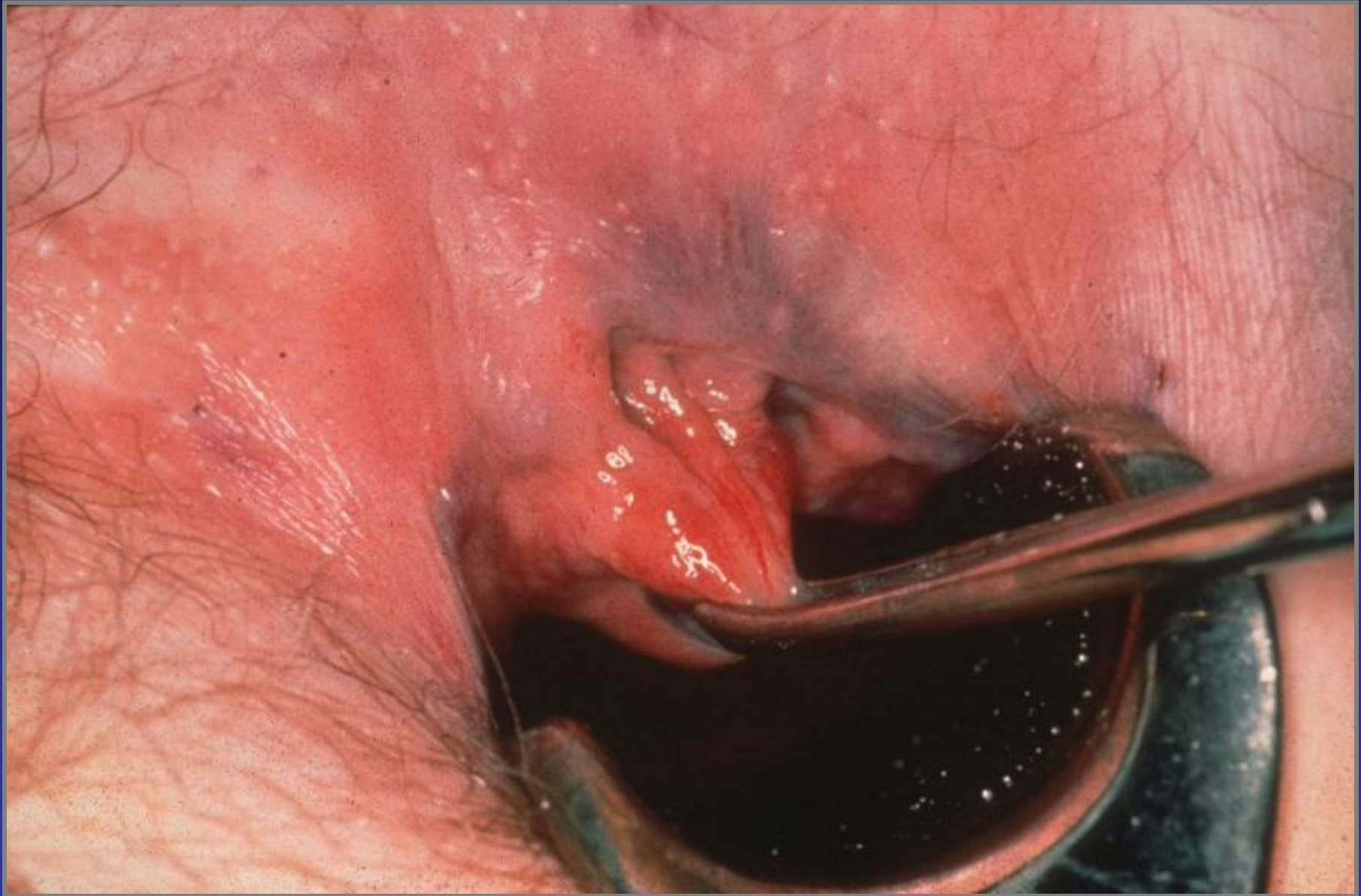
Elastic ligation technique

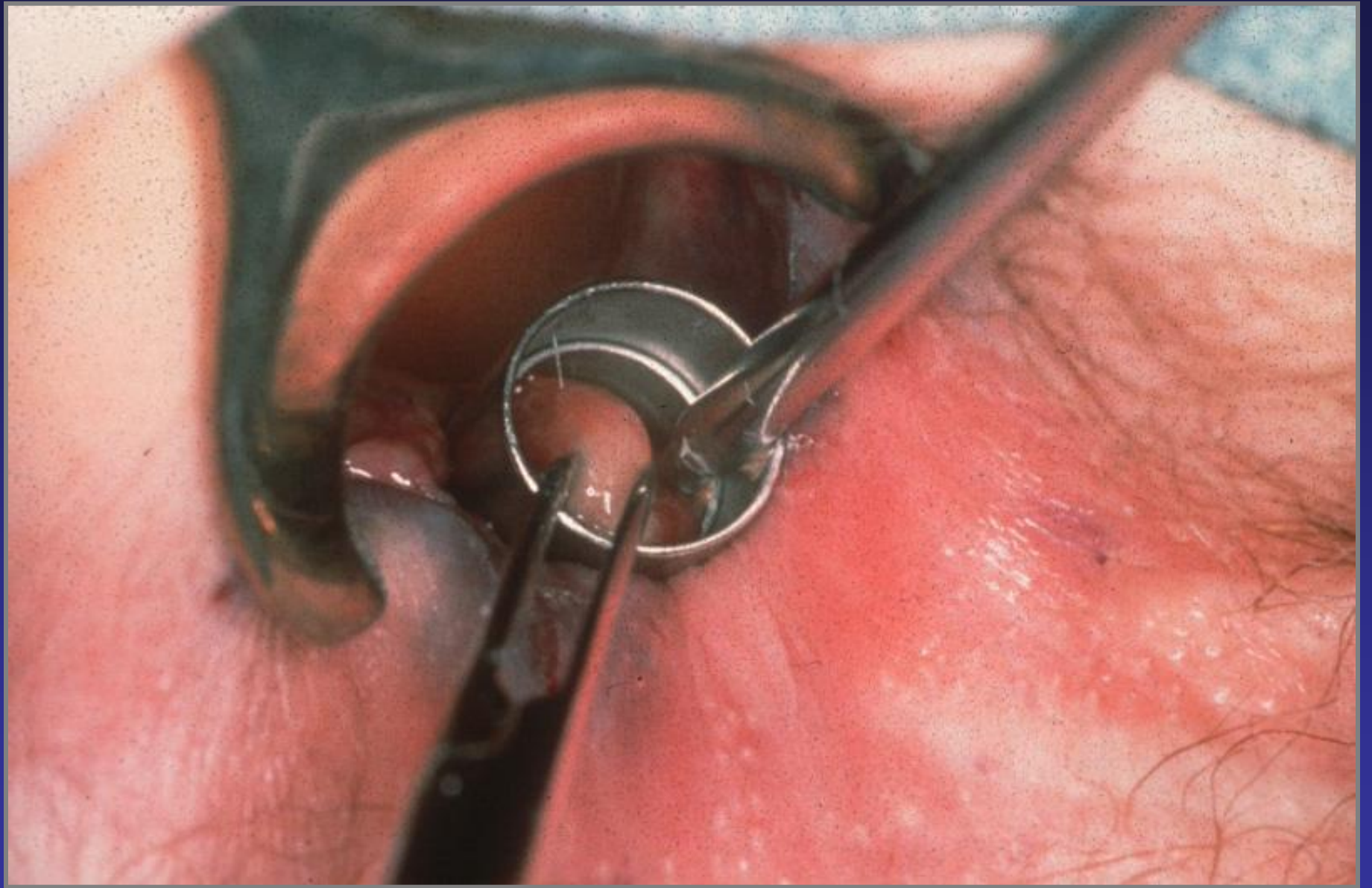


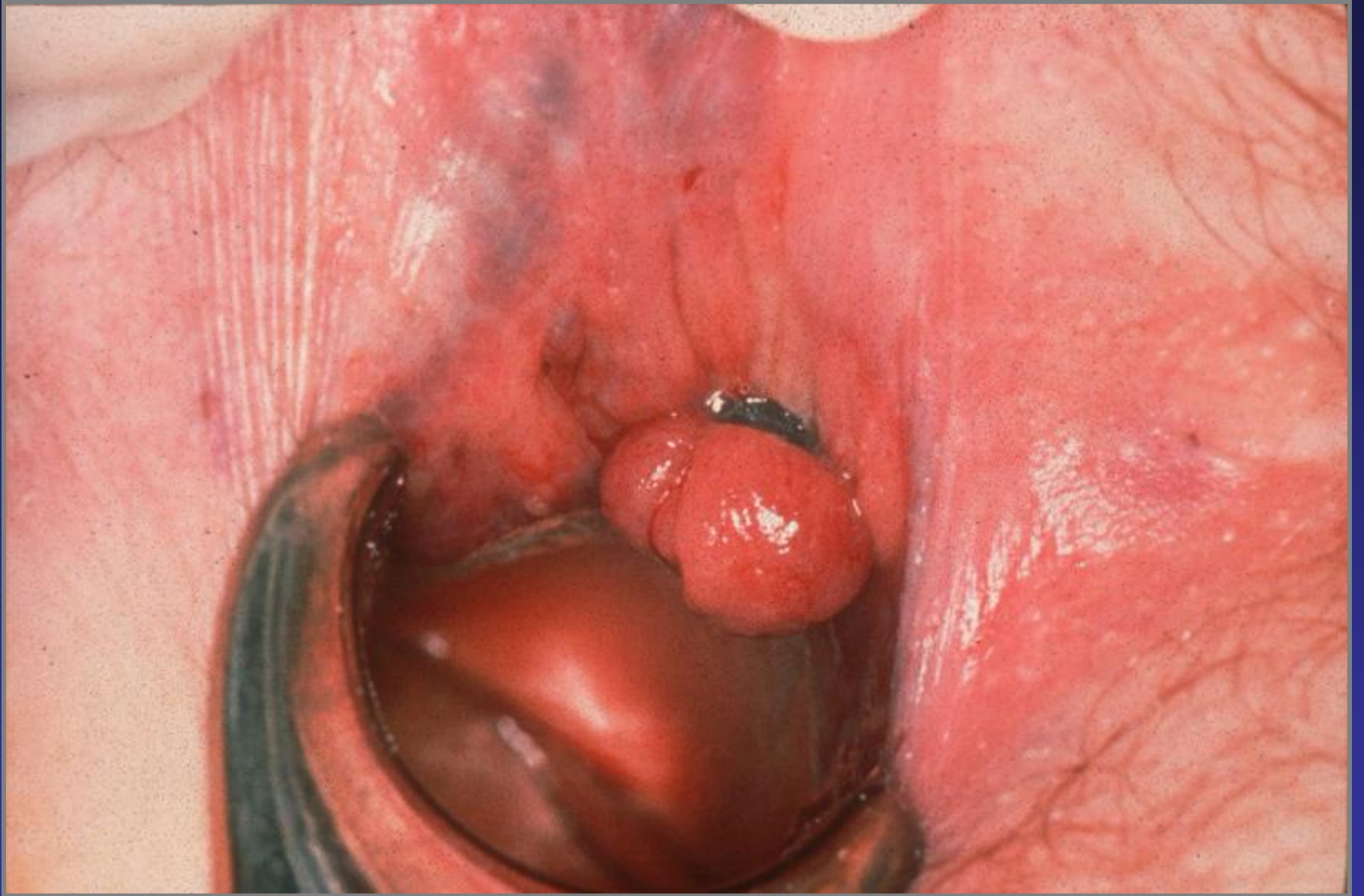
JOHN A. CRAIG, M.D.
© CIBA

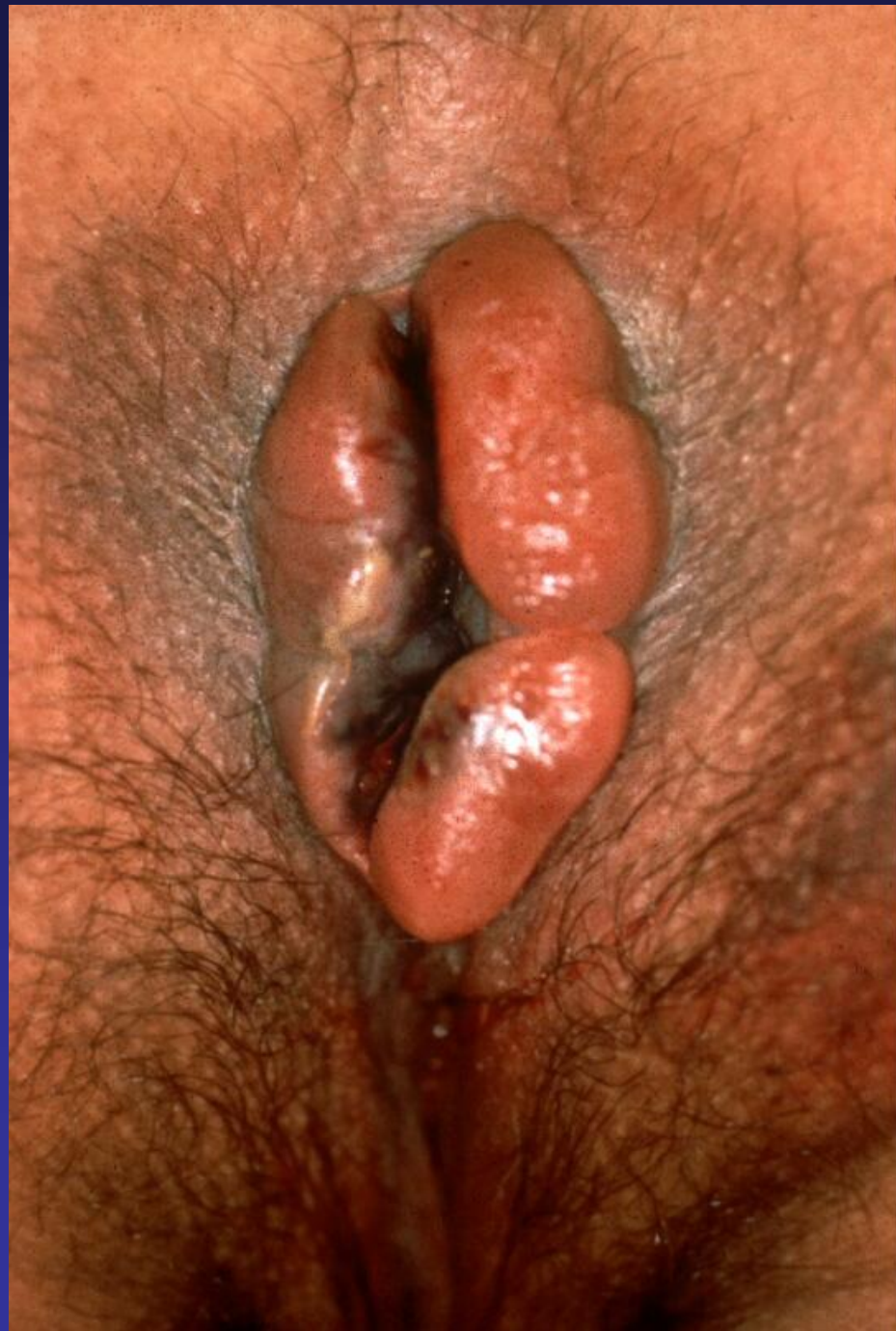Excision technique for mixed hemorrhoids

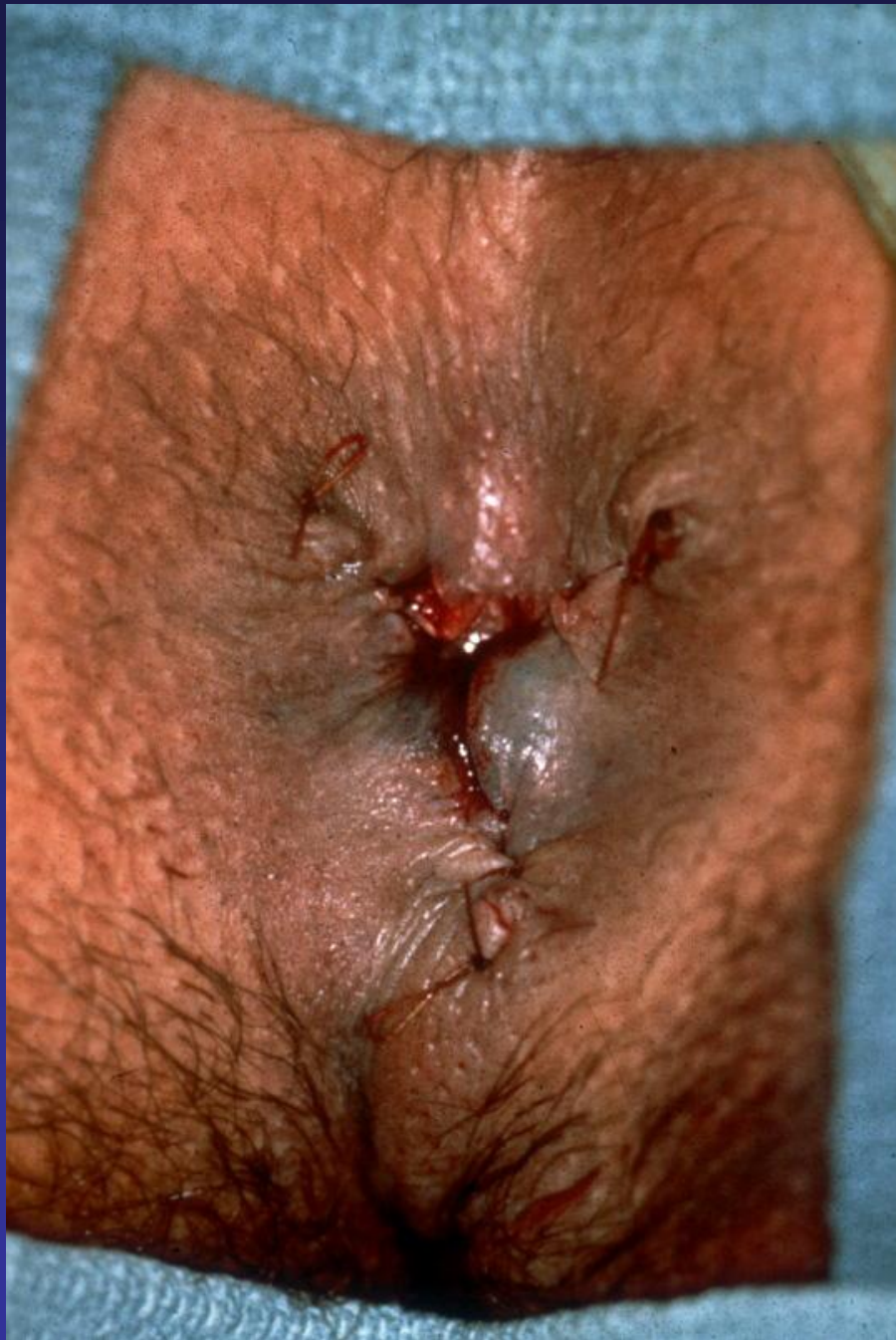











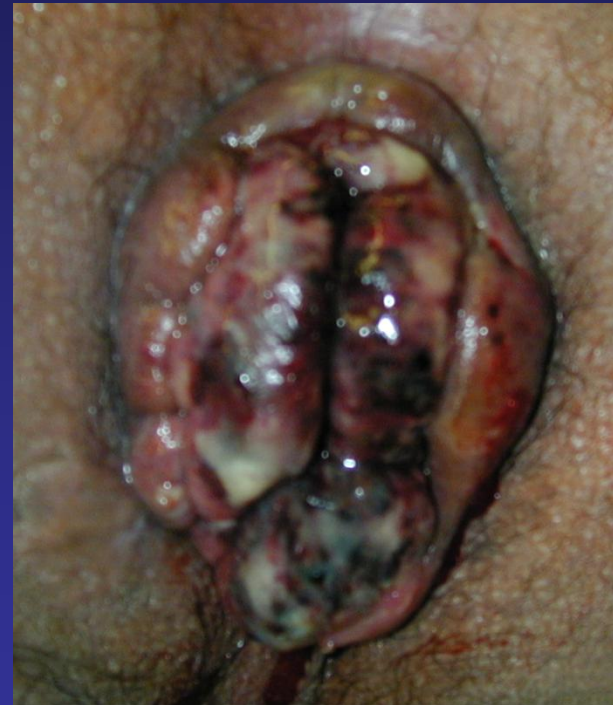Common Anorectal Disorders

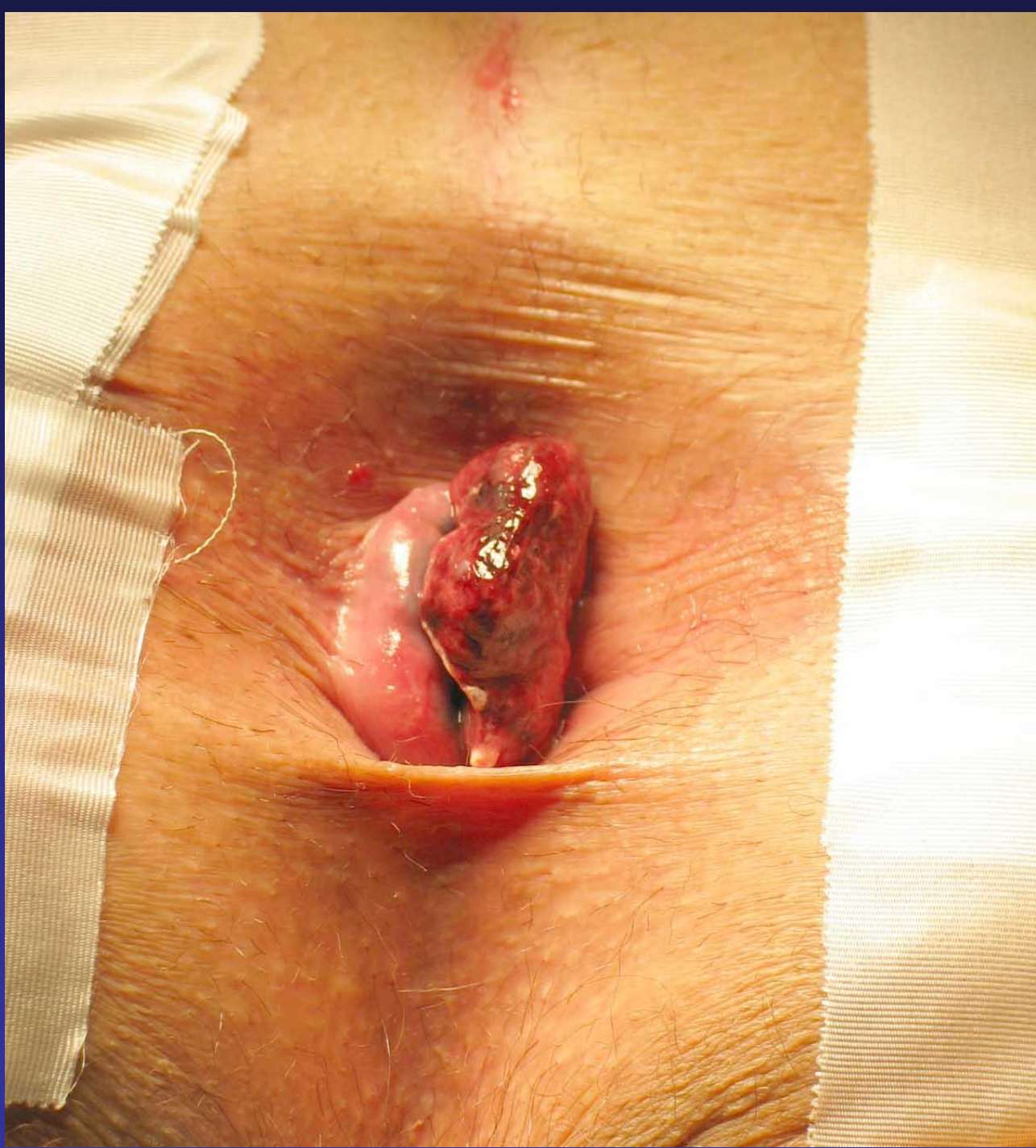
INTERNAL HEMORRHOIDS

Management

Surgical Hemorrhoidectomy

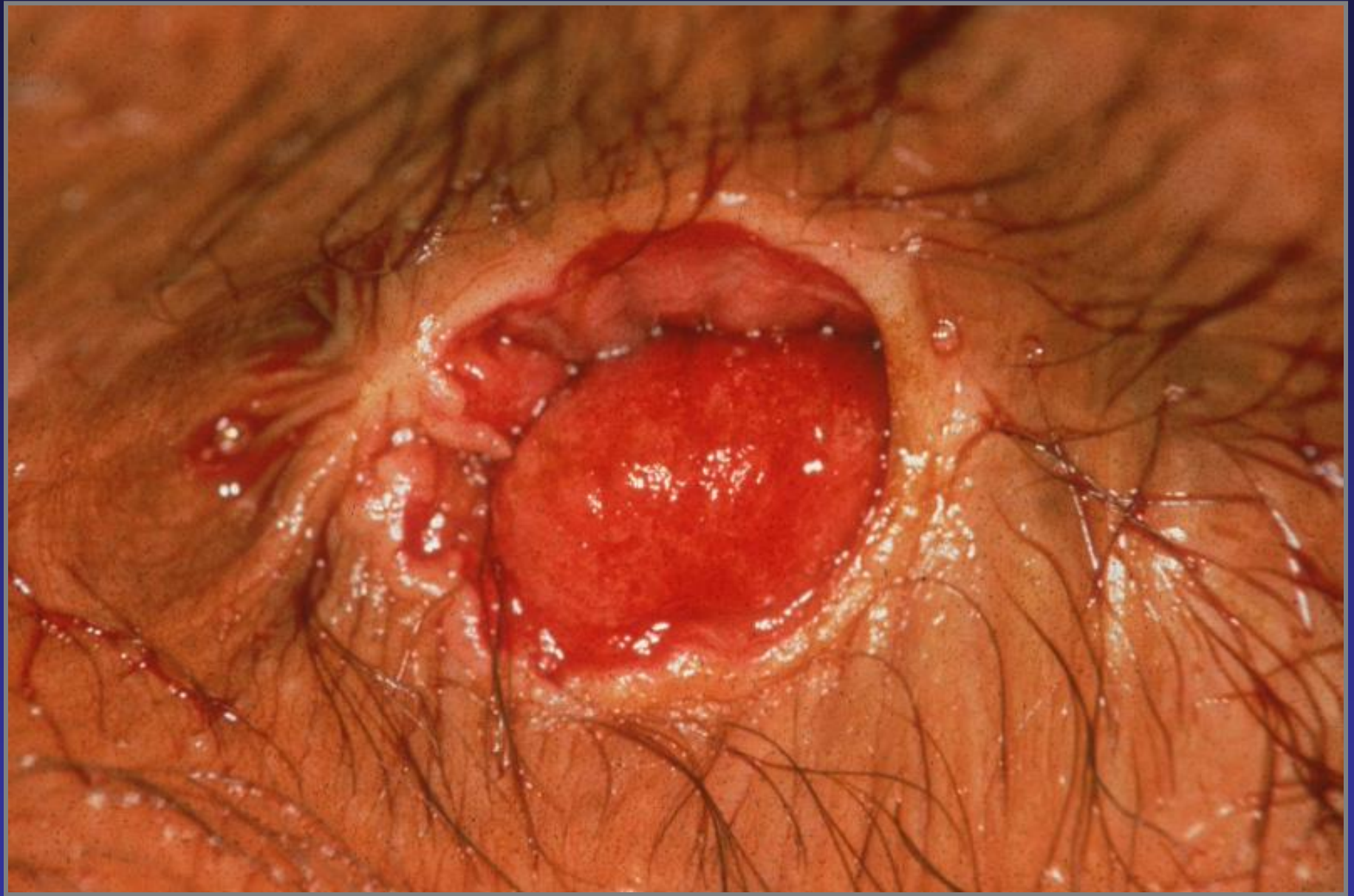- Grade IV
- Mixed internal and external
- Hemorrhoidal crisis
- Patient preference
- In conjunction with another procedure





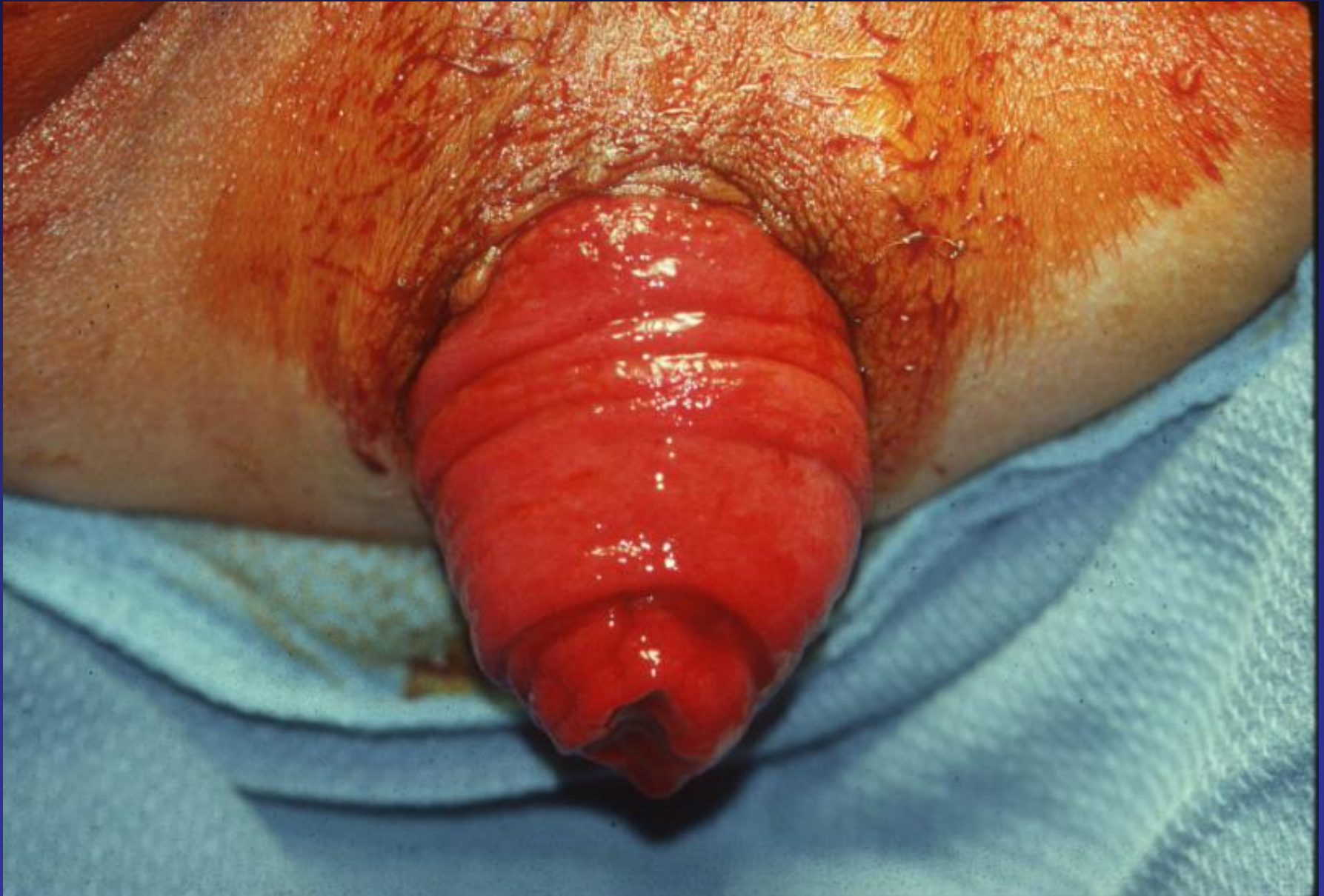Complications

- Bleeding
 - Acutely or delayed
- Infection
 - Rare: requires high index of suspicion
 - Can be lethal
- Incontinence
 - Detailed questioning regarding continence PREOP
- Stricture or ectropian
 - Increased risk with circumferential disease
- Urinary Retention



70 y.o. female

- Has had hemorrhoids for a long time
- They hang out all day, only go back up when she lies down
- Incontinence of stool
- Chronic soiling
- Wears pad



This is NOT a hemorrhoid

Rectal Prolapse

- Elderly (nulliparous) female
- Chronic constipation
- Straining to have bowel movement
- Pelvic floor abnormality
- Associated uro-gyn symptoms
- Patulous anus

Common Anorectal Disorders

Rectal Prolapse *Treatment*

Abdominal repair

- Rectal fixation
- Sigmoid resection
- Proctectomy
- Combination of rectal fixation and sigmoid resection

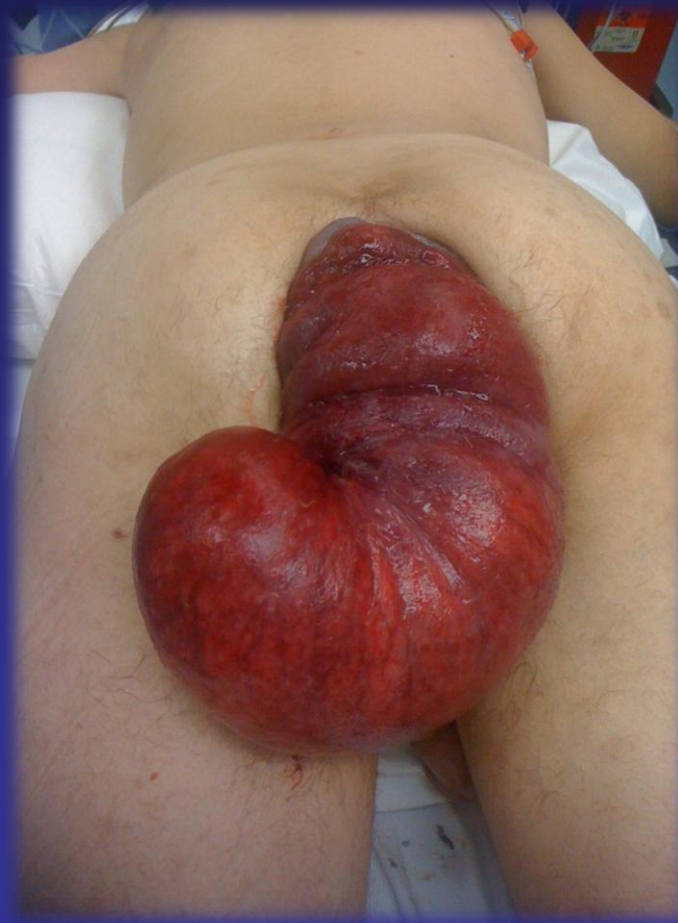Perineal repair

- Full thickness resection
- Mucosal resection with muscular reefing
- Anal encirclement

25 y.o. male

- Long history of difficulty having BM
- Recent trauma, on narcotics
- No BM for 3 days
- Strained at stool
- Brought to ED by girlfriend, who found him bleeding on floor of bathroom

This is not just the rectum:



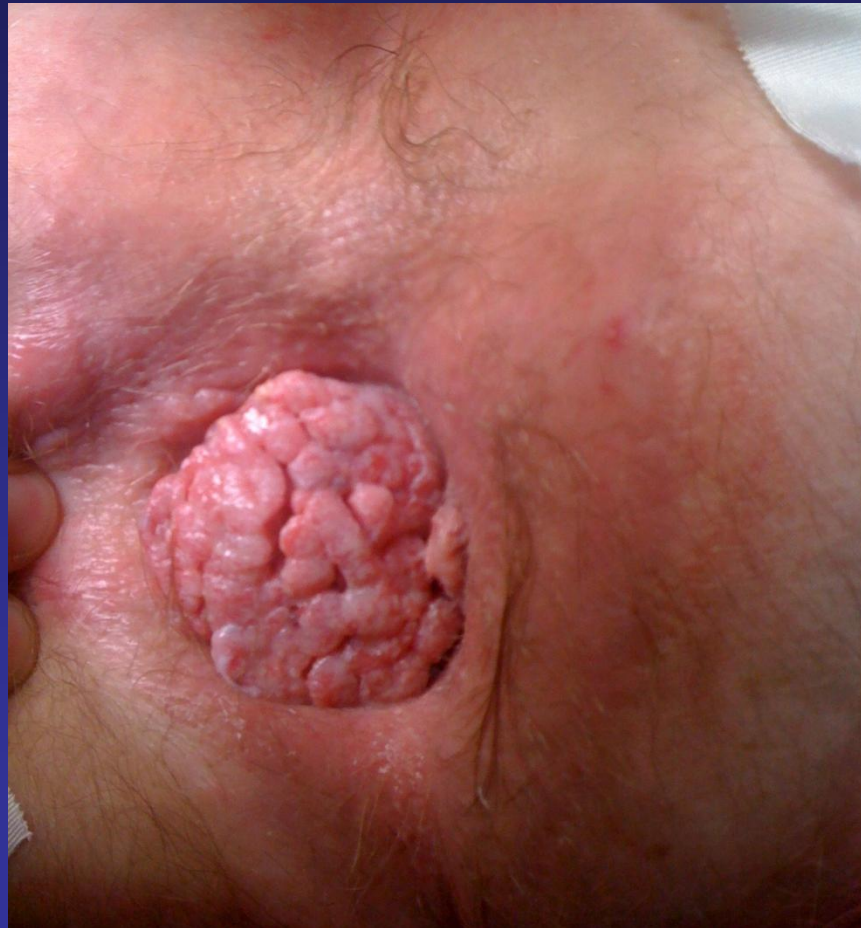Incarcerated Rectal Prolapse

- Surgical emergency
- Altemeier or perineal approach is procedure of choice
- Necrosis of the dentate line may require colostomy

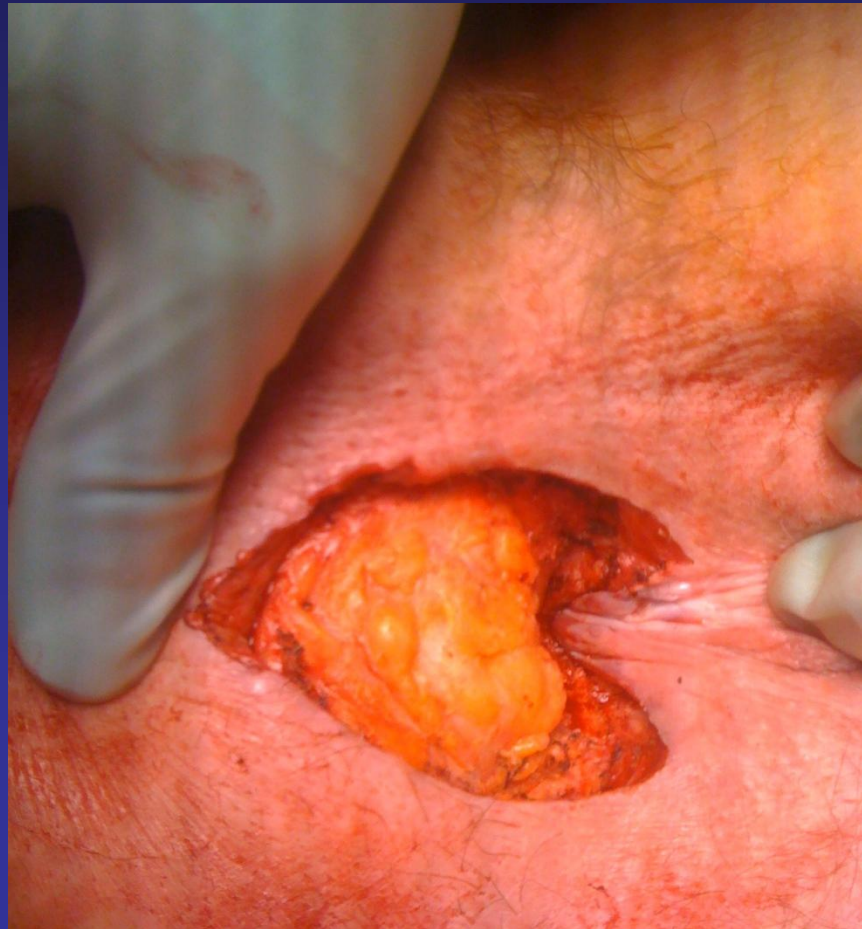45 y.o. male

- Cc: Doc, I've got this hemorrhoid that just keeps getting bigger.
- It's been there about a month.
- I can't push it back in.

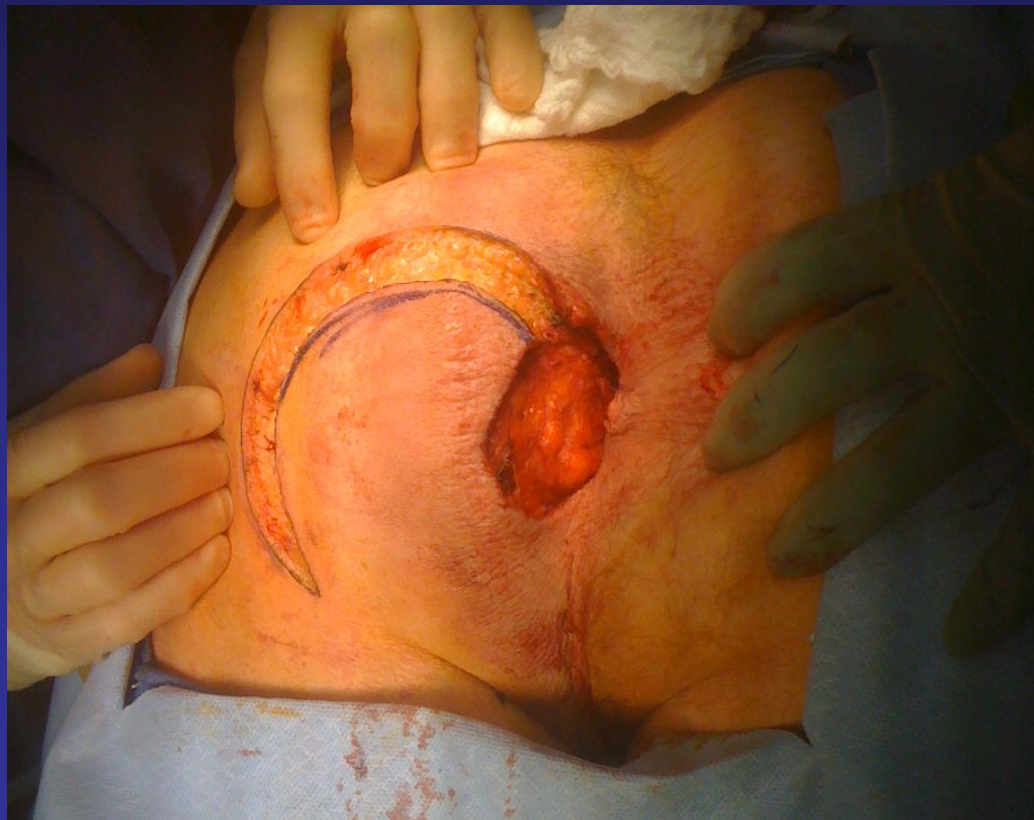This is not a hemorrhoid:



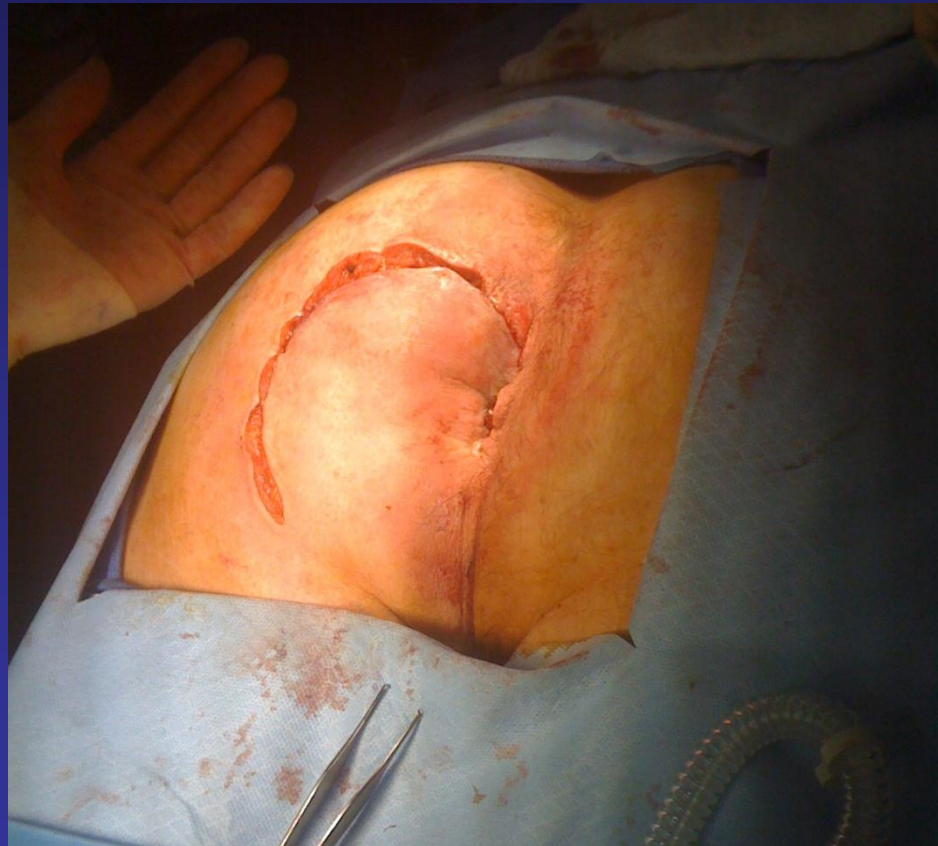After wide local excision



Flap outlined, elevation begun

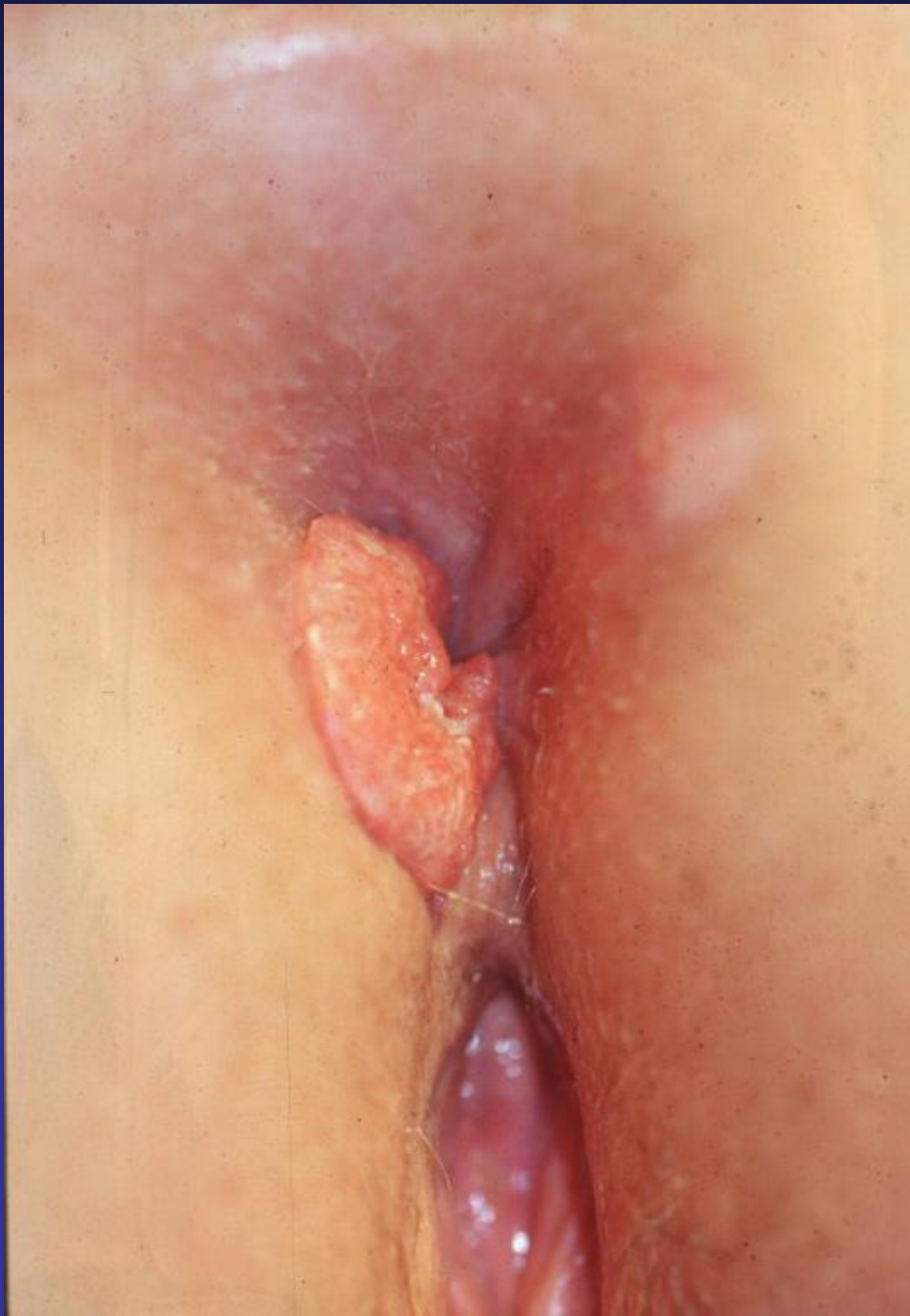

Flap sutured in place



50 y.o. female

- “It’s my hemorrhoids. I’ve been dealing with them a long time, and now they just hurt constantly.”



Anal neoplasms

- Mass
- Pain
- Bleeding
- Itching
- Discharge
- *Up to 30% will be misdiagnosed as a benign anorectal condition*

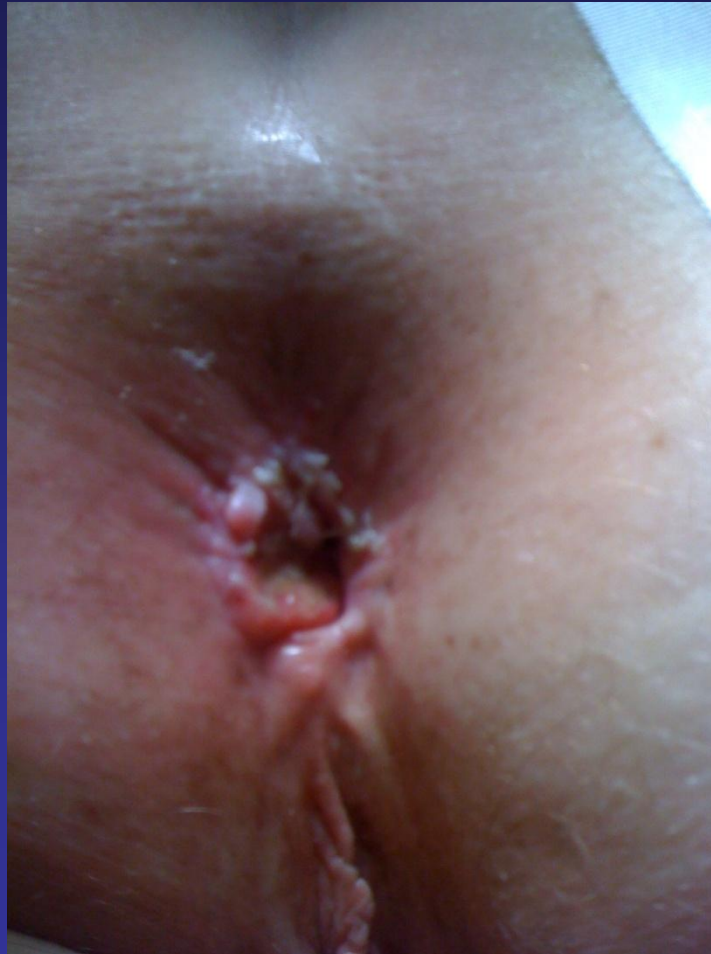Anal margin v. anal canal

- Paget's or Bowen's
- Squamous cell carcinoma
- Involves skin around anus
- Often history of anal condylomata
- Treatment is wide local excision
- Cloacogenic carcinoma (squamous)
- Involves anal canal
- Treatment is Nigro protocol
- Radiation, chemo (5-FU + mitomycin-c)

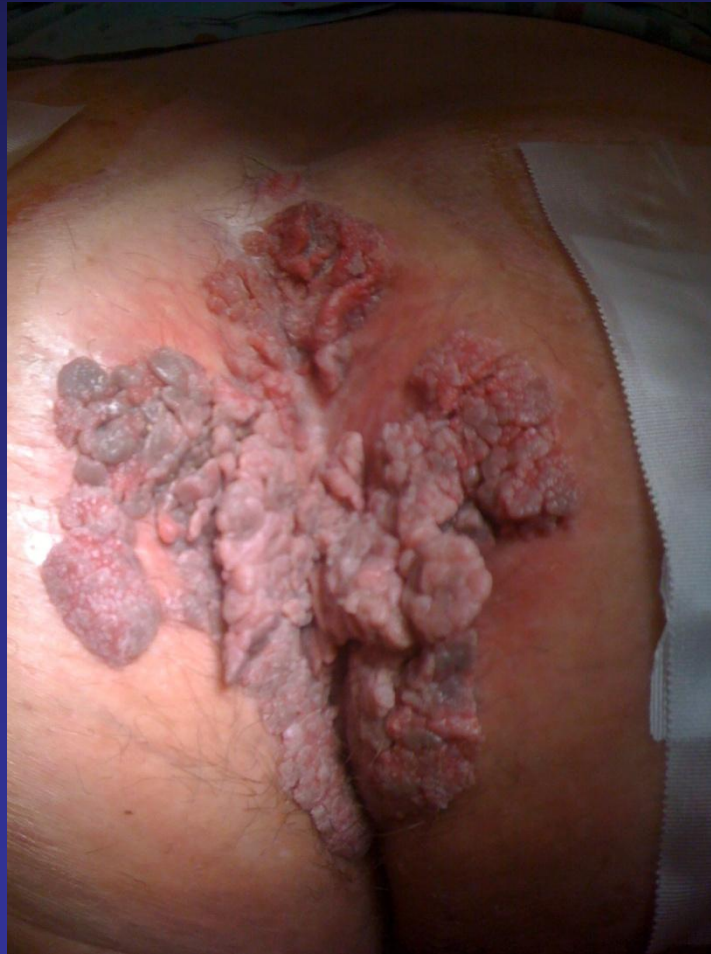68 y.o. female

- Complains of pain, discharge, decreased calibre of stool
- Gastroenterologist has identified a “scar” on the anus
- History of radiation and chemotherapy in 80’s. Received both external beam and brachytherapy.

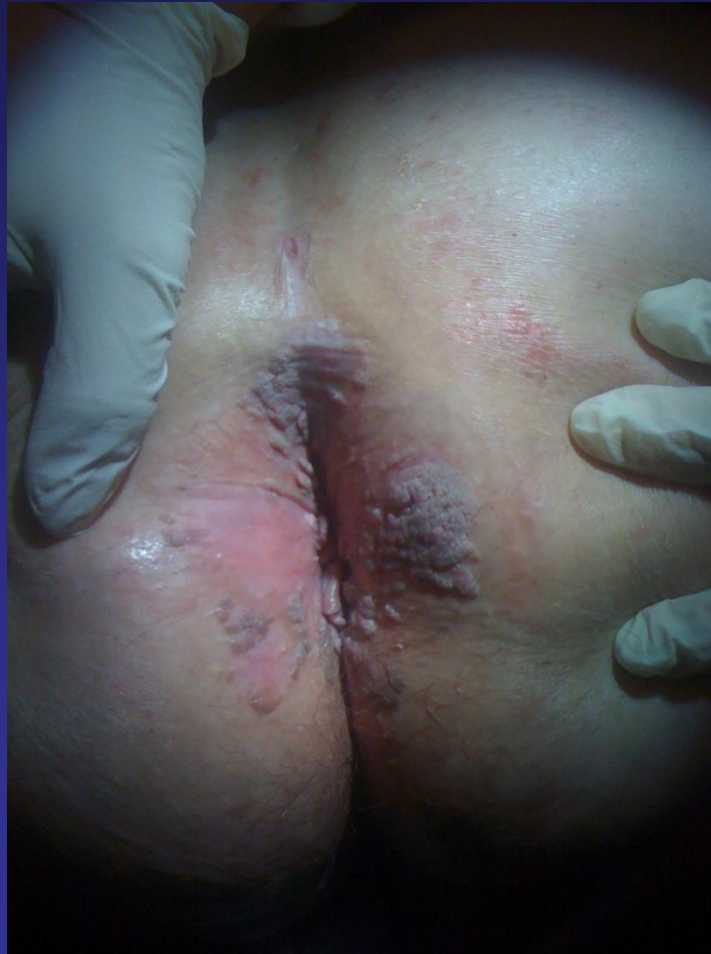Recurrent anal cancer



How it all began...



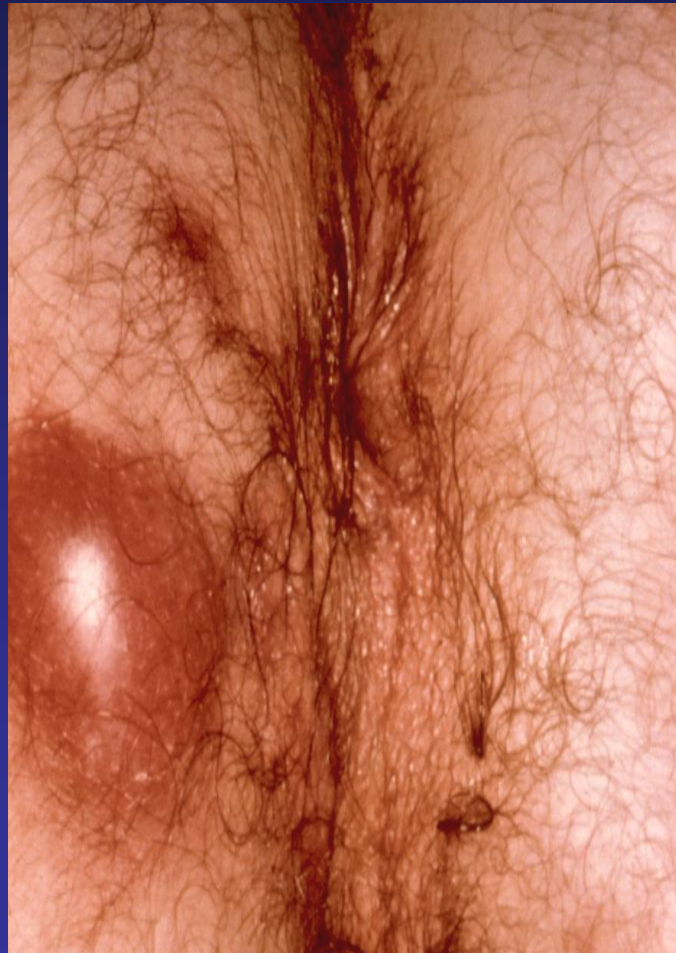After treatment...



18 y.o. male c/o hemorrhoid

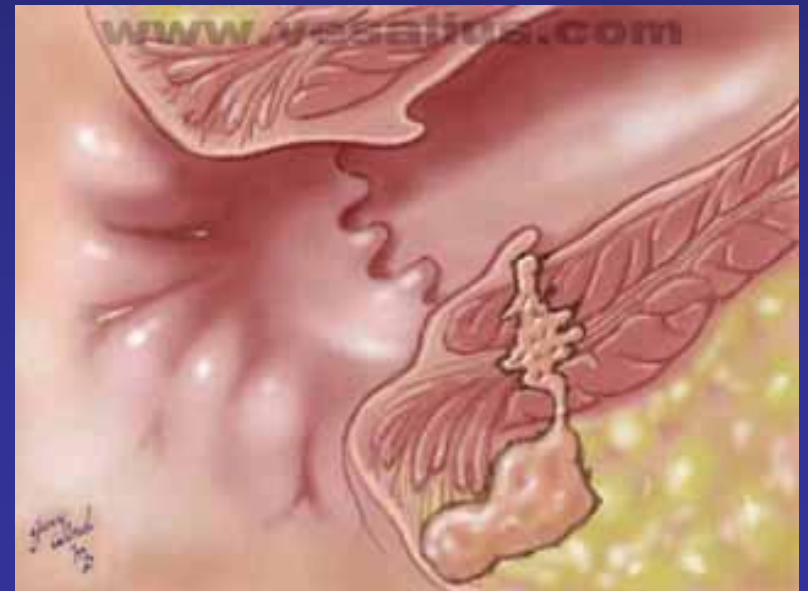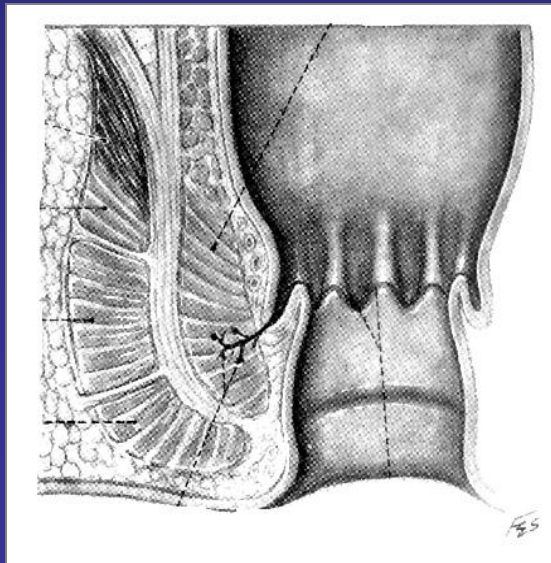
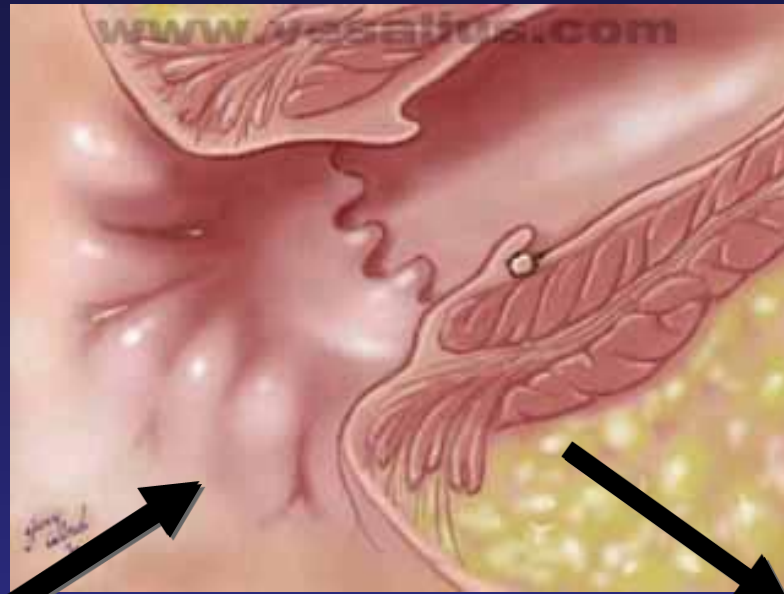
- Several day history of increasing pain
- Swelling on anus
- (Fever)
- (Urinary retention)
- (Difficulty initiating bowel movement)

This is not...

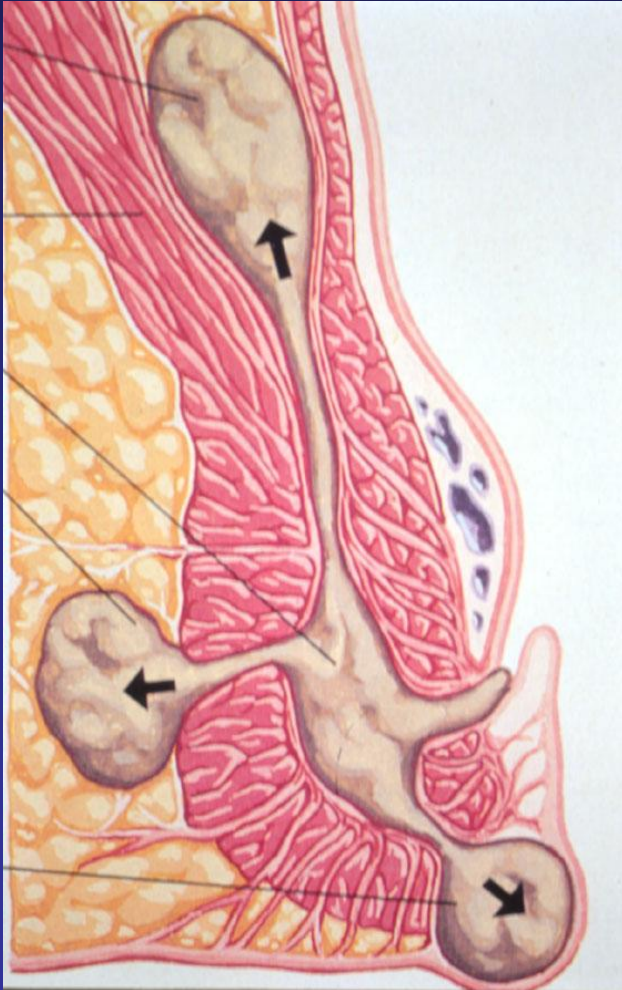


What to do next:

- Further work-up?
- CT pelvis?
- None!
- Treatment?
- Antibiotics?
- Incision and drainage!



Abscess: Classification

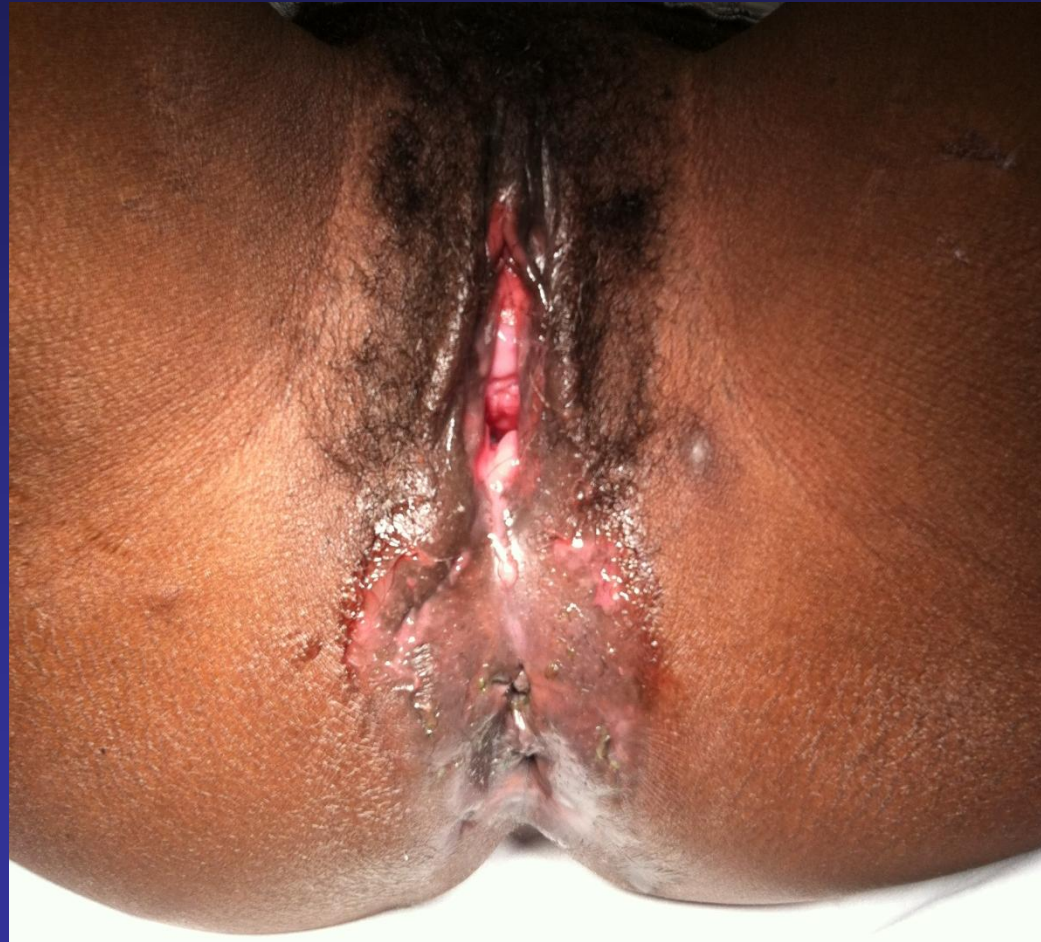

- Perianal (~40%)
- Ischioanal (~20%)
- Intersphincteric (~3%)
- Supralevator (<2.5%)

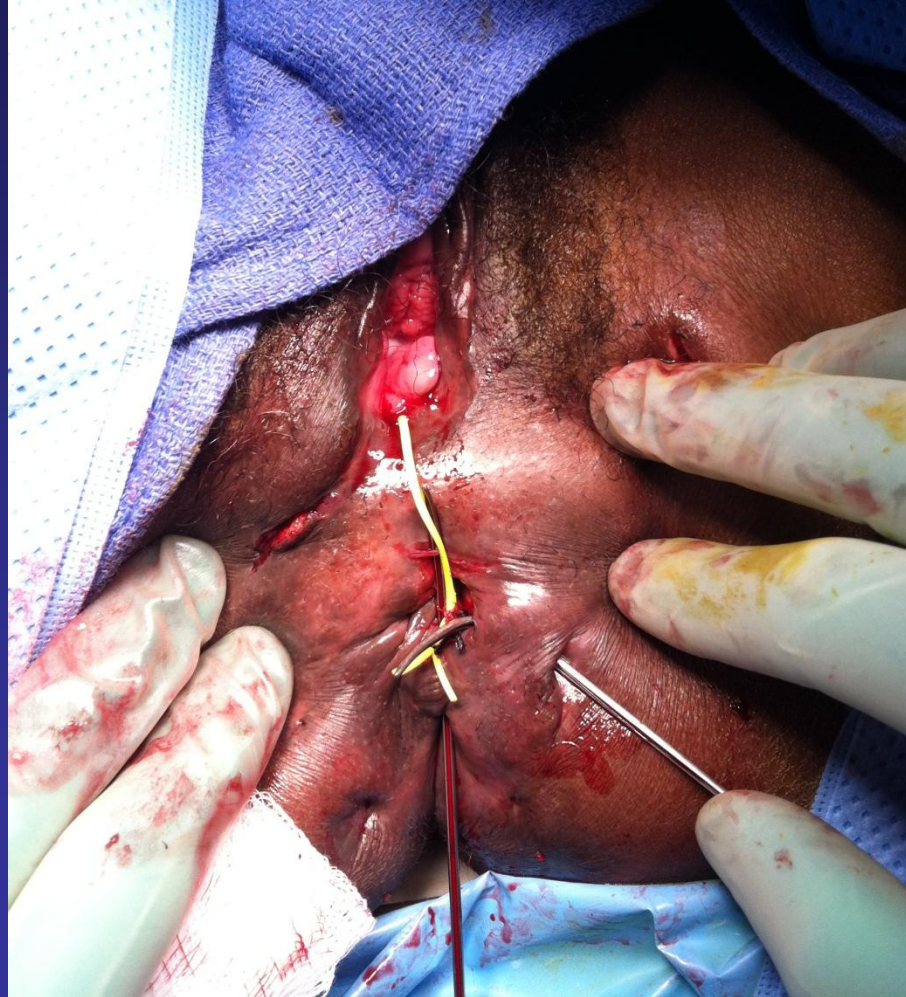48 y.o. female pain for 5 days

- Swelling “burst” day before presentation
- Long history of Crohn’s disease
- Previous bowel resection
- Multiple drainage procedures
- Currently on no therapy

Next step: EUA



Drainage procedure



Fistula-in-Ano

- History:
 - Abscess in past
 - Discharge/excoriation (65%)
 - Pain (34%)
 - Swelling (24%)
 - Bleeding (12%)

Fistula-in-Ano

- Differential Diagnosis:
 - Crohn's Dz
 - HIV
 - TB
 - Lymphoma
 - Malignancy
 - Hydradenitis Suppurativa
 - Bartholin's gland abscess

Fistula-in-Ano

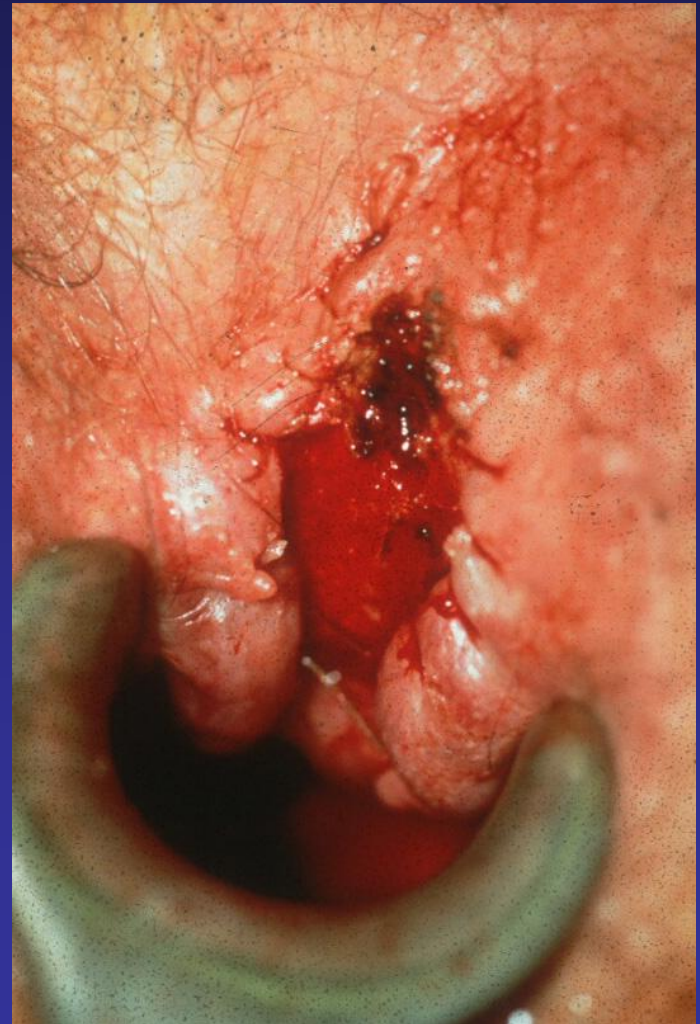
- Physical exam:
 - Elevated granulation tissue with d/c
 - Palpable chord
 - Rectal exam:
 - Internal opening
 - Sphincter tone
 - Anoscopy/Colonoscopy

Treatment:

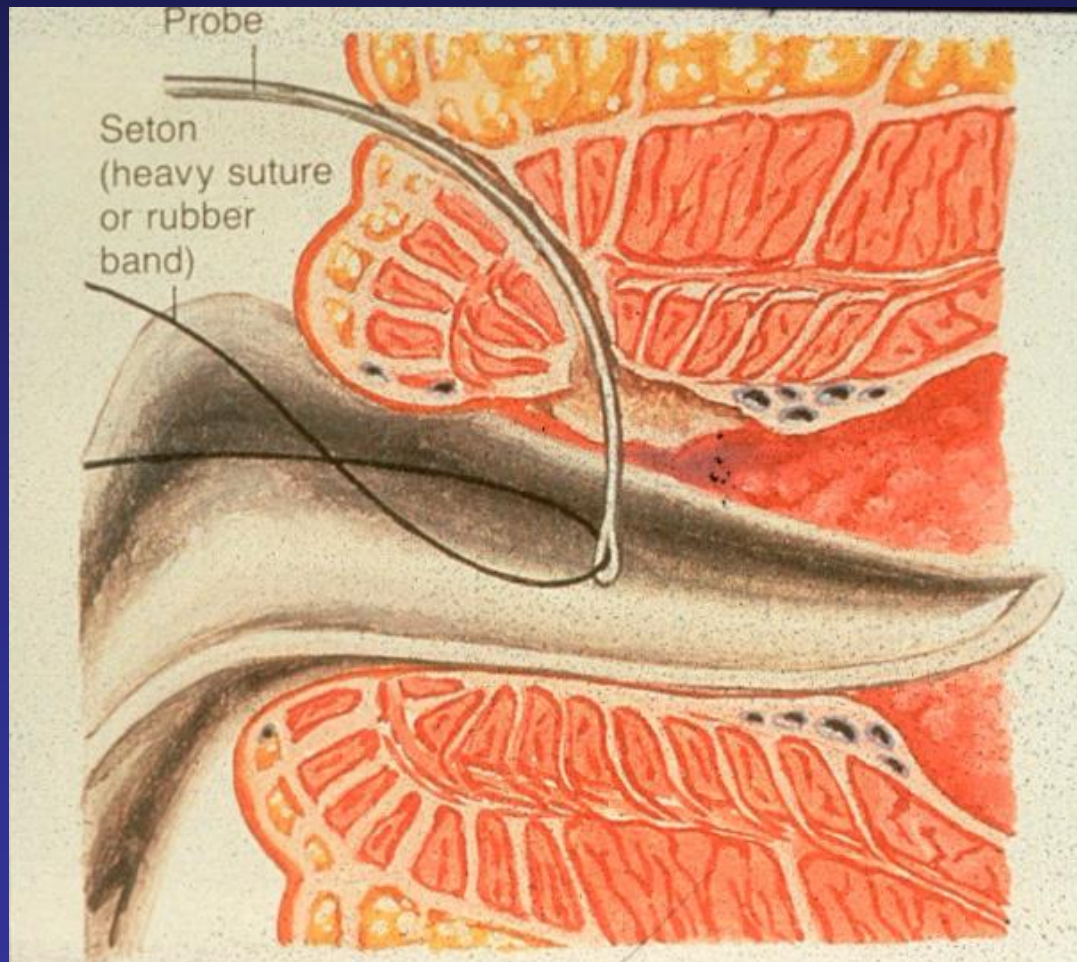
- Fistulotomy
- Seton placement
- Anal fistula plug
- Sliding flap closure

Fistula-in-Ano: Fistulotomy

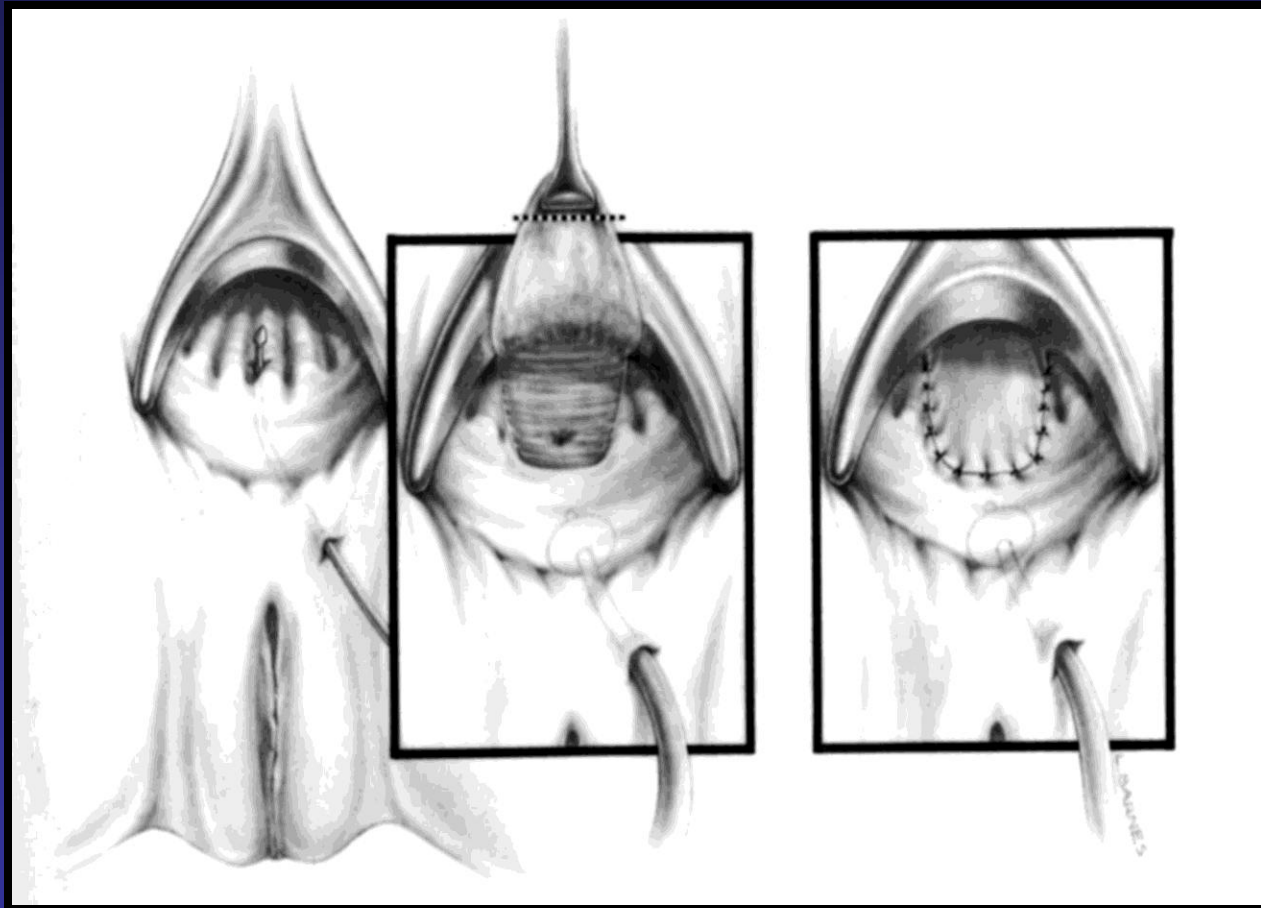
- Complications:
 - Incontinence 3-7%
 - Delayed healing
 - Anal stenosis
 - Mucosal prolapse



Seton Placement



Endo-rectal flap



To Review:

Anal Symptoms/Pathology

<u>Symptoms</u>		<u>Pathology</u>
1. Pain and bleeding after bowel movement	→	Ulcer/Fissure
2. Forceful straining to have bowel movement	→	Pelvic floor Abnormality
3. Blood mixed with stool	→	Neoplasm/Inflammatory bowel disease
4. Drainage of pus during or after bowel movement	→	Abscess/fistula

Anal Symptoms/Pathology

Symptoms

Pathology

- | | | |
|----------------------------------------|---|-------------------------|
| 5. Constant moisture | → | Condyloma
Accuminata |
| 6. Mucous drainage
and incontinence | → | Rectal prolapse |
| 7. Constant anal pain | → | Abscess |
| 8. +/- retention, fever | | |

Open Invitation

- Office hours:
- University Pointe Wednesday morning
- Christ Hospital MOB Thursday 2-5
- University Pointe Friday 1-5.
- See gross stuff!
- Do procedures!
- Have fun!

Hemorrhoids

Prevalence

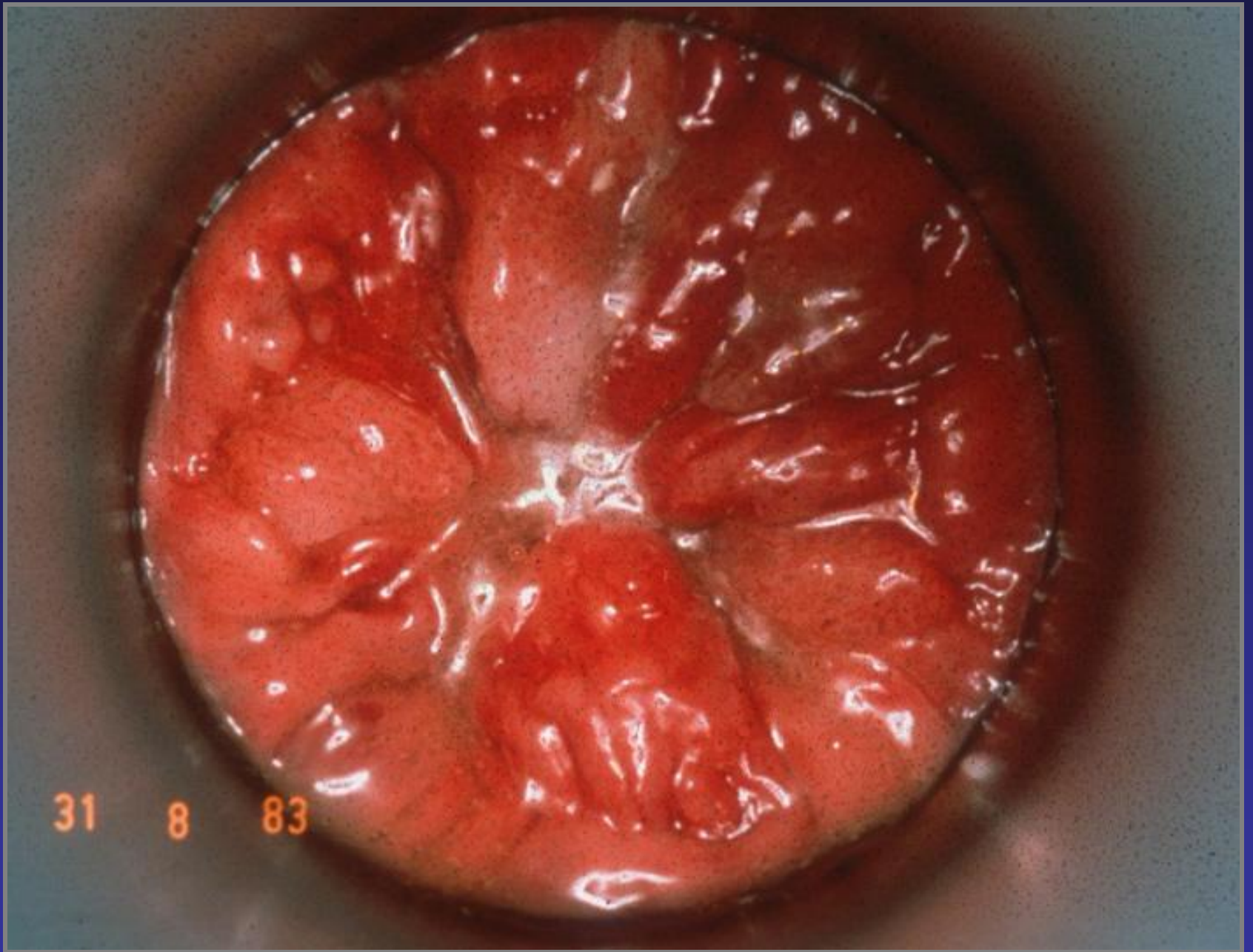
- 10 million people complain of hemorrhoids yearly
- Prevalence rate of 4.4%
- Peak incidence - Age 45 to 65 years
- Rare before 20 years or after 70 years
- 60% of hospitalized patients are men

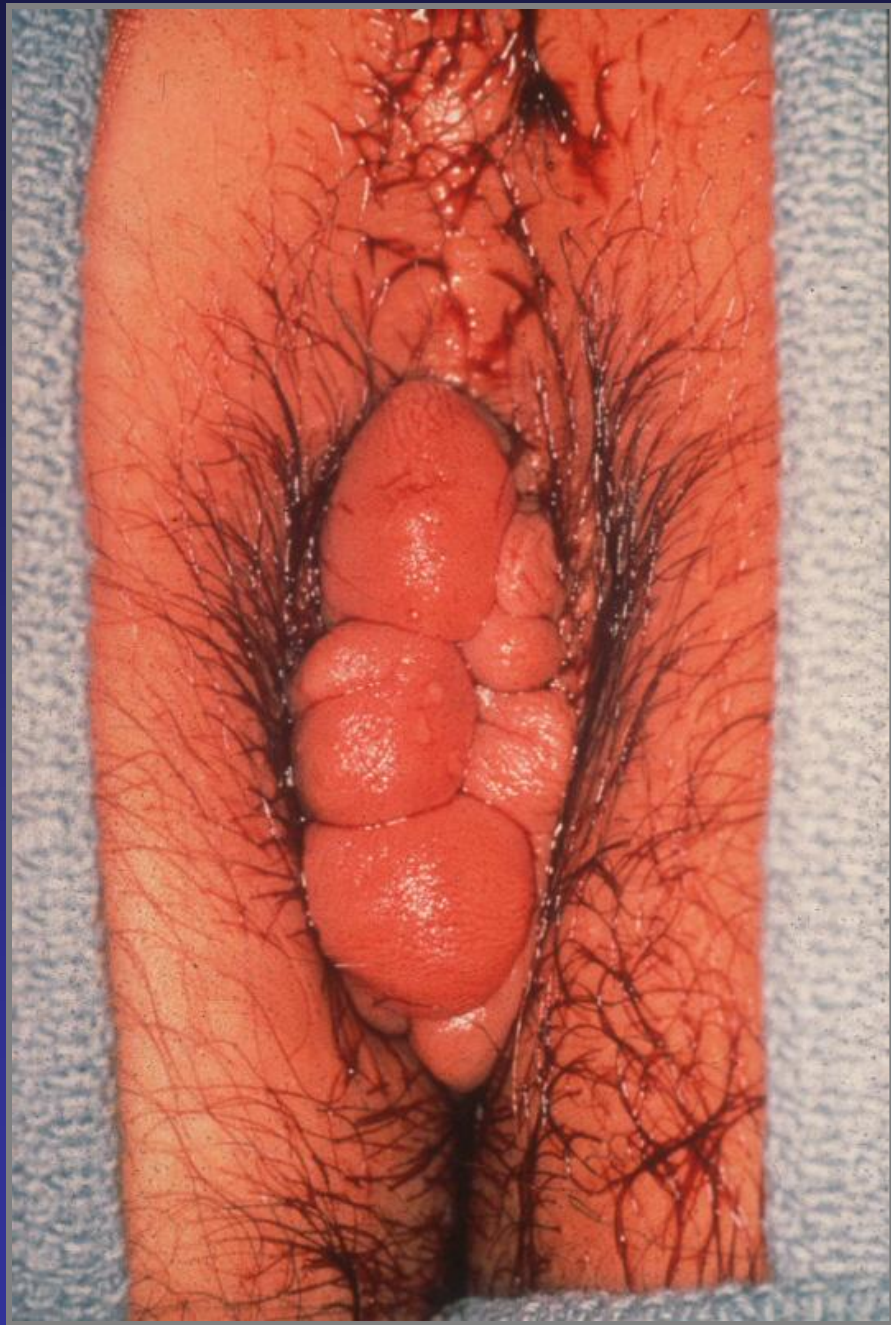
Symptoms

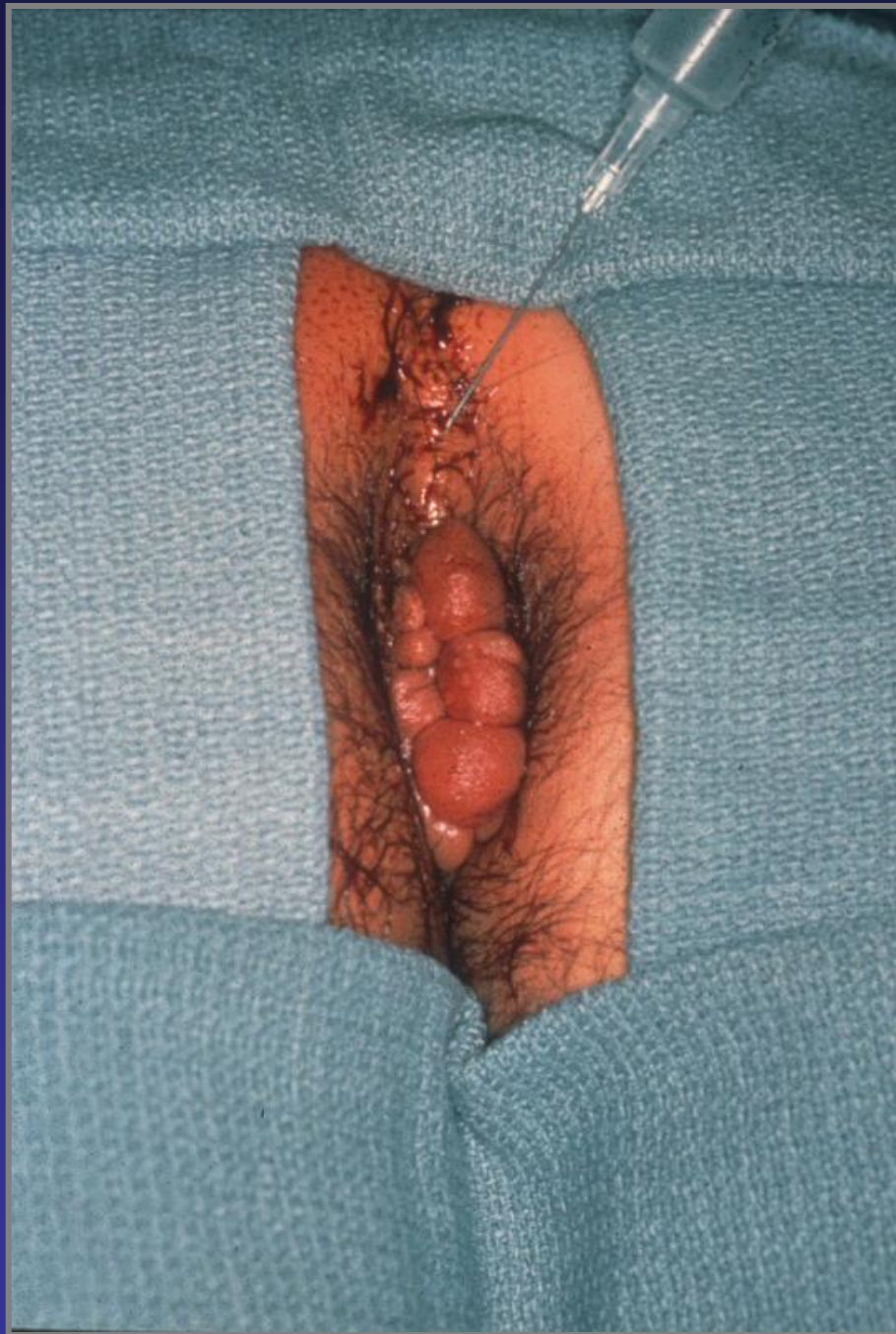- Bright red rectal bleeding
- Protrusion / prolapse
- Pain / discomfort
- Mucous drainage / soiling

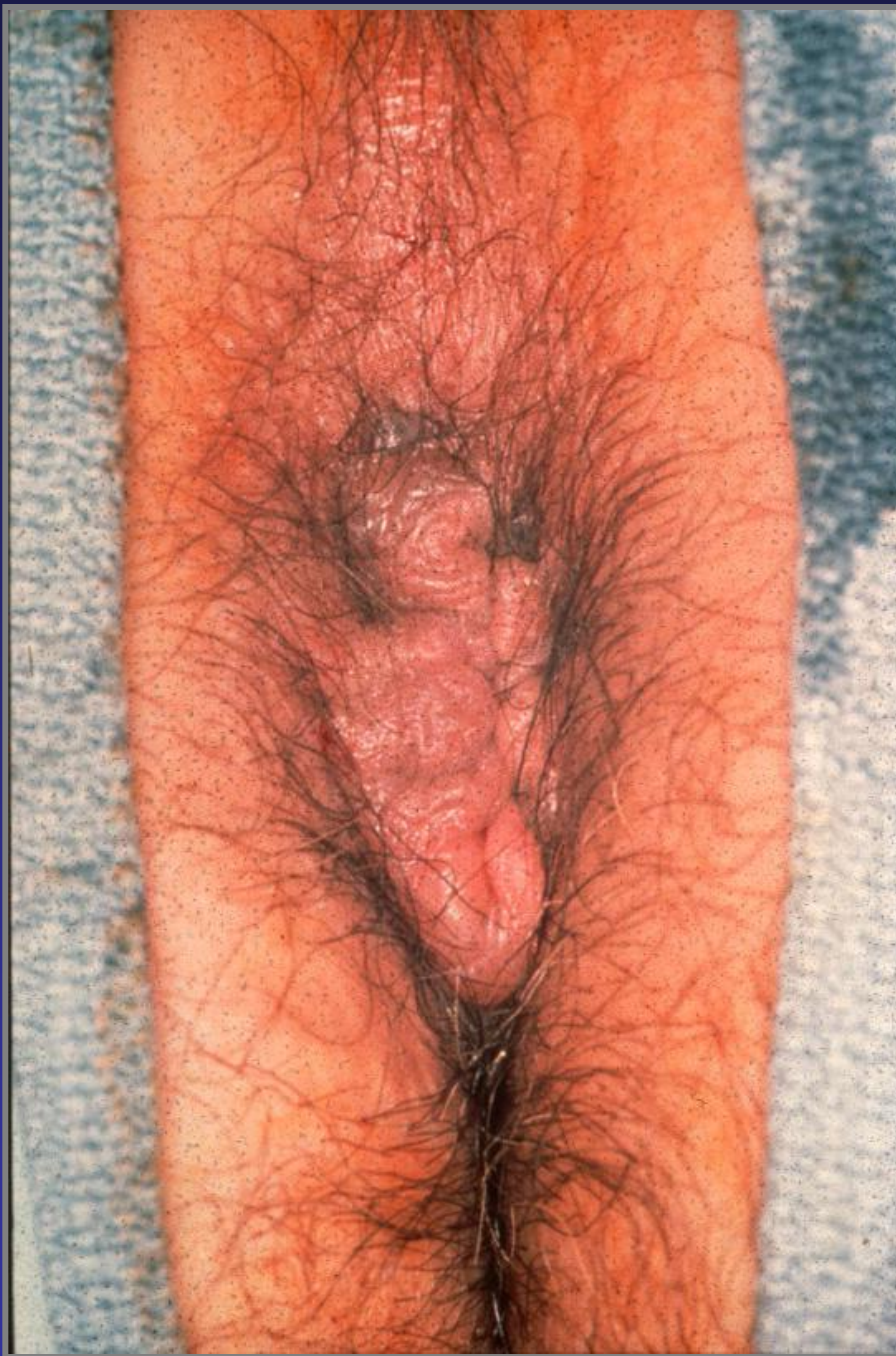Acute Thrombosis: Indications for Surgery

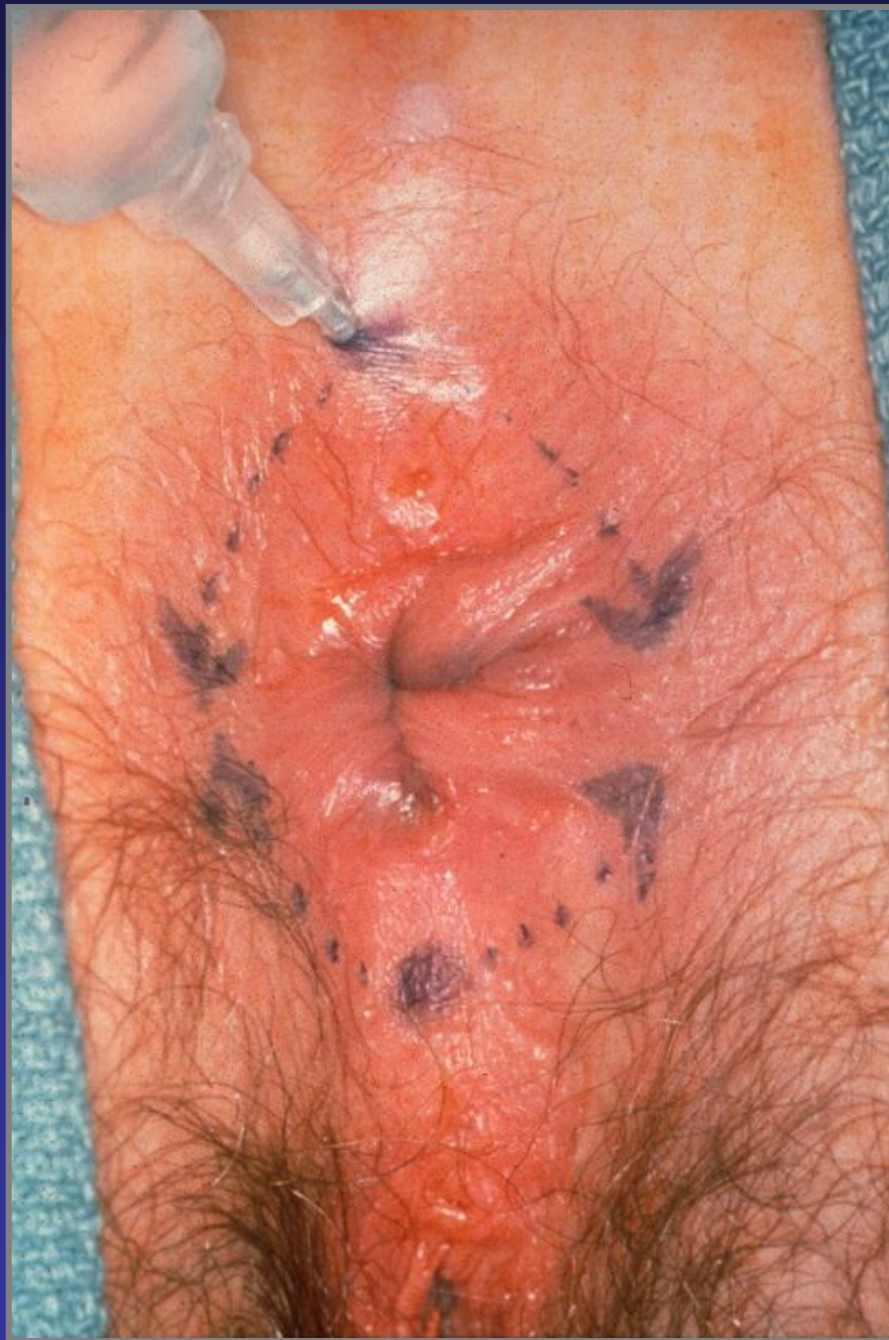1. Inability to tolerate pain
2. Erosion of blood clot
3. Circumferential thrombosis and necrosis
4. Never as a primary procedure in the chronic state

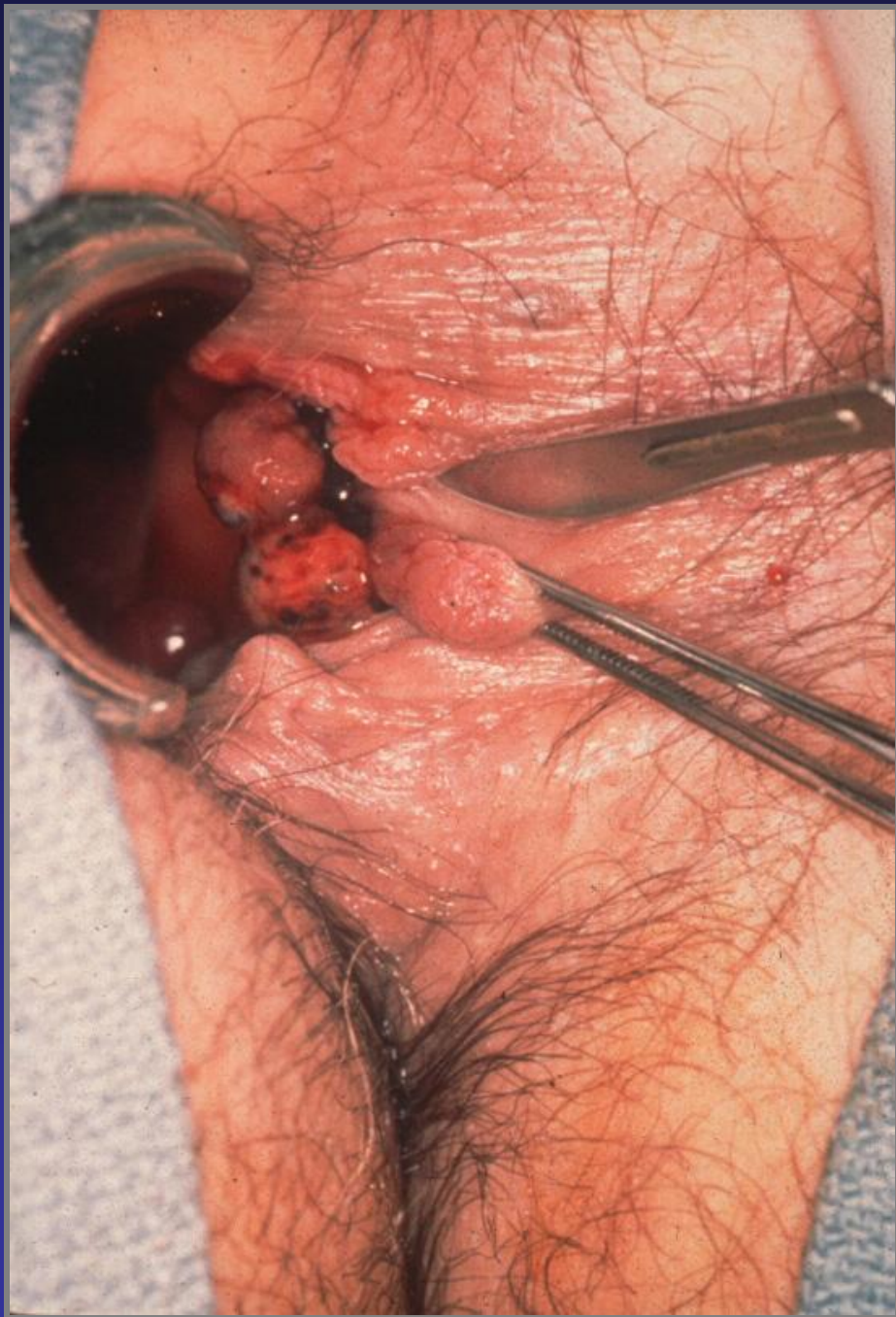












Complications

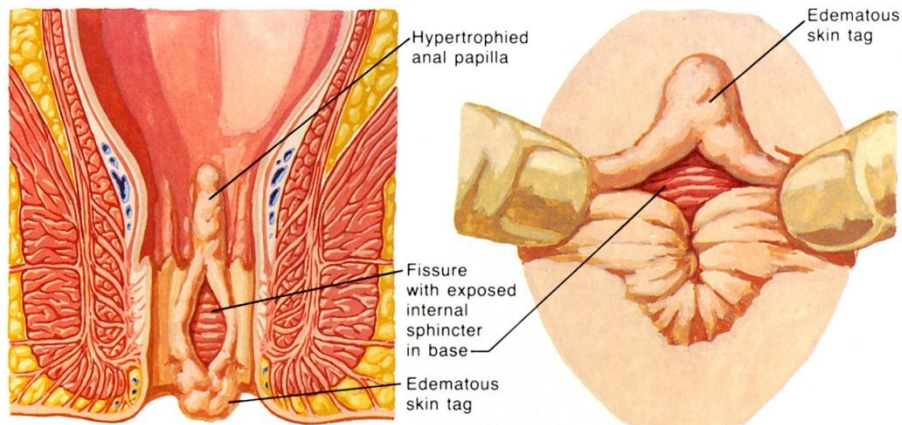
- Bleeding
 - Acutely or delayed
- Infection
 - Rare: requires high index of suspicion
 - Can be lethal
- Incontinence
 - Detailed questioning regarding continence PREOP
- Stricture or ectropian
 - Increased risk with circumferential disease
- Urinary Retention

ANAL FISSURES

Anal Fissure

- History
 - Severe pain with defecation
 - Bleeding
- Exam
 - Sentinel tag
 - Eversion of the anal canal is all that is required to make the diagnosis
 - DON'T PROD AND PUSH

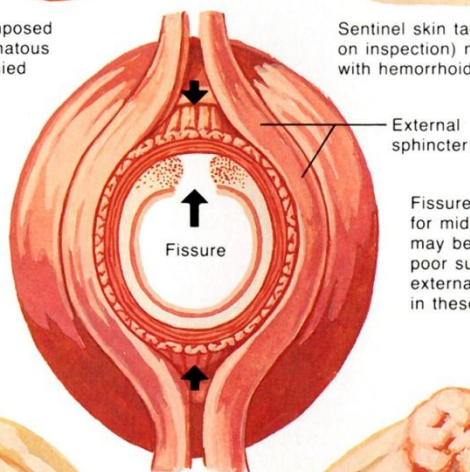
Anal Fissure



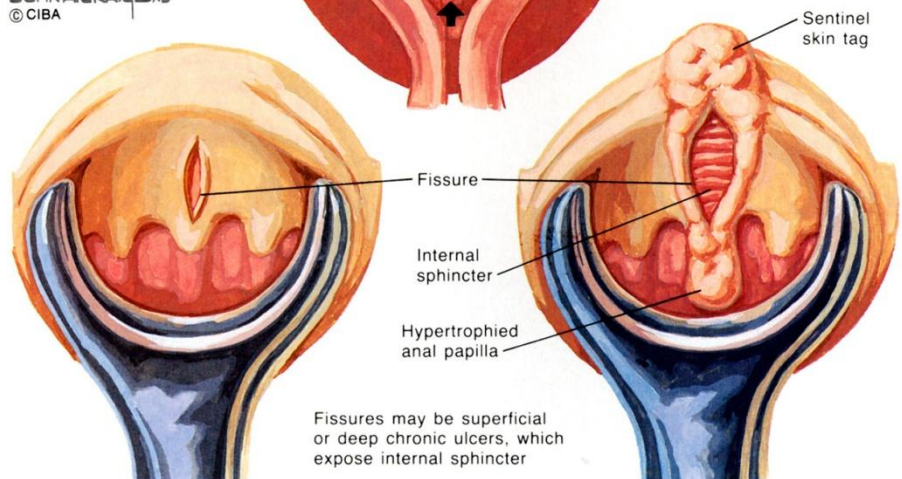
Classic anal fissure composed of fissure, sentinel edematous skin tag, and hypertrophied anal papilla

Sentinel skin tag (shows fissure on inspection) may be confused with hemorrhoid

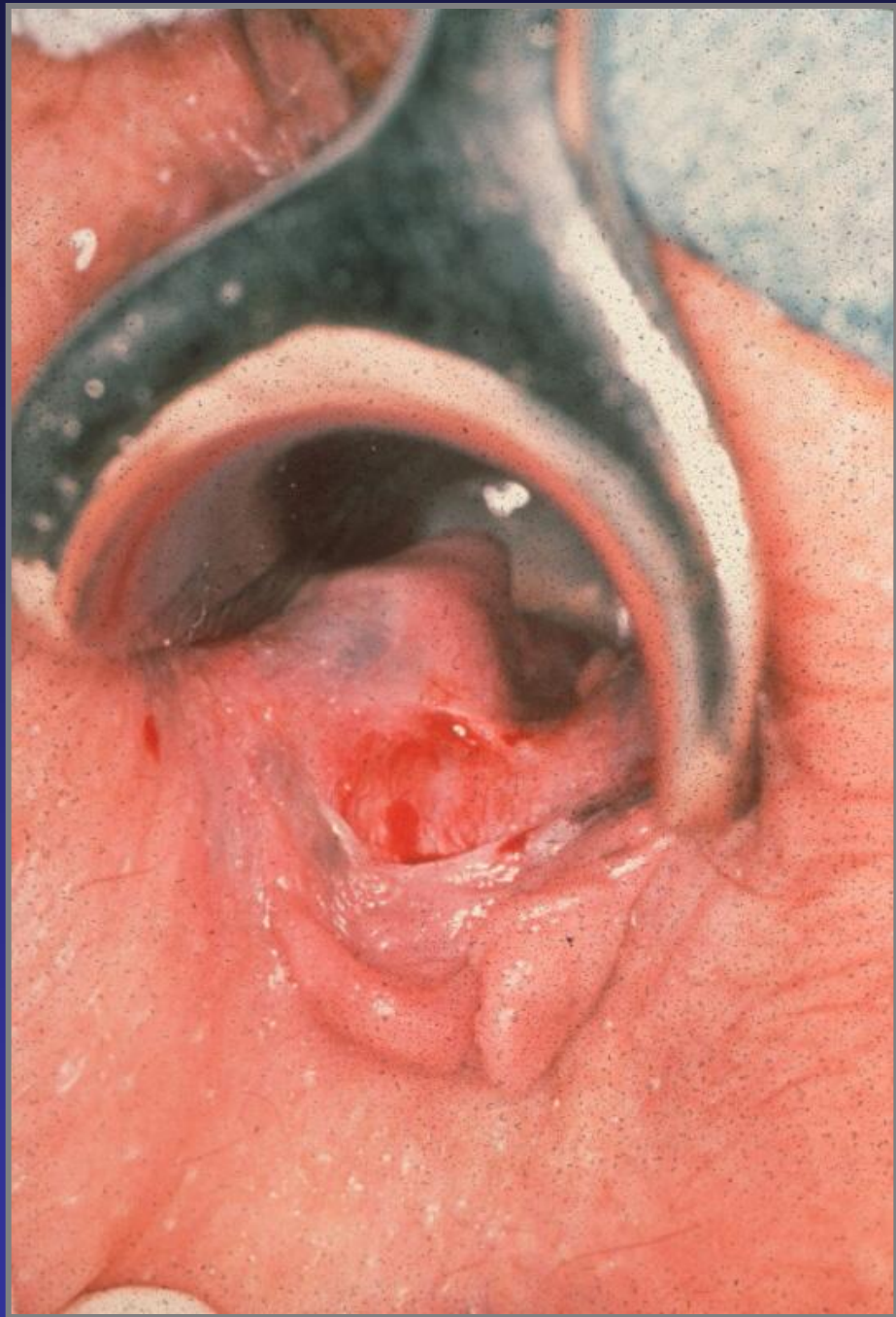
JOHN A. CRAIG, M.D.
© CIBA



Fissure predilection for midline locus may be related to poor support by external sphincter in these areas

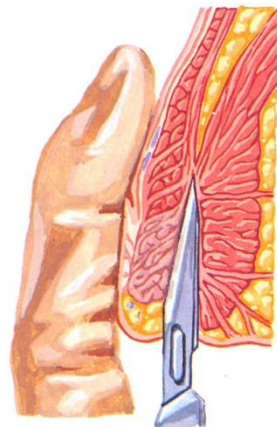


Fissures may be superficial or deep chronic ulcers, which expose internal sphincter

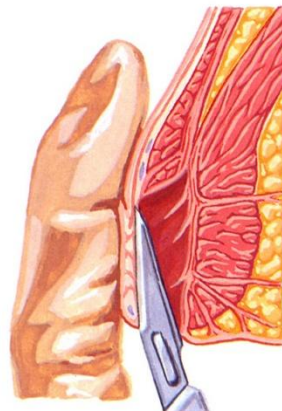


Lateral Internal Sphincterotomy

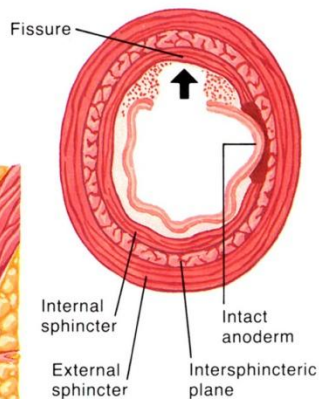
Closed technique



Blade inserted in intersphincteric groove and passed cephalad in intersphincteric plane to level of dentate line

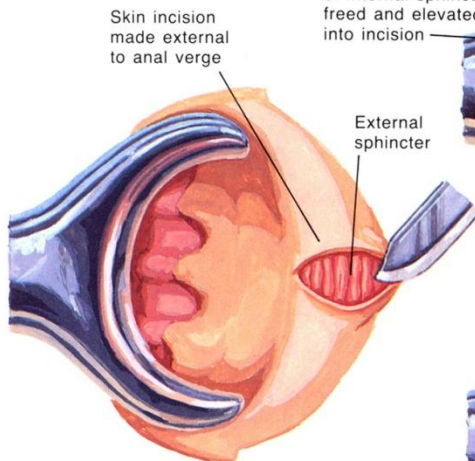


Blade then moved medially, dividing inferior 1/3 to 1/2 of internal sphincter



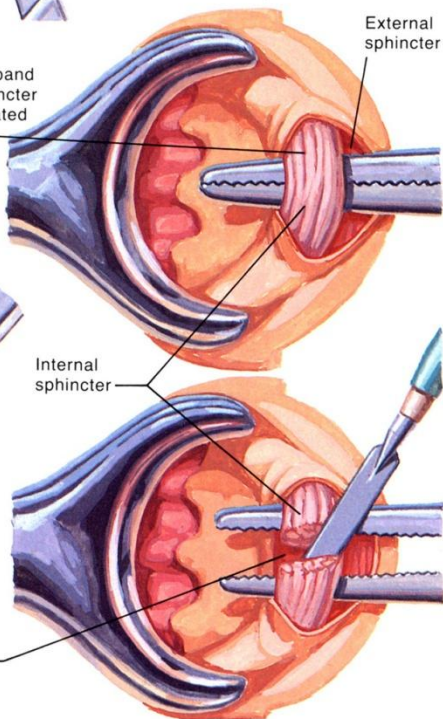
Internal sphincter divided; external sphincter, anoderm, and longitudinal muscle remain intact

Open technique

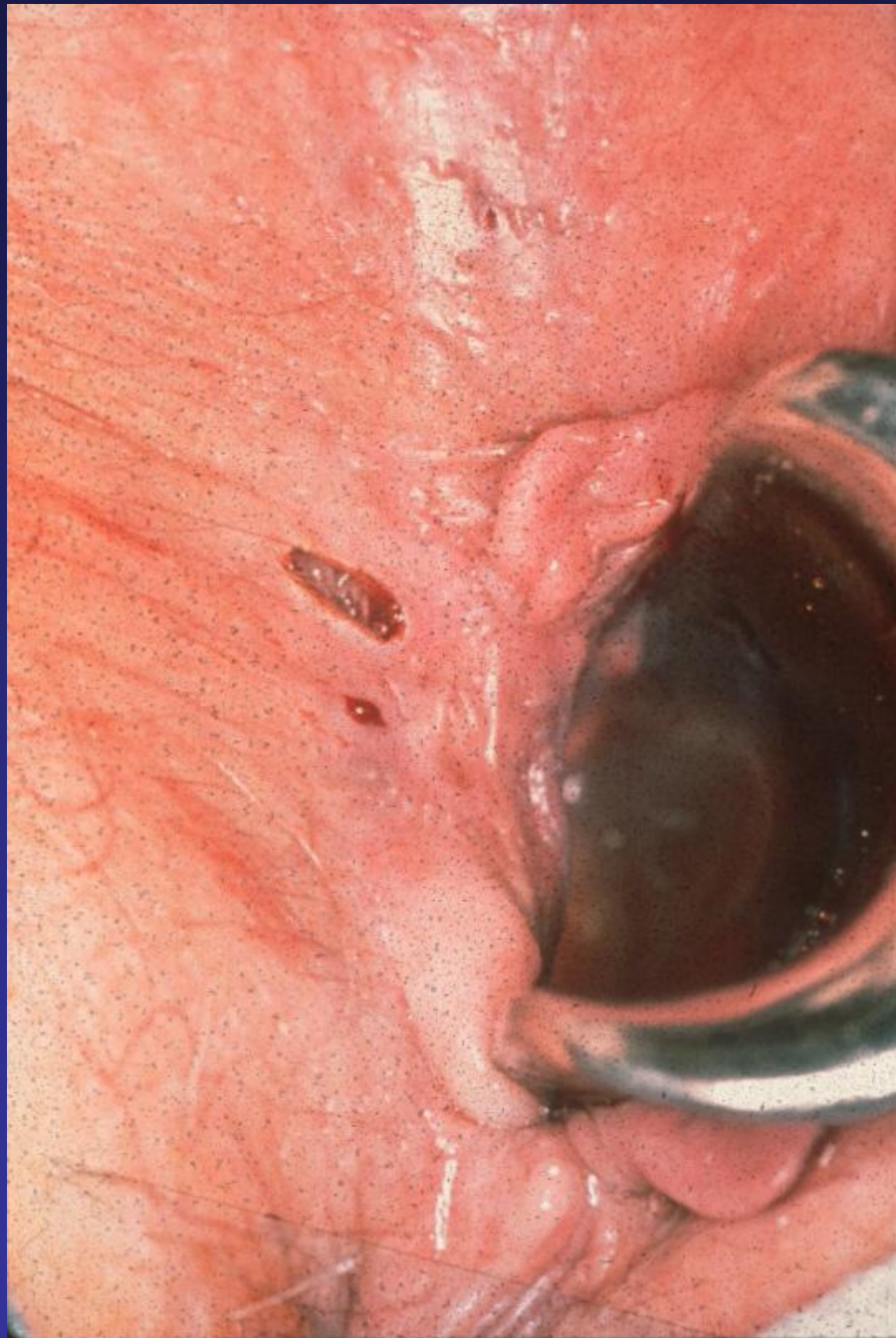


Skin incision made external to anal verge

Hypertrophied band of internal sphincter freed and elevated into incision



Internal sphincter divided; wound usually left open for drainage



Risks of Sphincterotomy

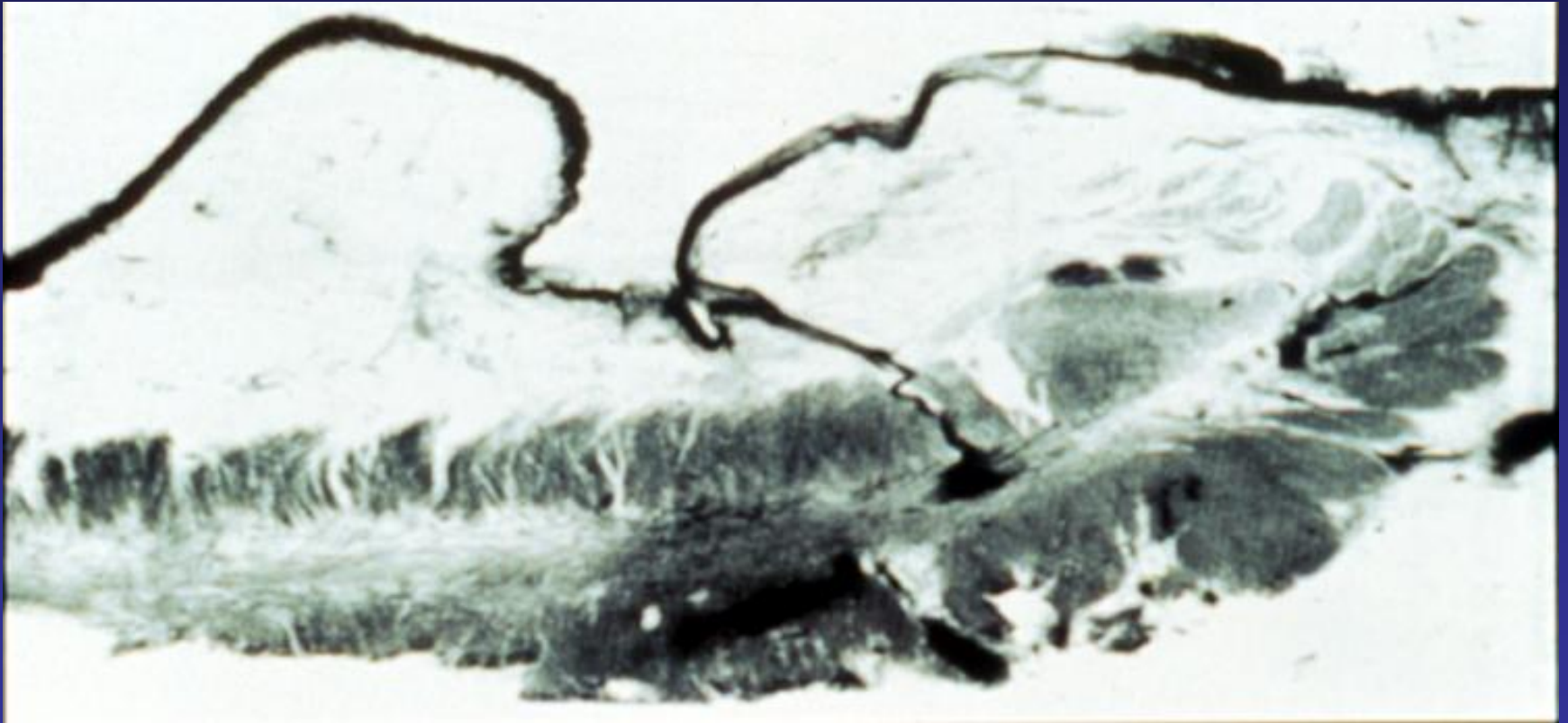
- Recurrence/persistence of fissure (2-10%)
- Incontinence to flatus (10-40%)
- Seepage/soiling, chronic irritation (up to 10%)
- Abscess

Abscess/Fistula

Abscess/Fistula

- Incidence: 8 per 100,000 – population based
- Male:Female – 3:1 to 2:1
- Seasonal incidence? Spring and summer
- Majority in 4th or 5th decade of life but range from 2 months to 8th decade

Abscess: Pathogenesis



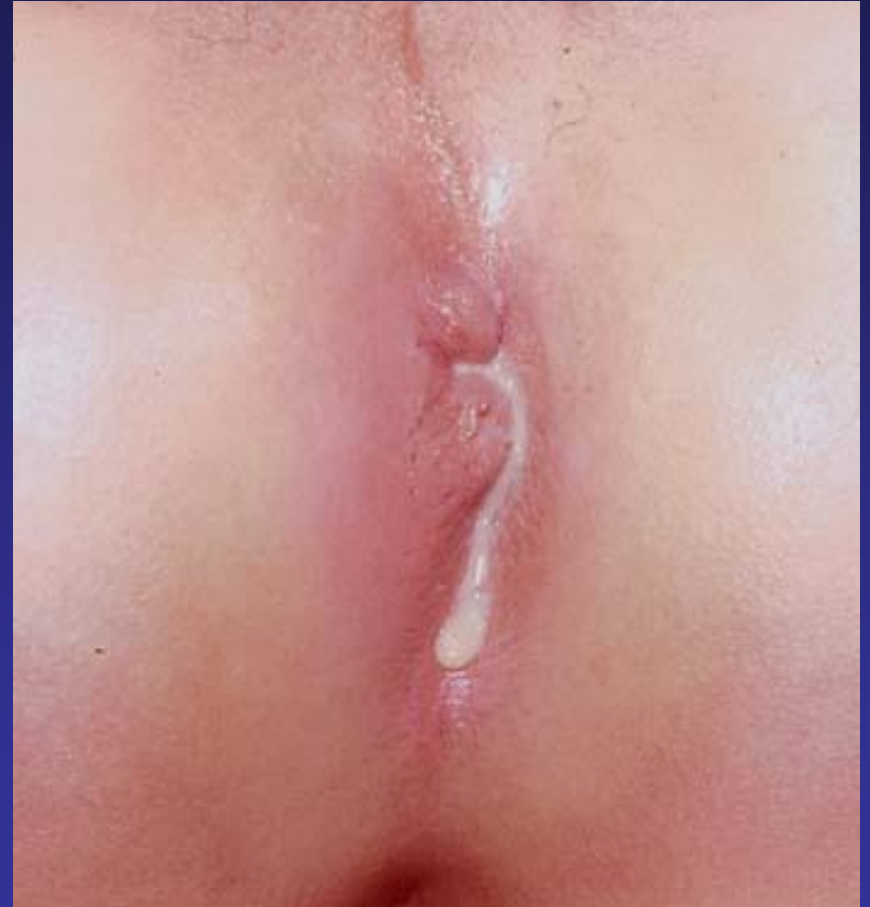-Parks, Br Jrnl Surg 1976

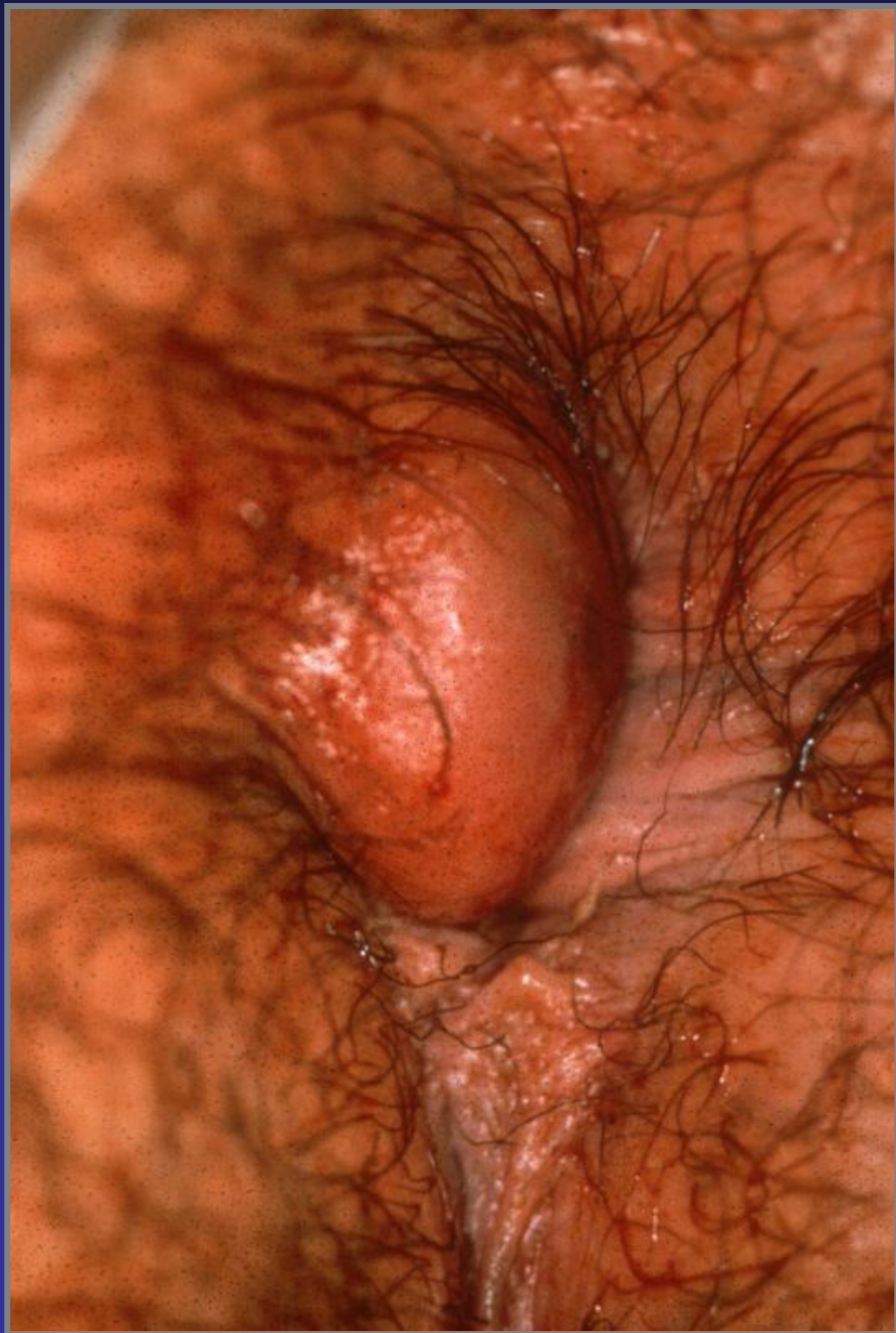Presentation

- Pain: Exacerbated by sitting, BM's
- Fever/Malaise
- Nonspecific symptoms if intersphincteric or supralelevator
- Digital exam difficult due to pain

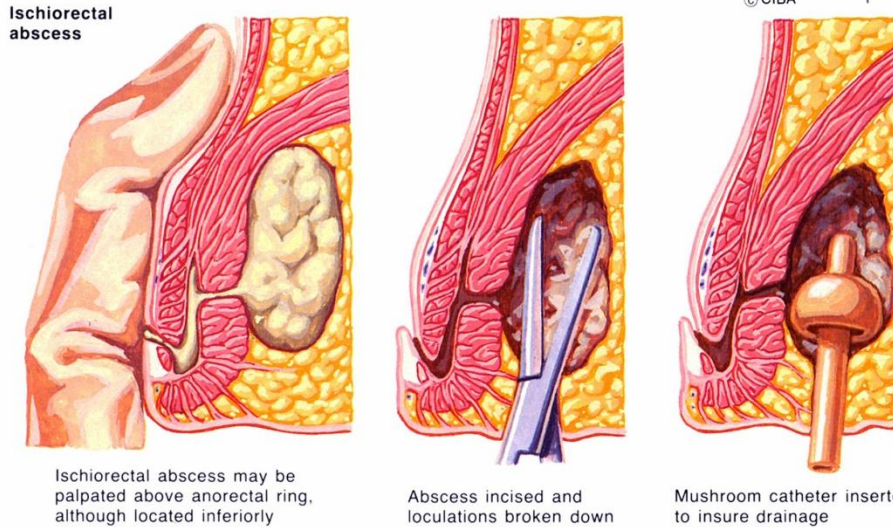
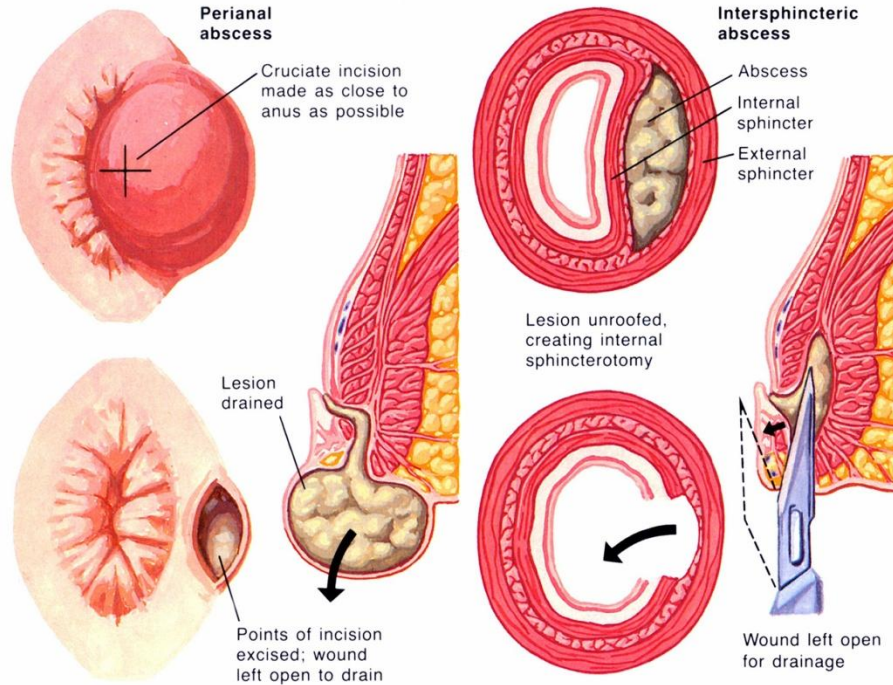
Treatment: Urgent I&D

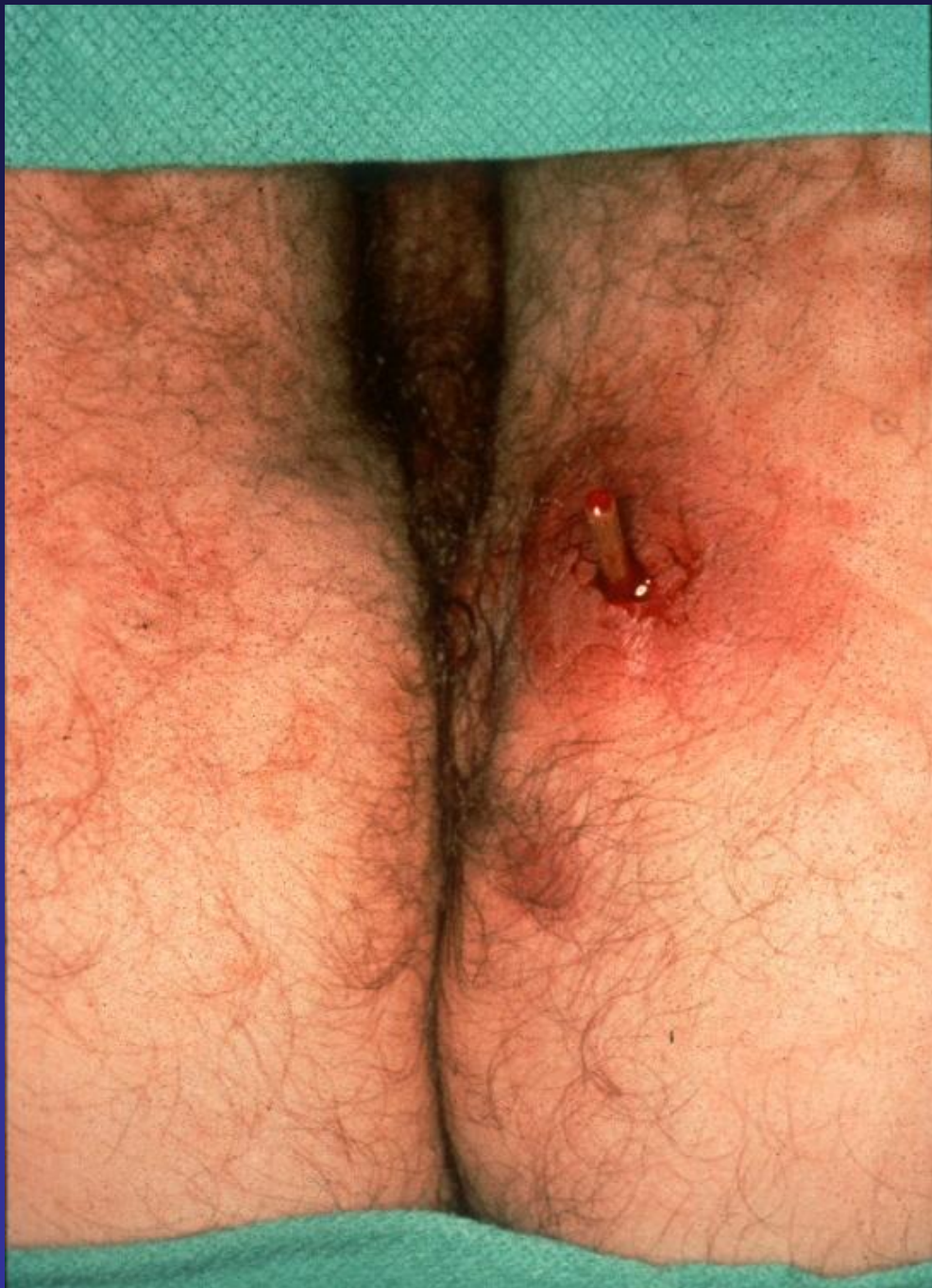- Local vs general anesthesia
- Technique
 - Where:
 - Transrectal vs percutaneous
 - Zone of greatest fluctuance
 - As near anus as possible

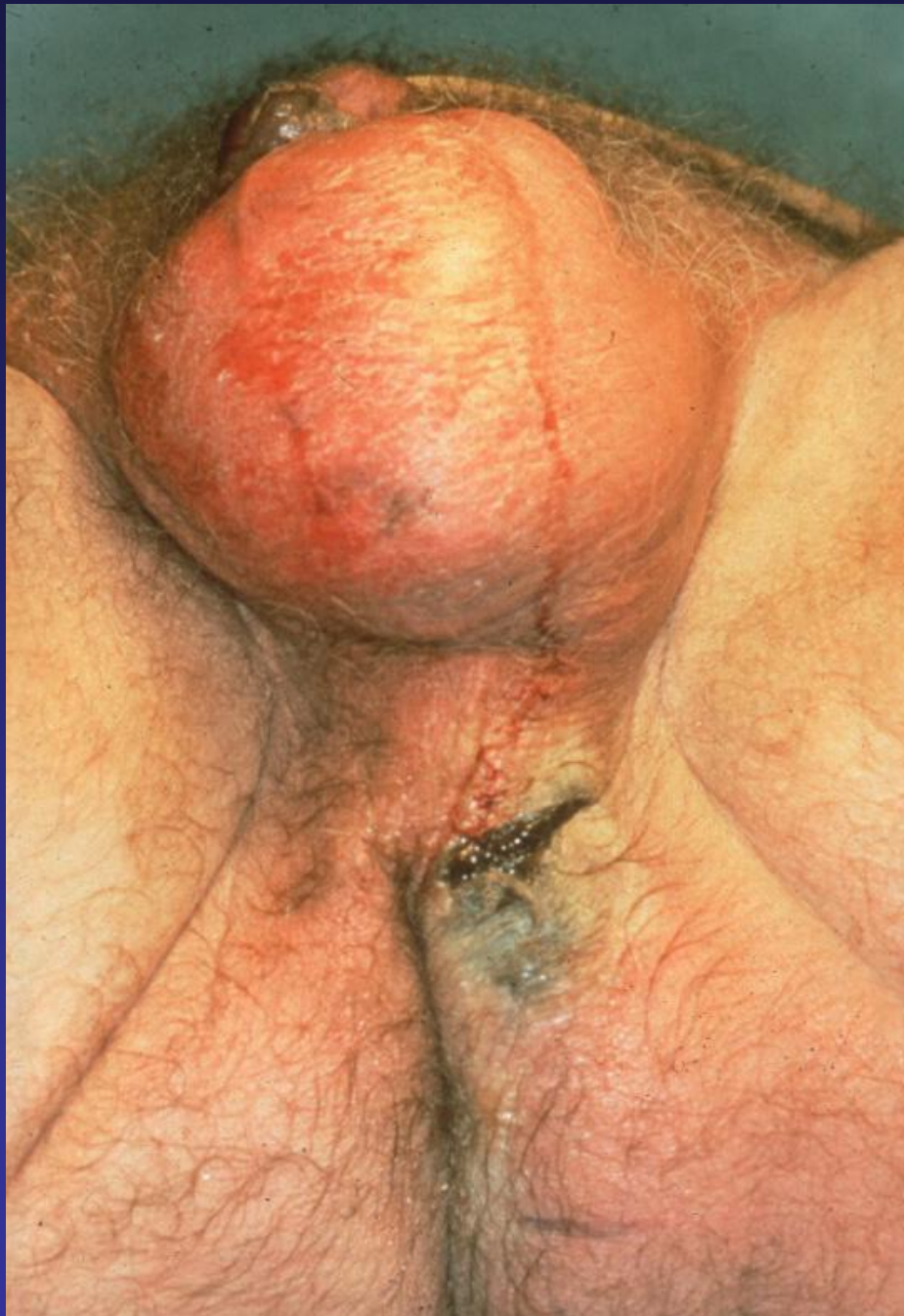

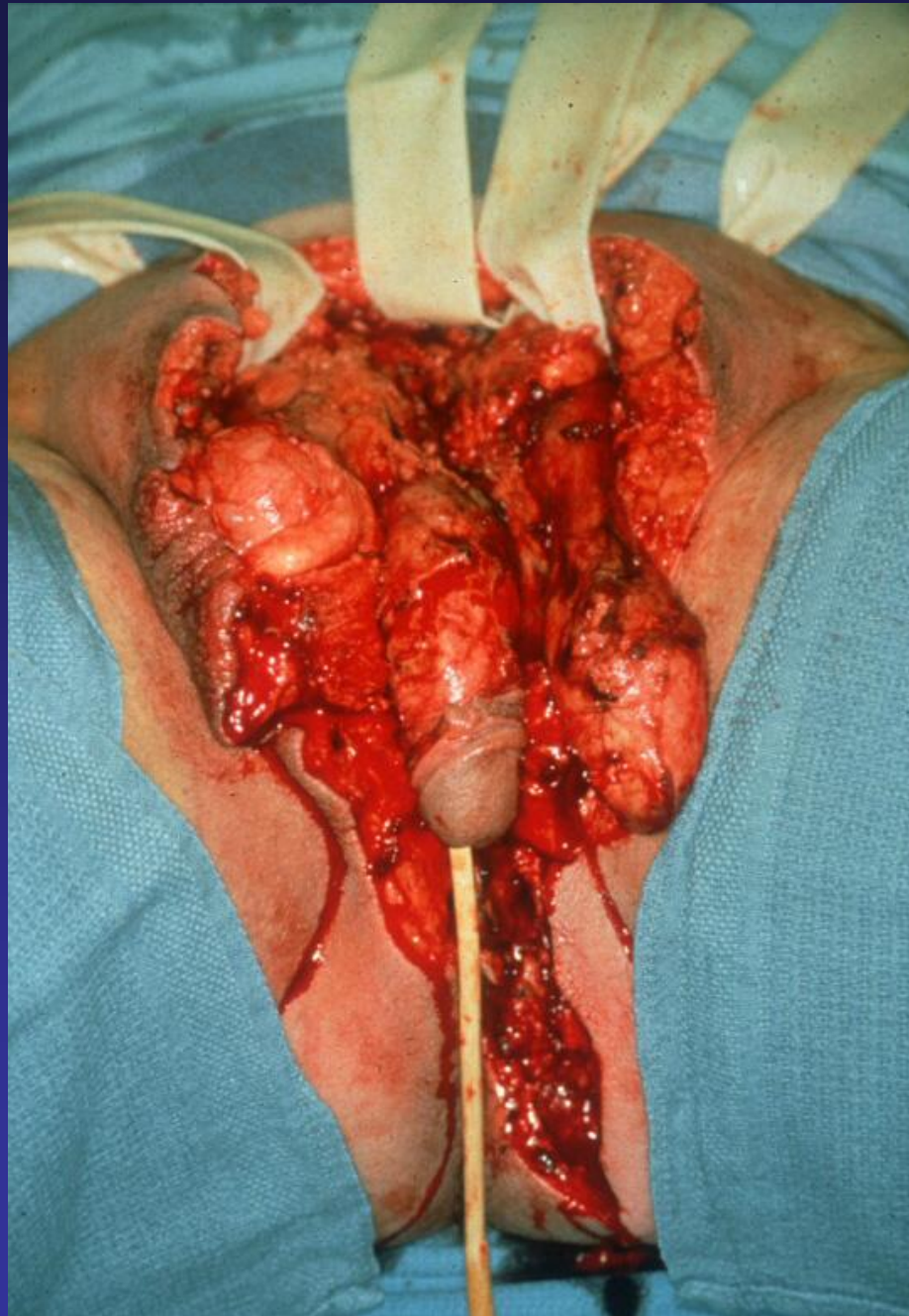


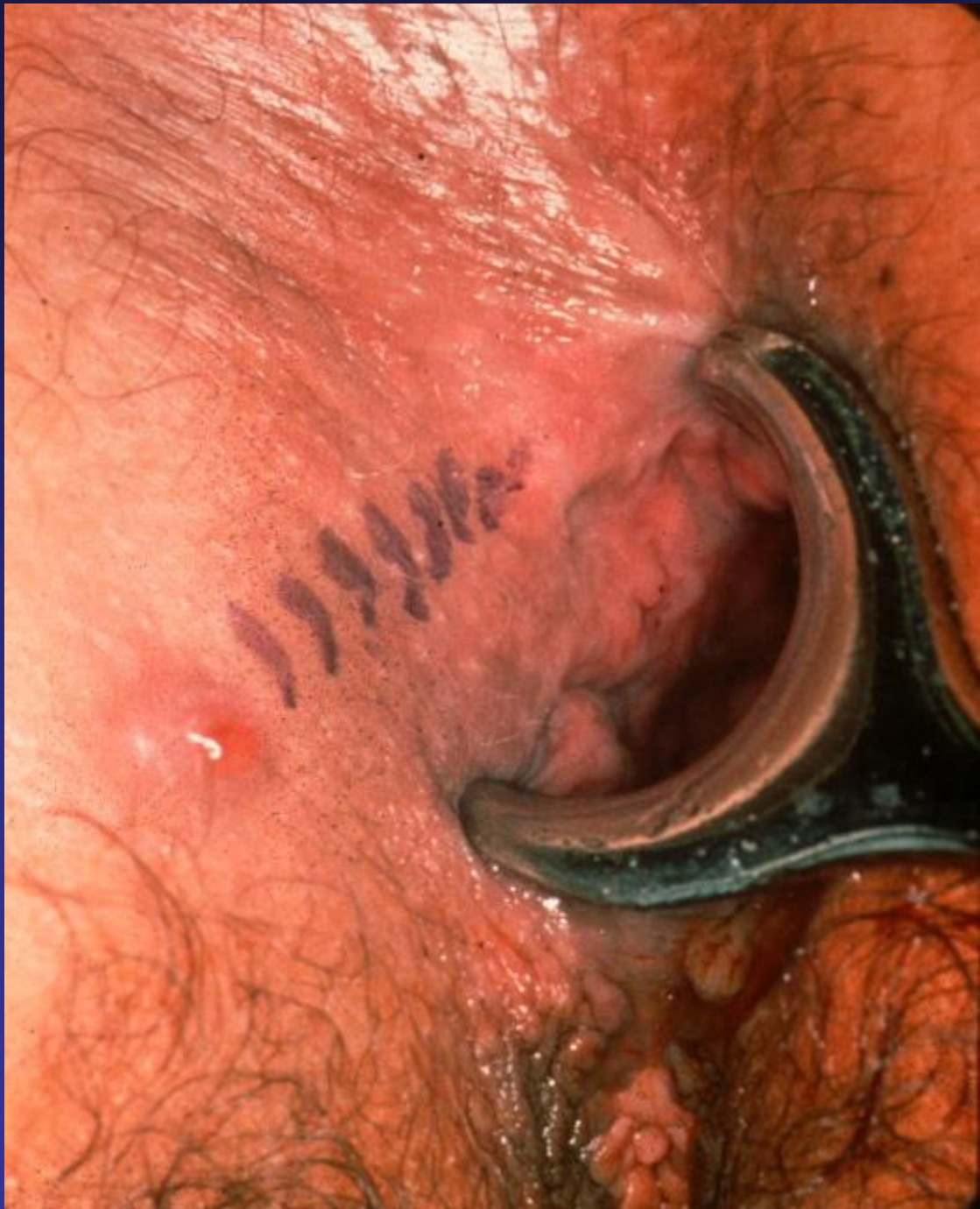Surgical Management of Anorectal Abscess

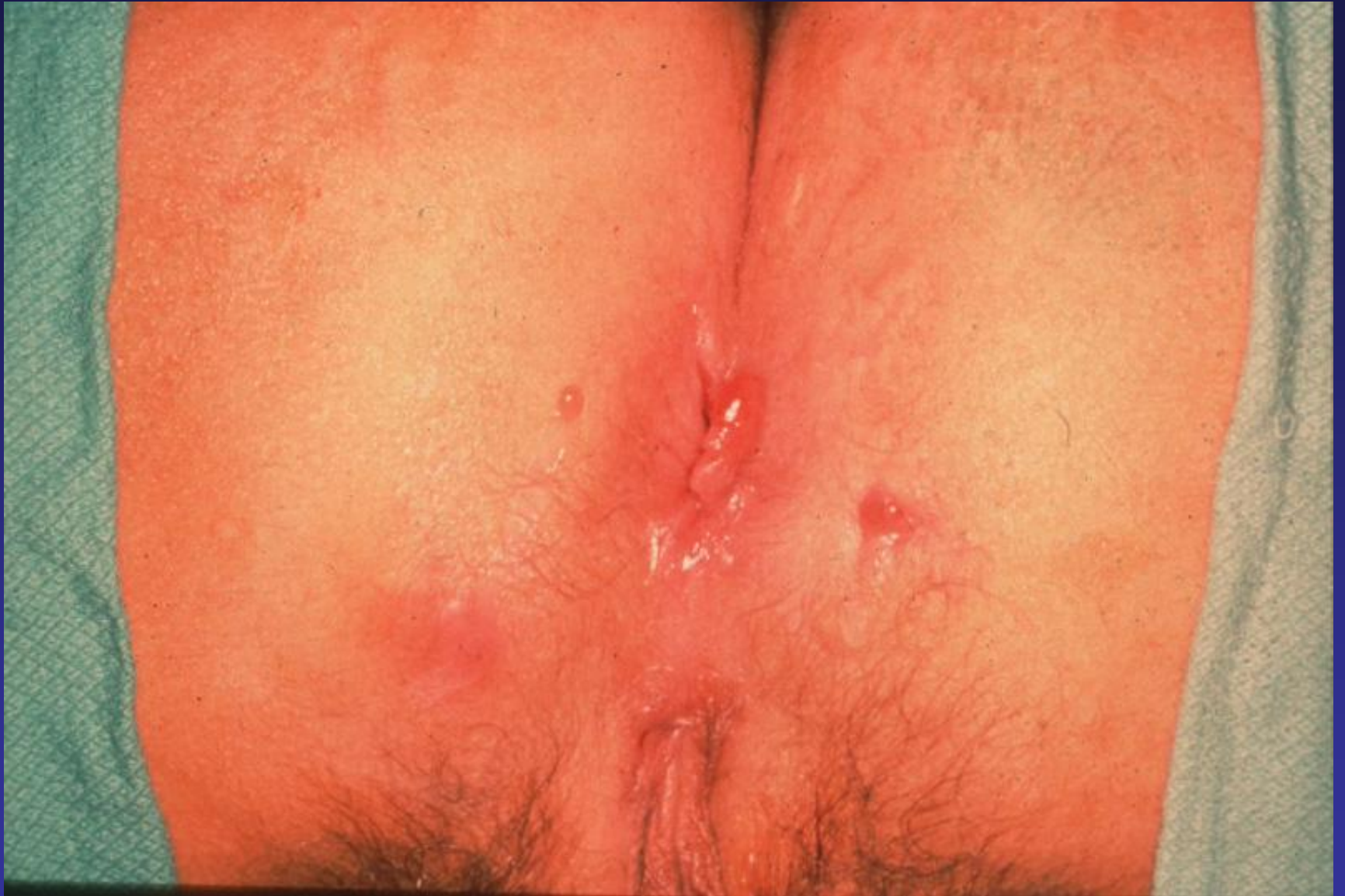



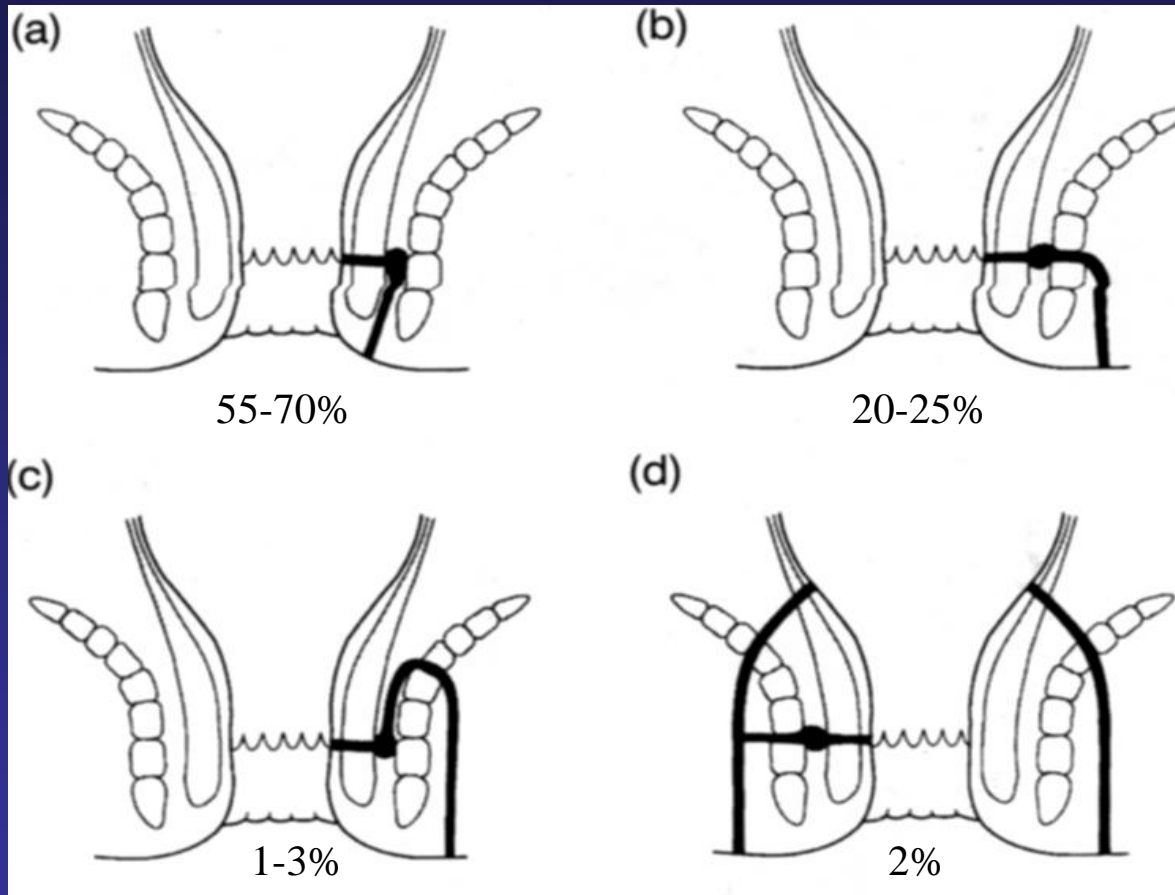






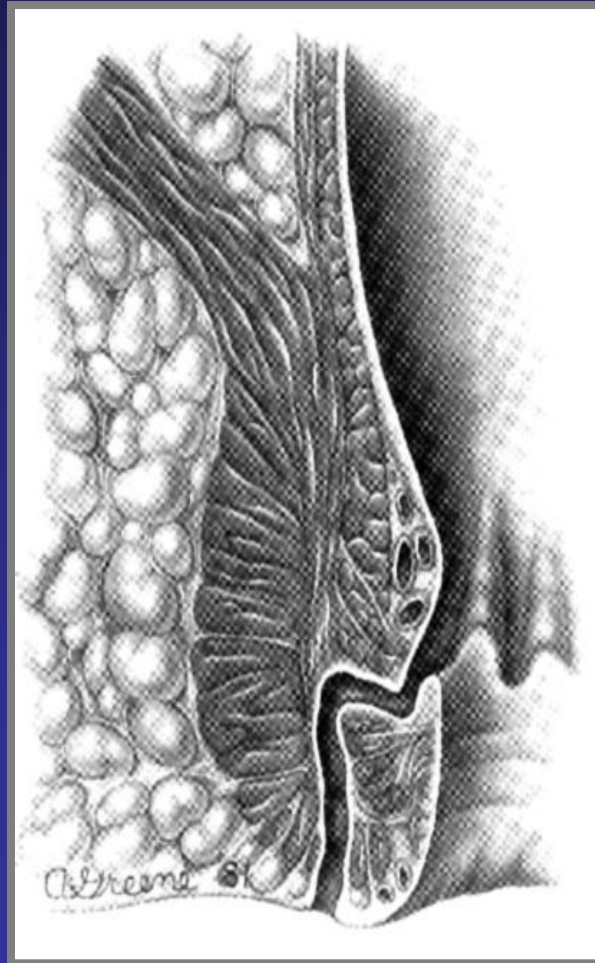


Fistula-in-Ano

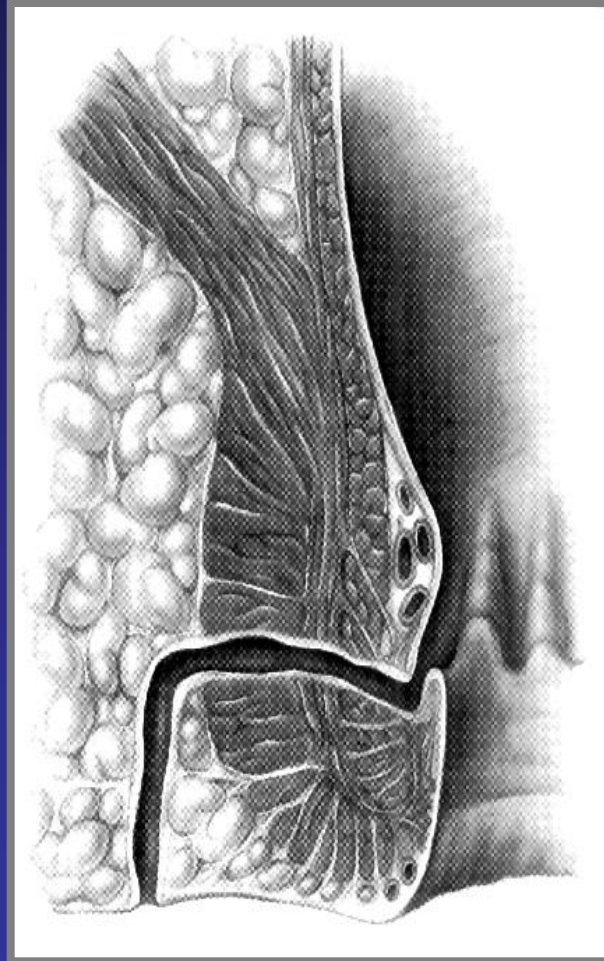


a. Intersphincteric, b. Transsphincteric, c. Suprasphincteric, d. Extrasphincteric

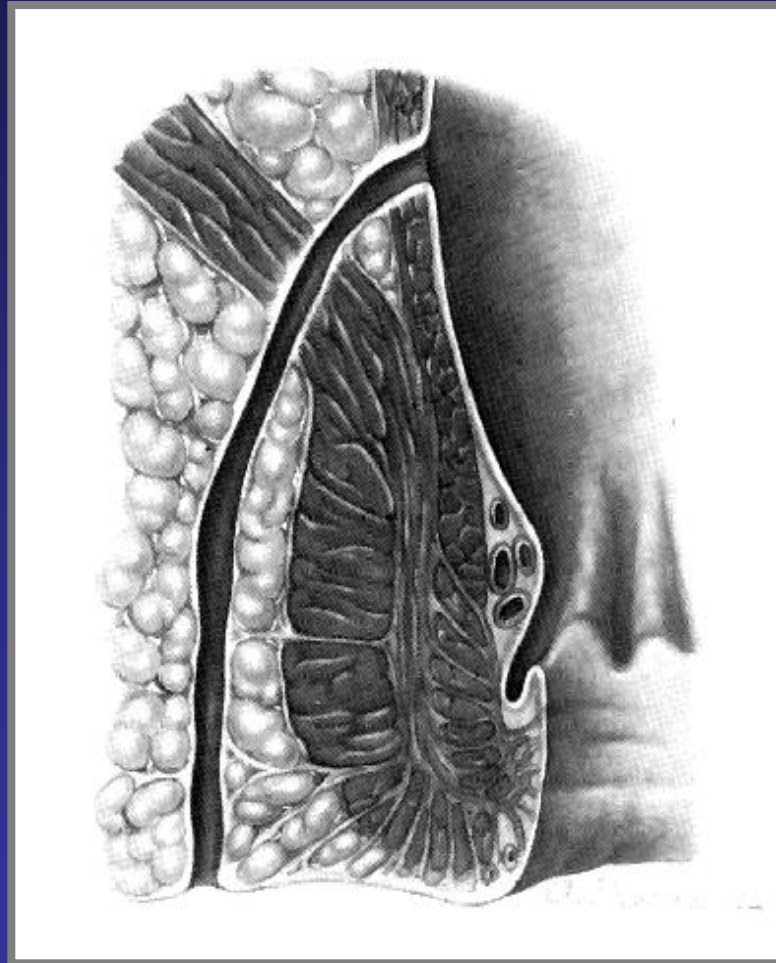
Fistula-in-Ano: Intersphincteric



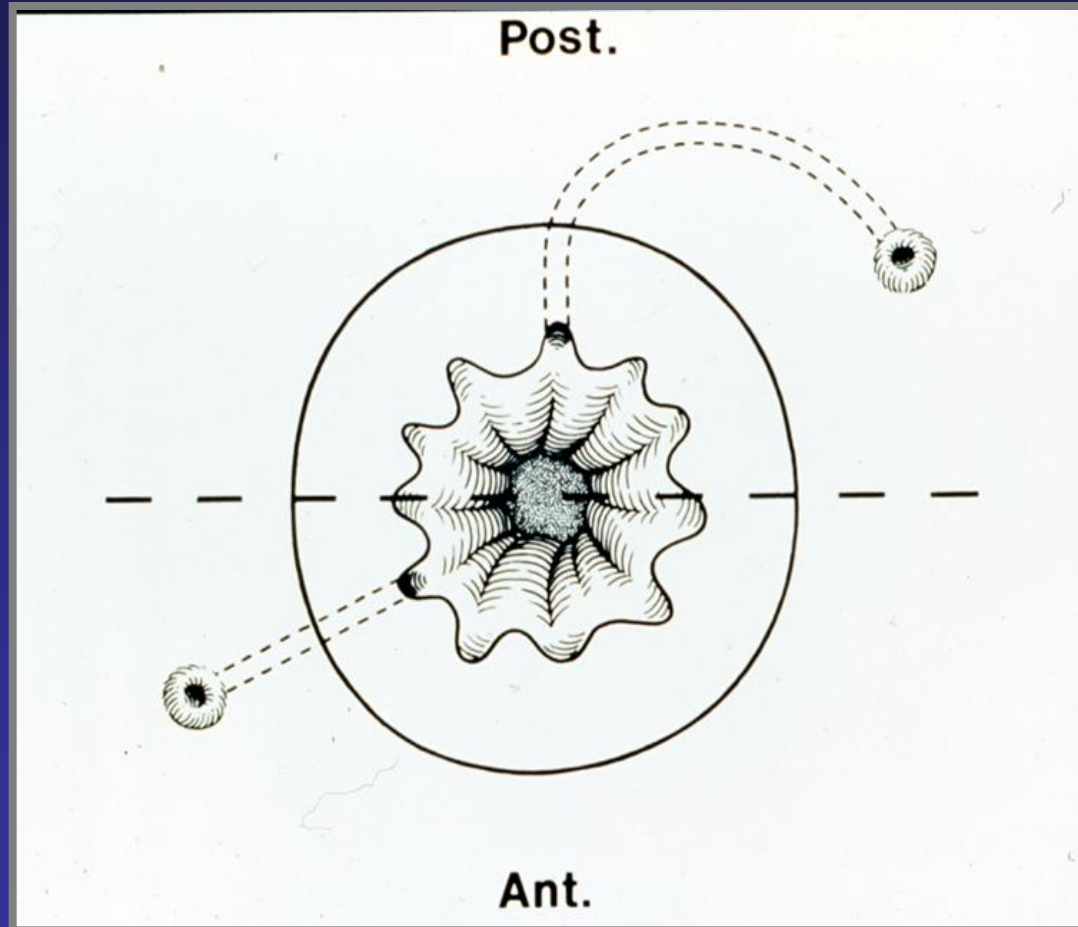
Fistula-in-Ano: Transsphincteric



Fistula-in-Ano: Extrasphincteric



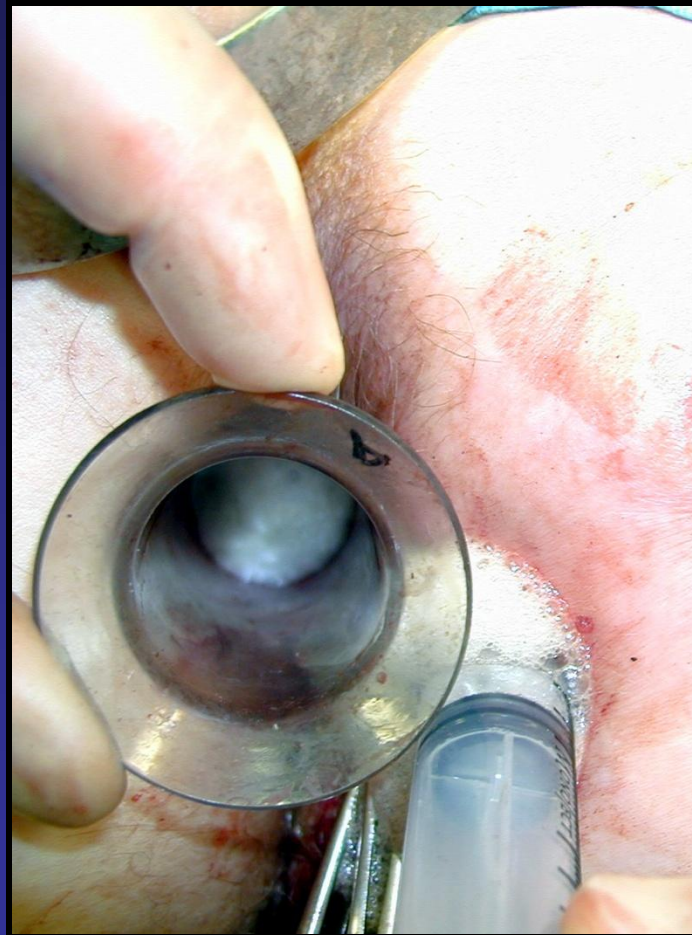
Goodsall's Rule



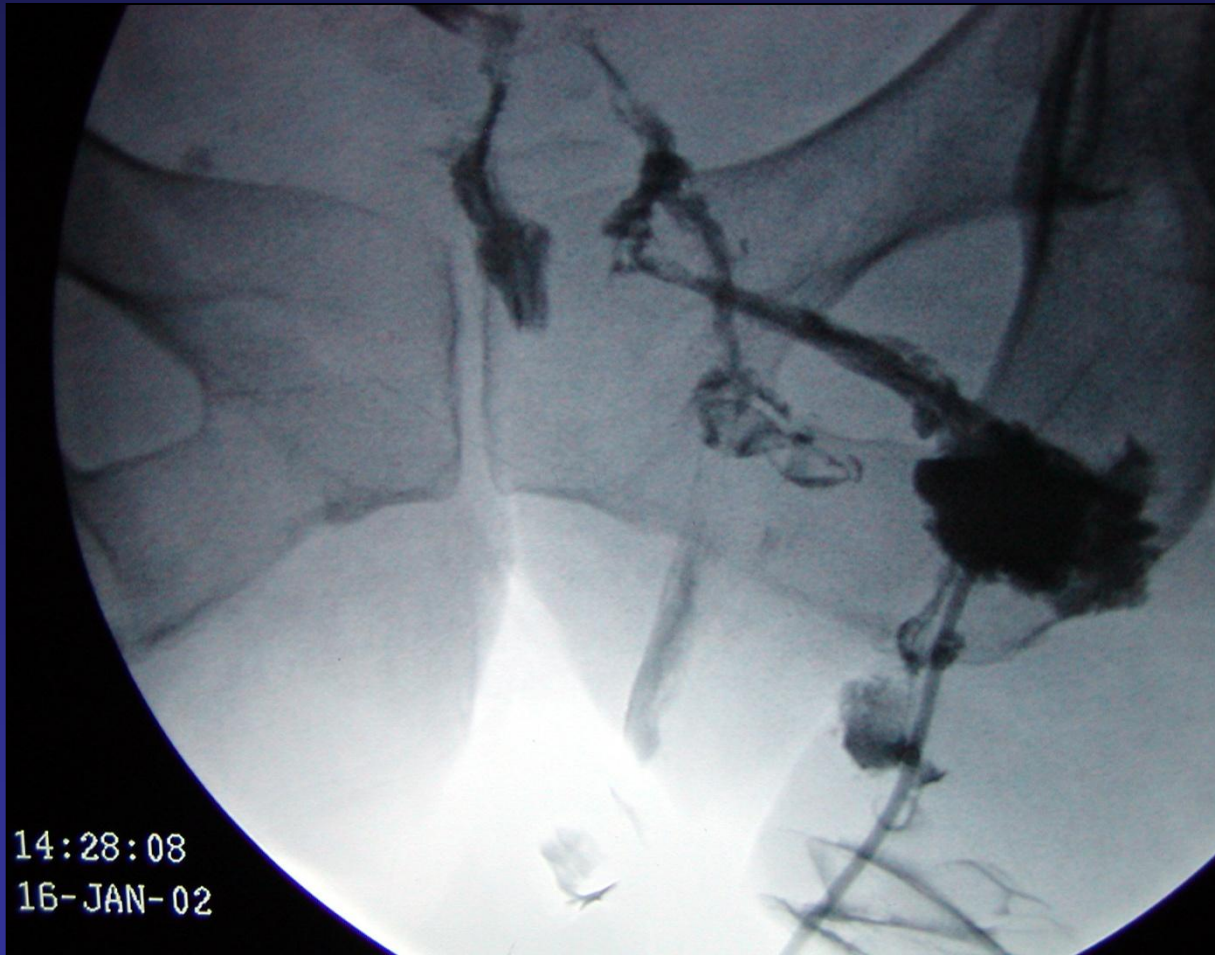
Goodsall's Rule: Not So Good?

- Posterior opening: 90% followed rule
- Anterior opening: 49% followed rule
 - 71% tracked to anterior midline
 - 39% of men unpredictable course
 - 10% of women unpredictable course

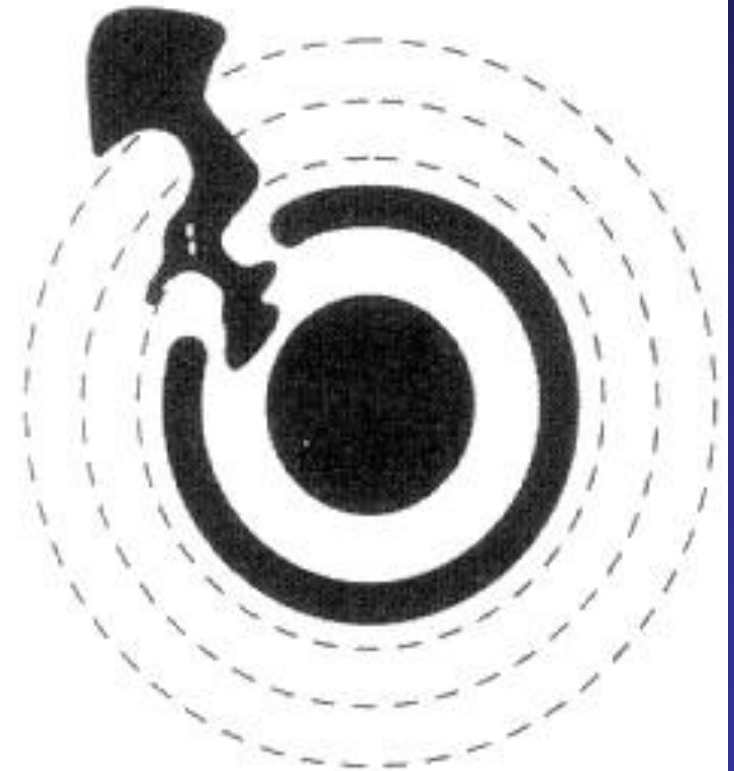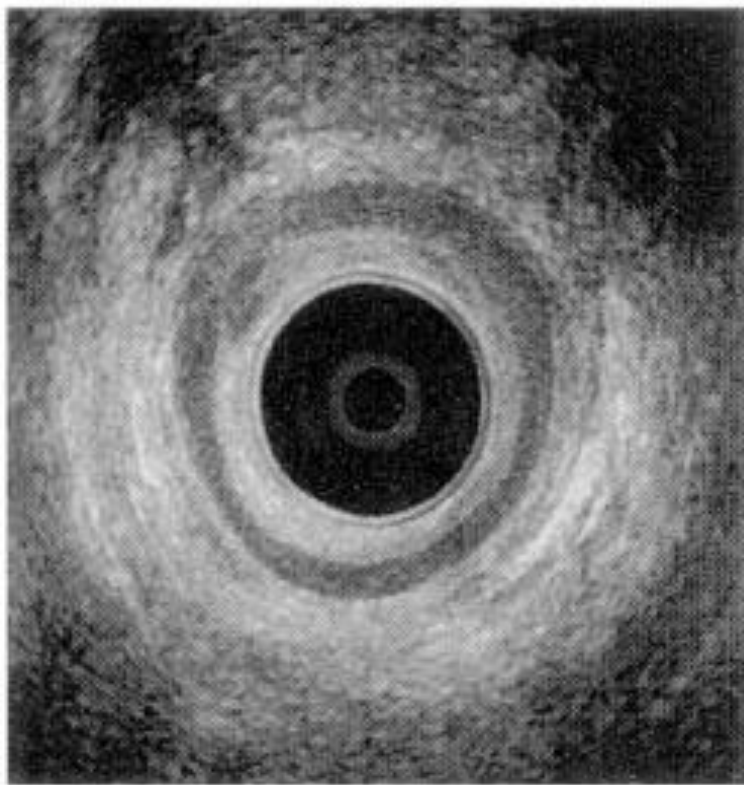
Fistula-in-Ano: Diagnosis



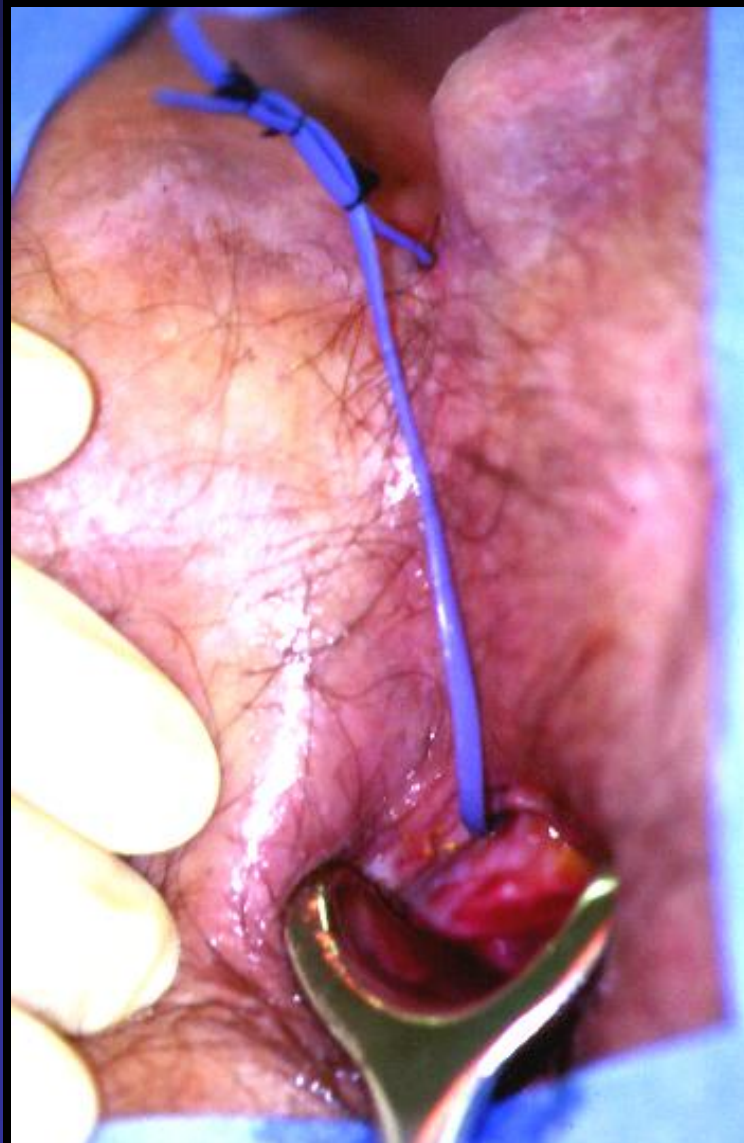Fistula-in-Ano: Diagnosis



Fistula-in-Ano: Diagnosis

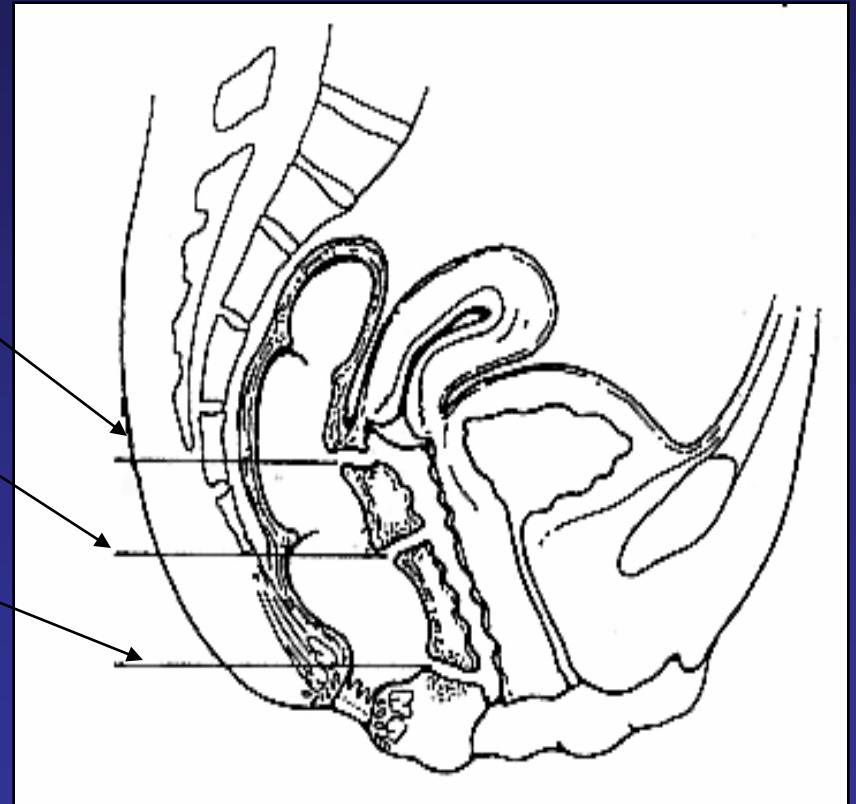


Draining Seton



Rectovaginal Fistula

- High fistula - Diverticulitis
- Mid fistula – Crohn's Disease, radiation
- Low fistula – cryptoglandular, obstetric



Hidradenitis Suppurativa

- **Prevalence**

- seborrheic skin type

- obesity

- heavy perspiration

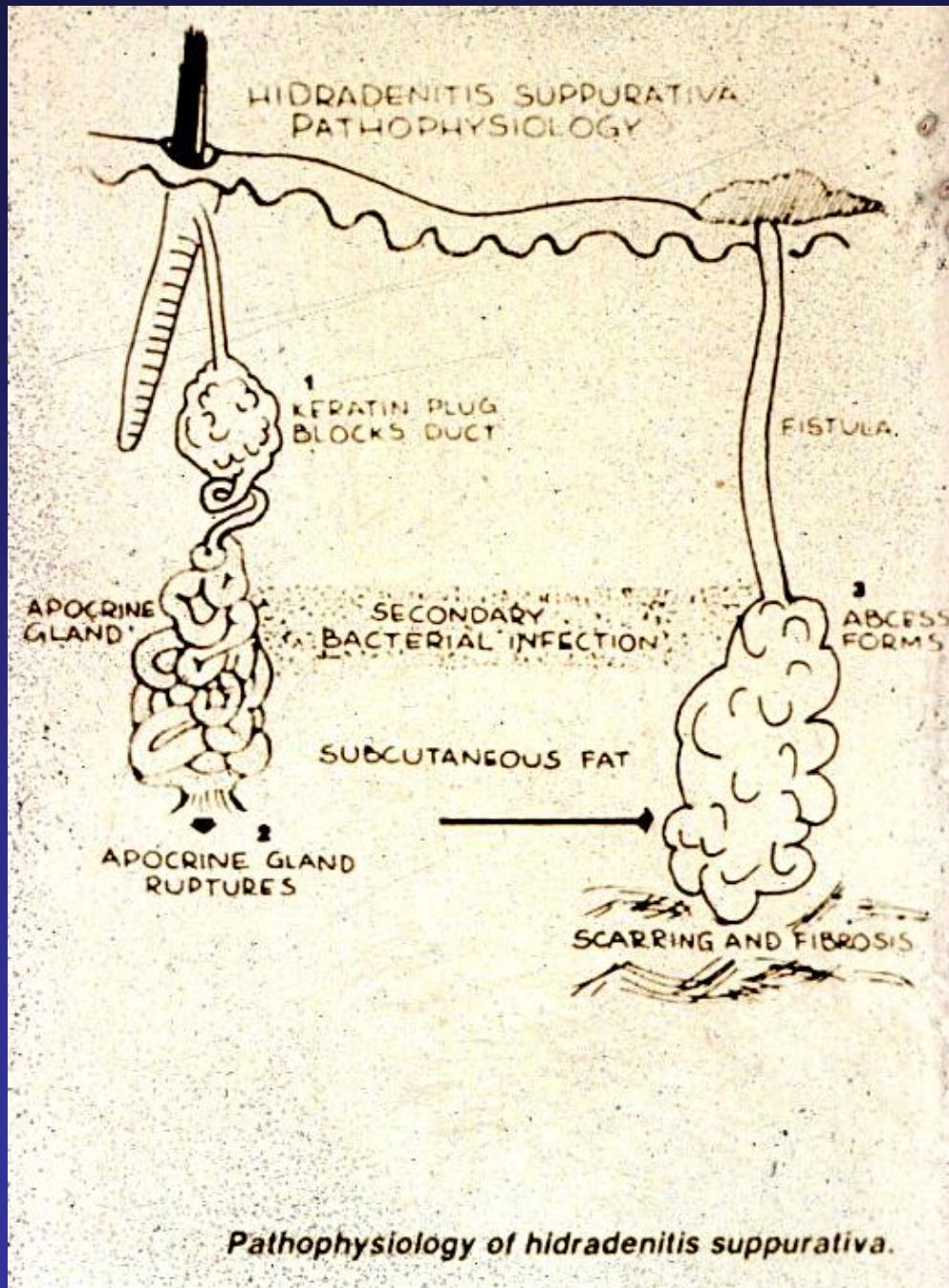
- cystic acne in face, neck, axillae, groin

- **Treatment**

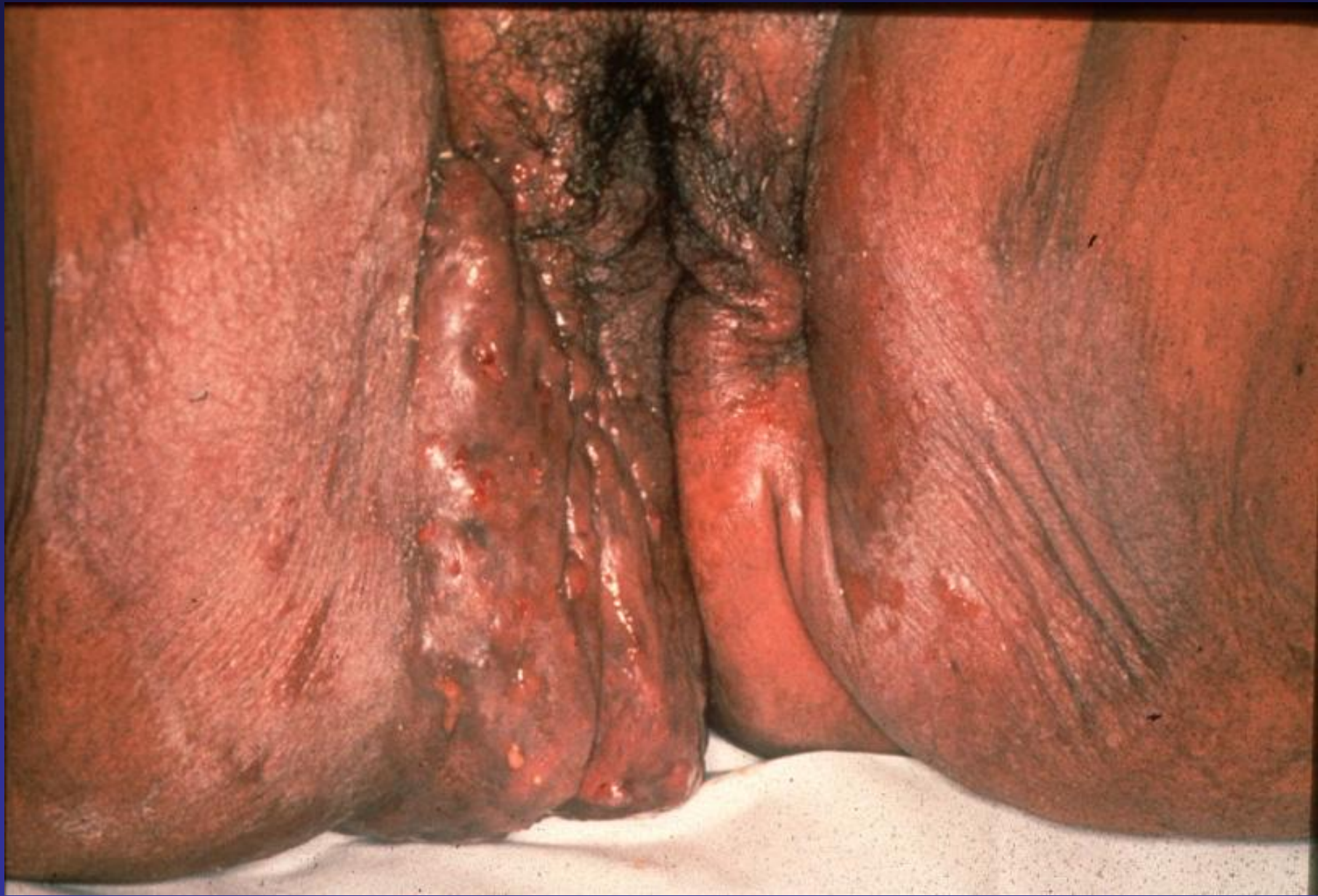- incision, drainage, unroofing

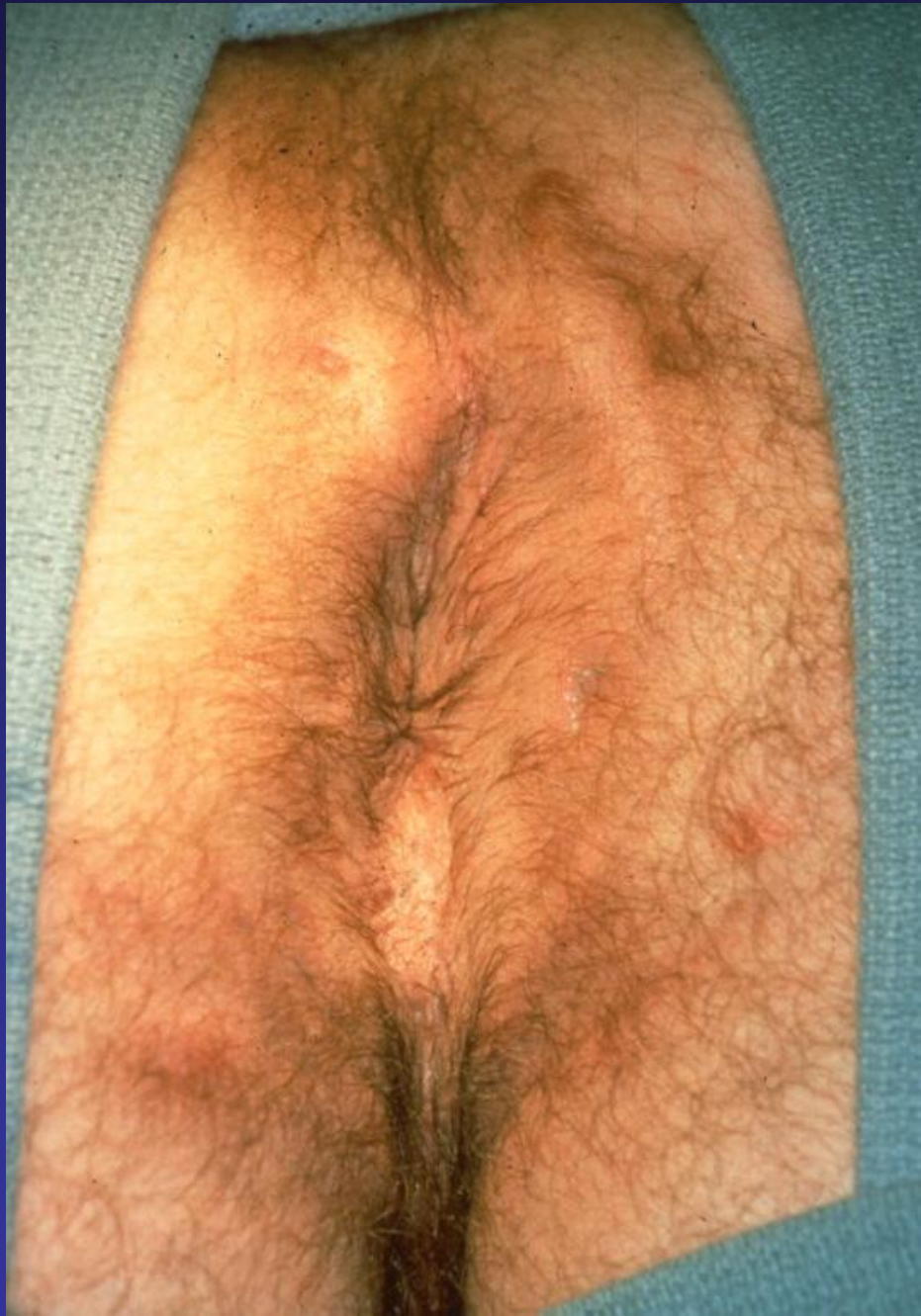- excision of chronic disease

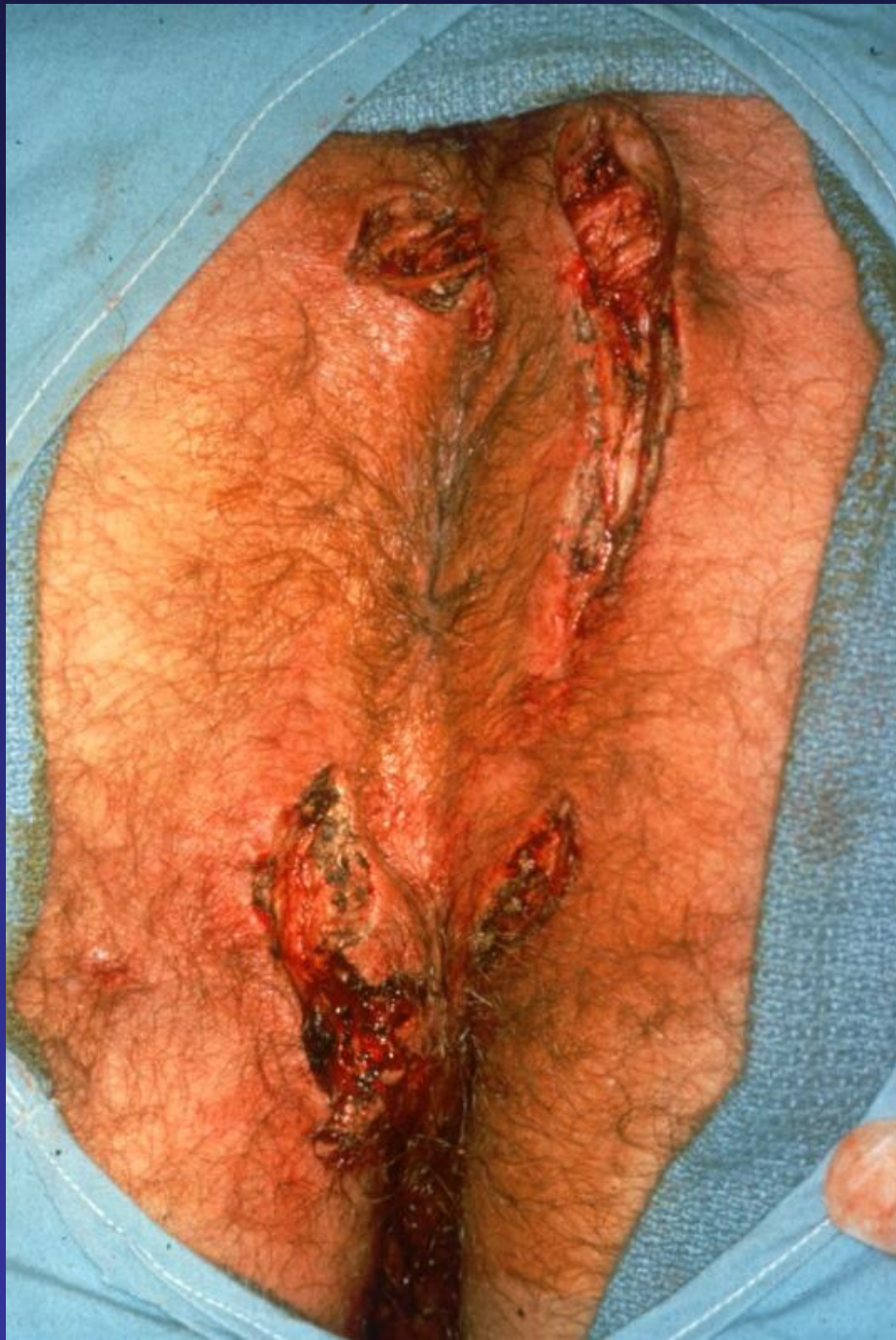- rare need for stoma

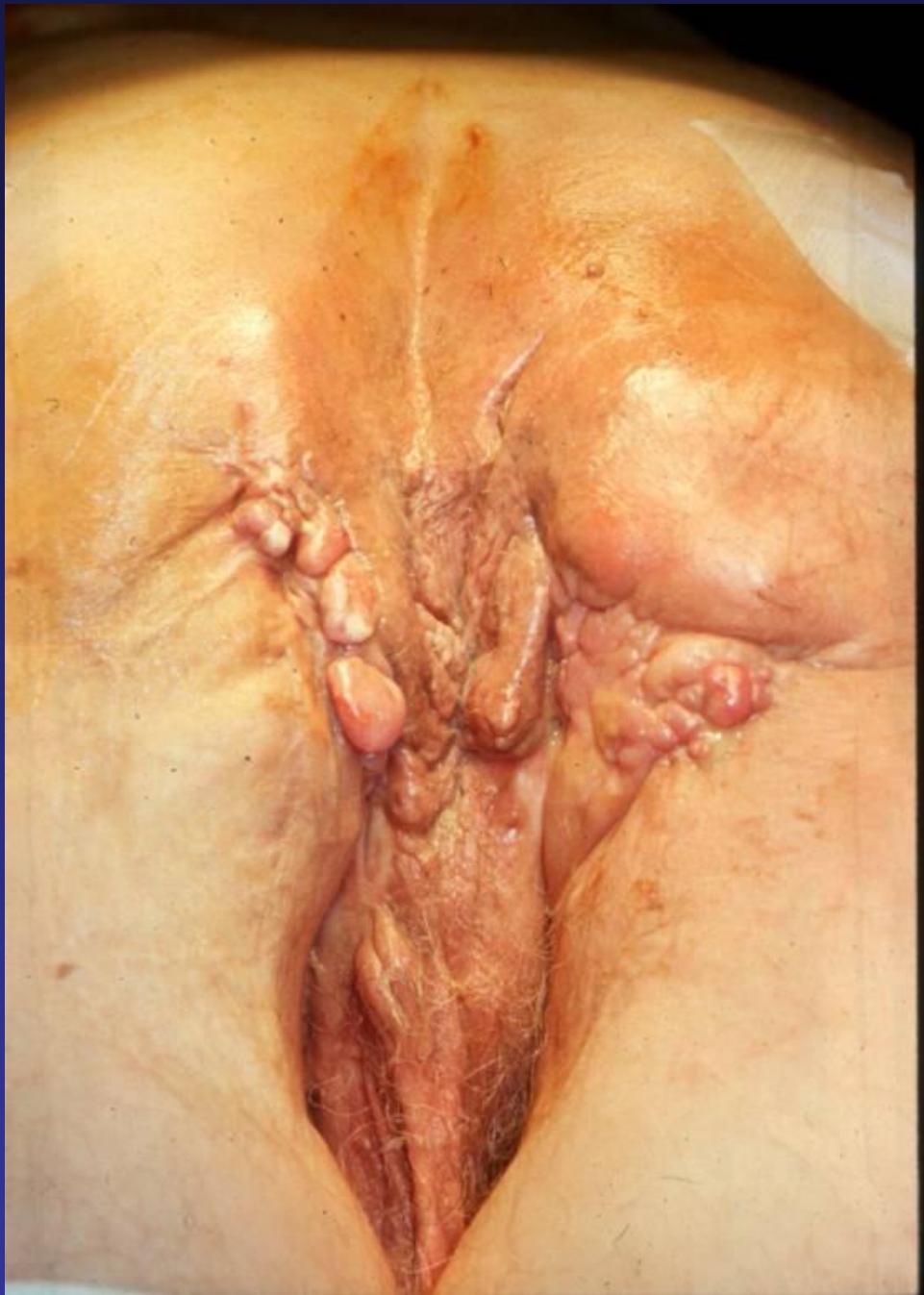

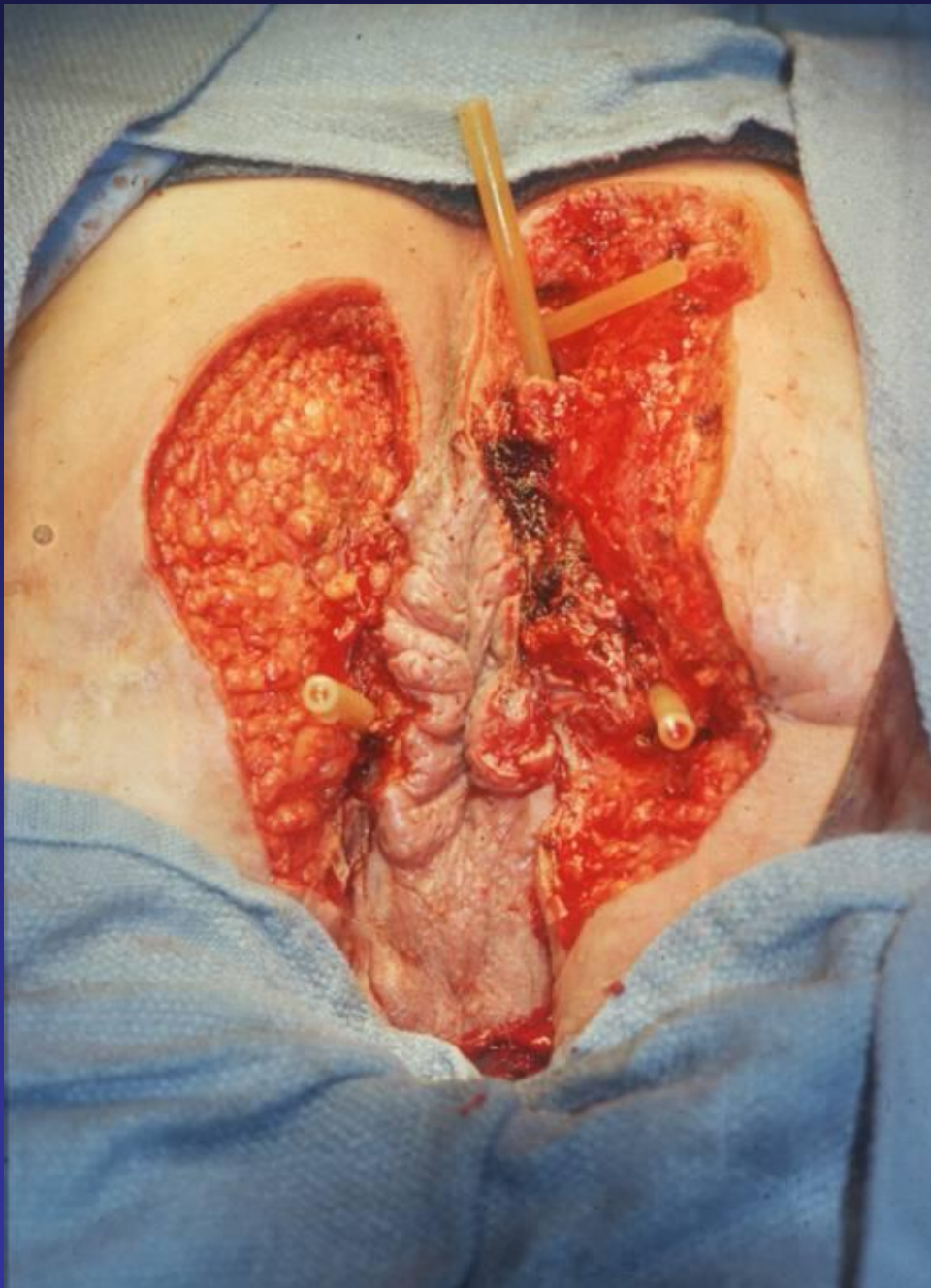
Pathophysiology of hidradenitis suppurativa.



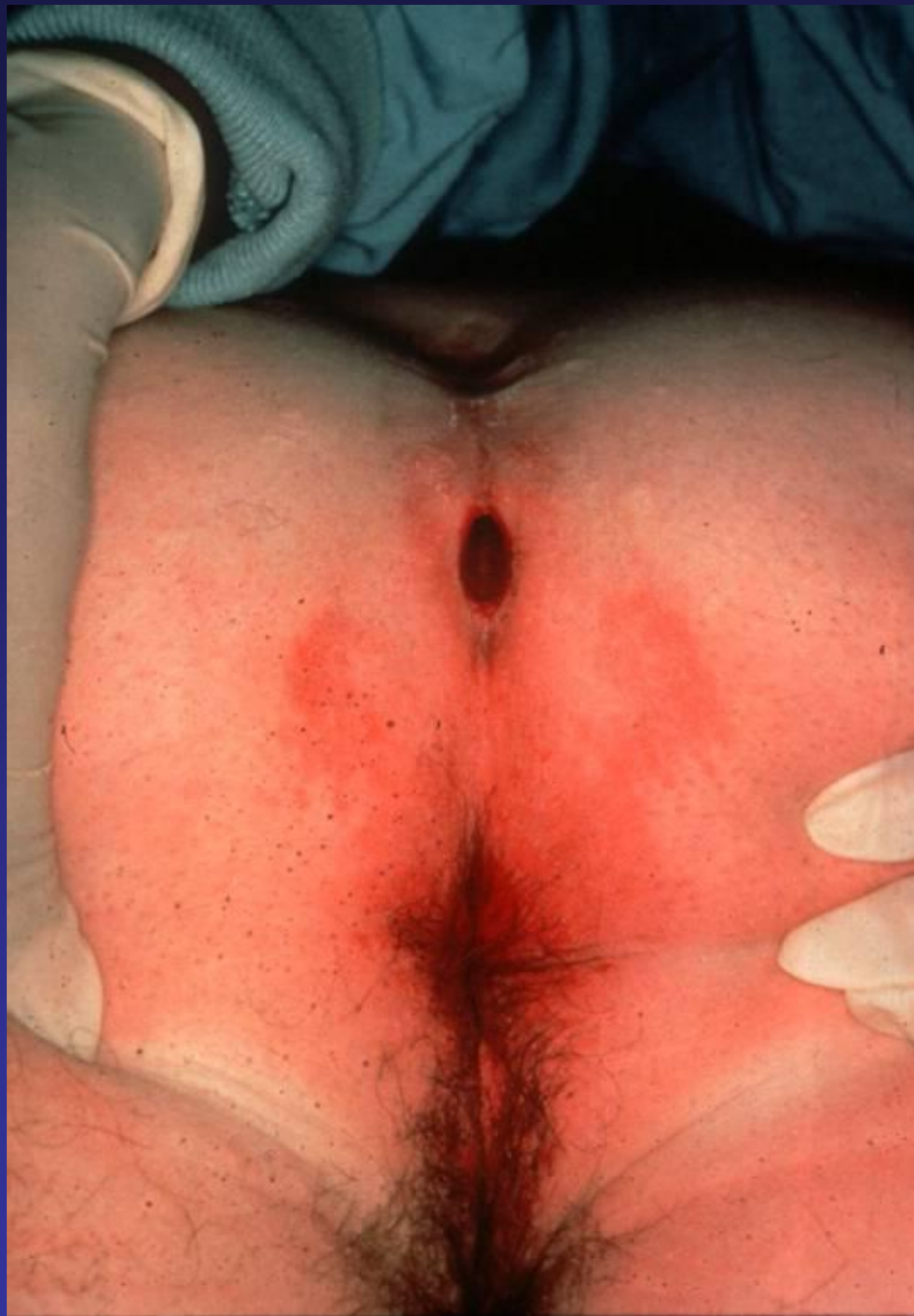


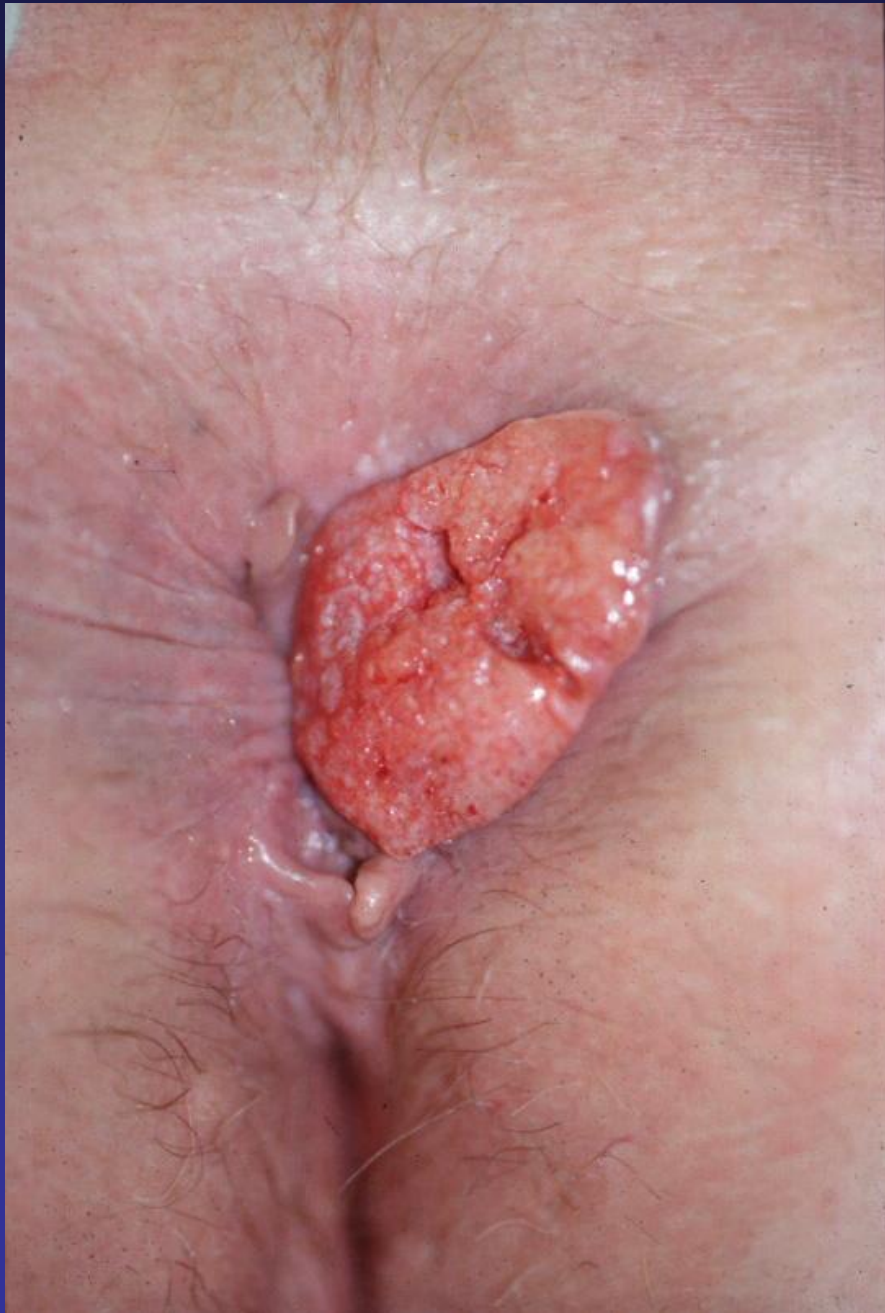


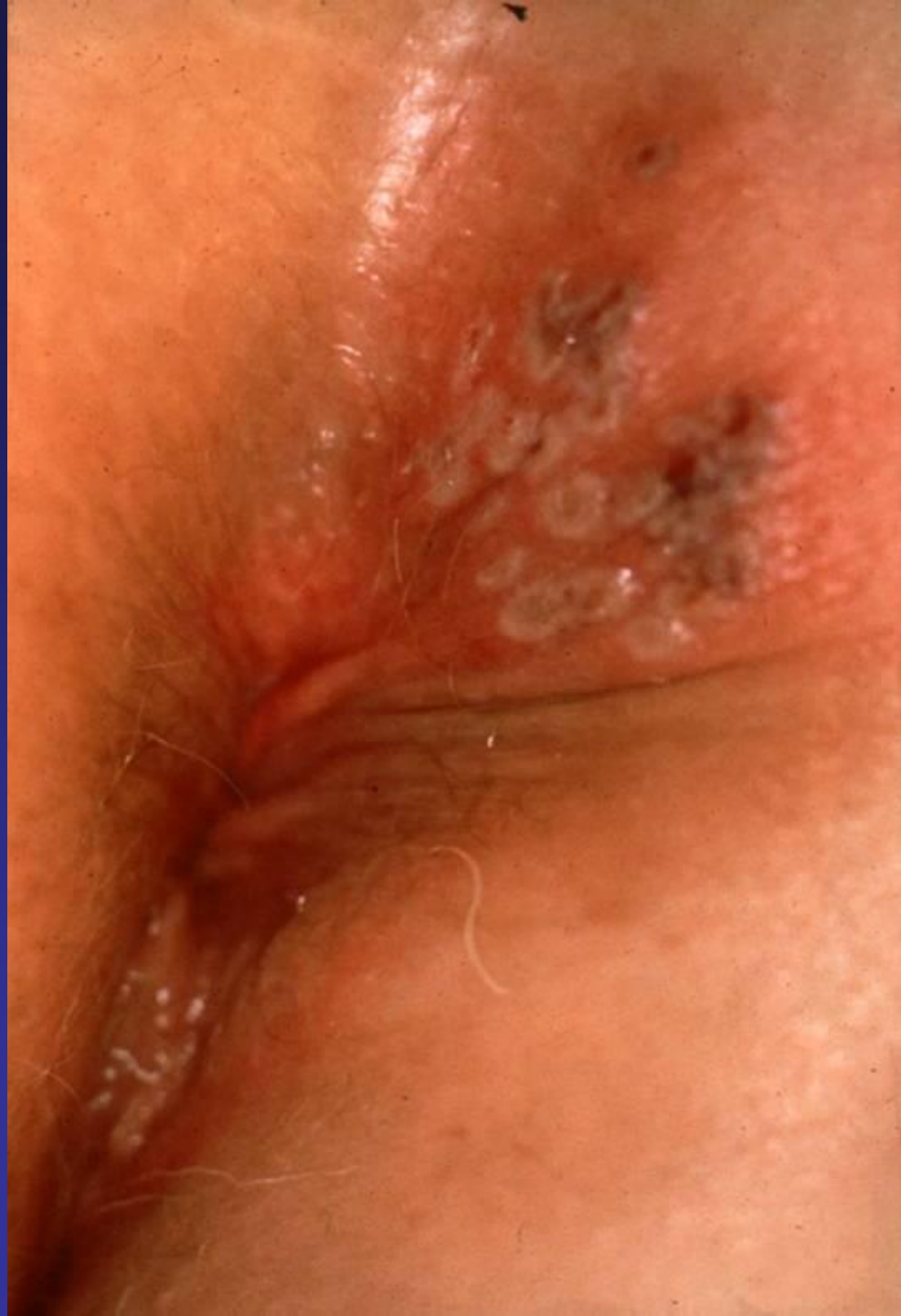

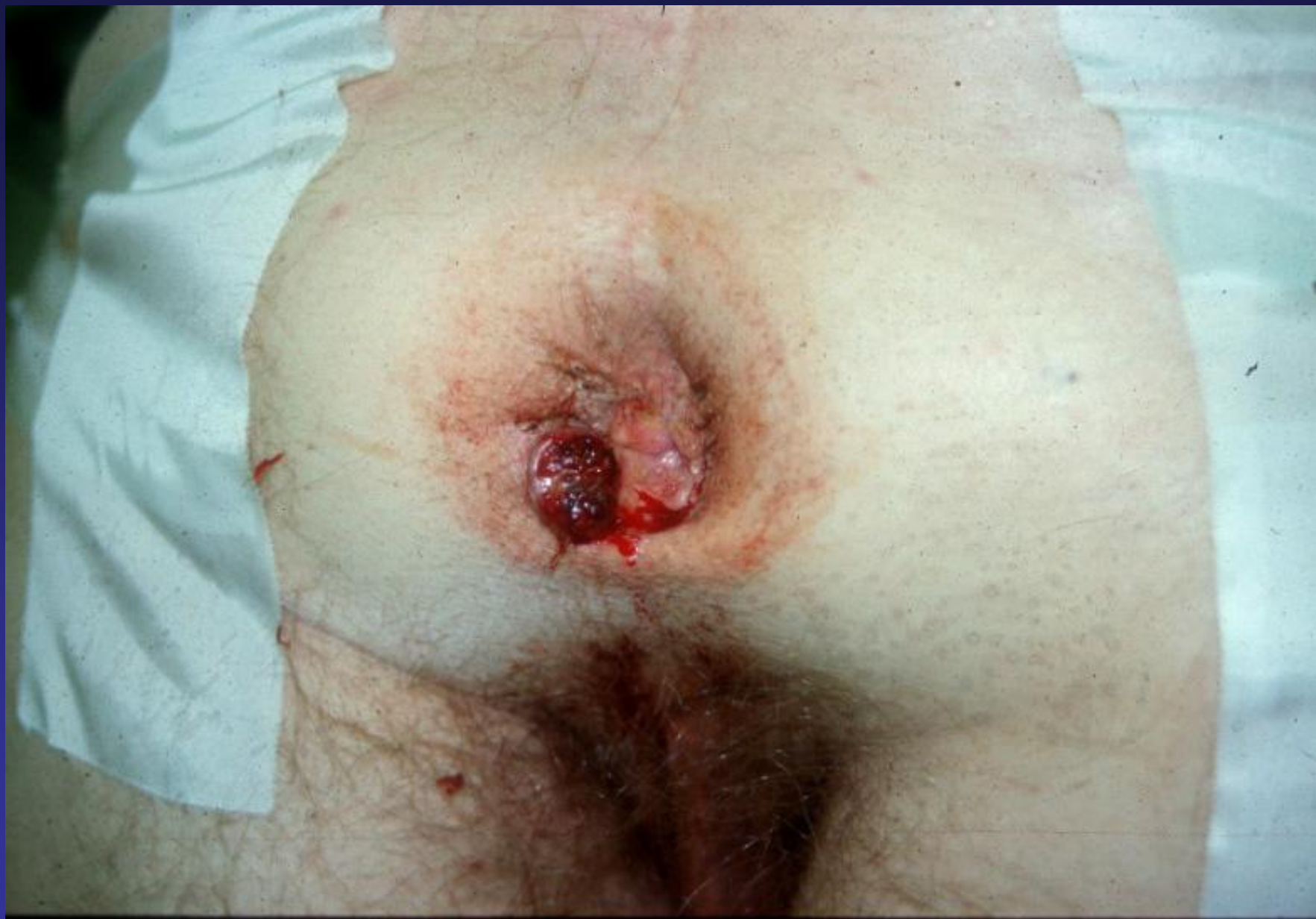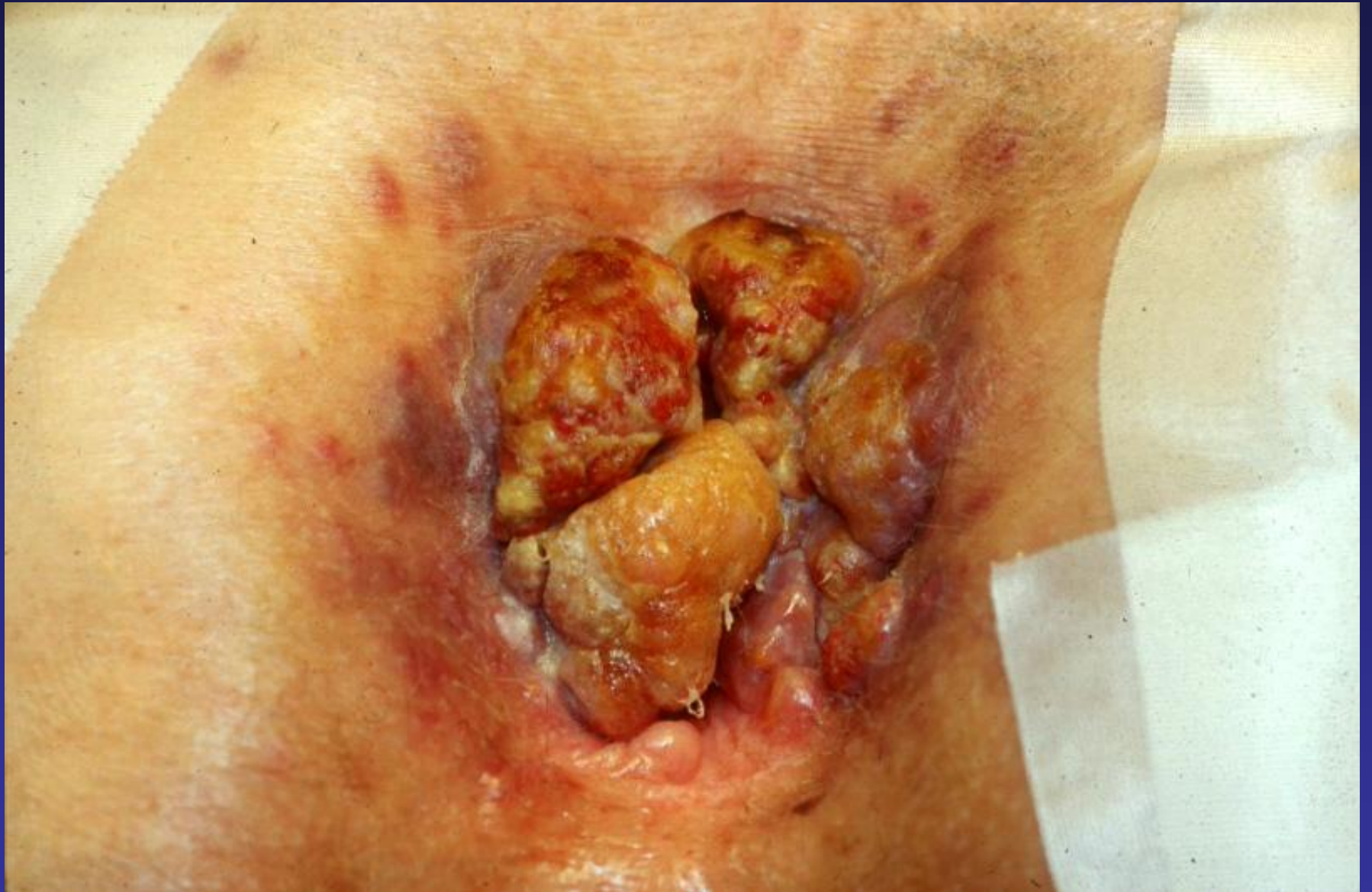Miscellaneous Conditions

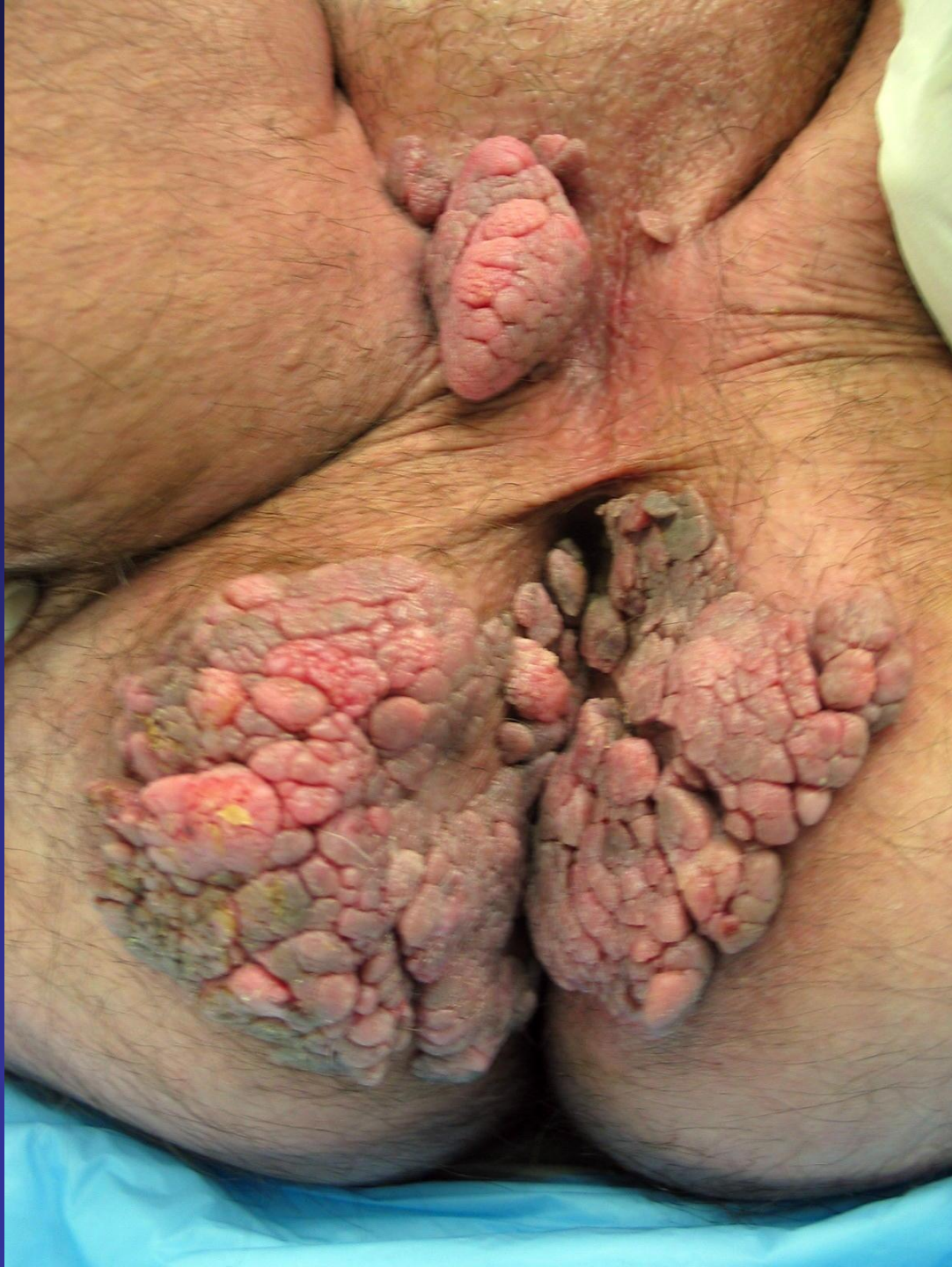


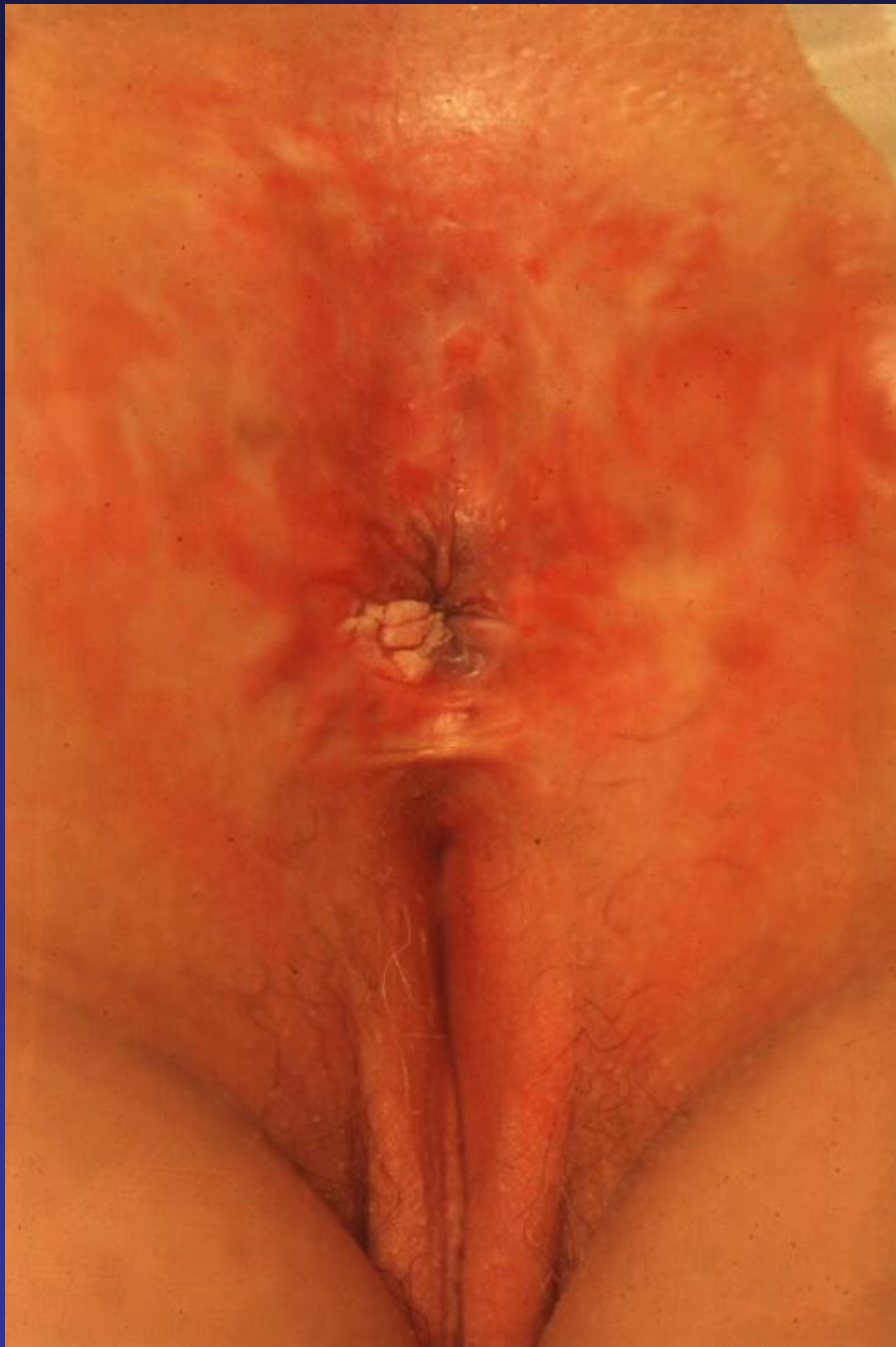
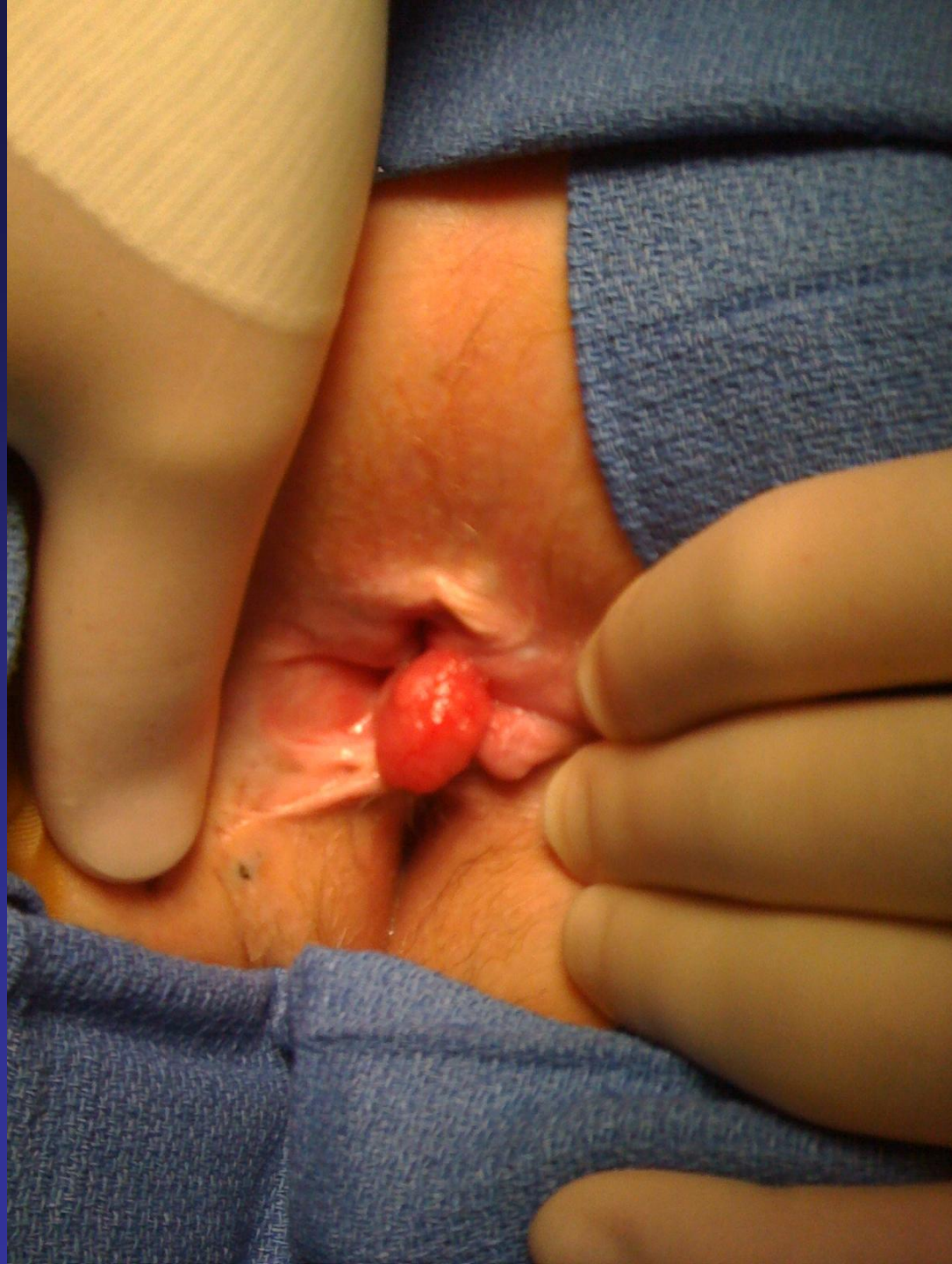




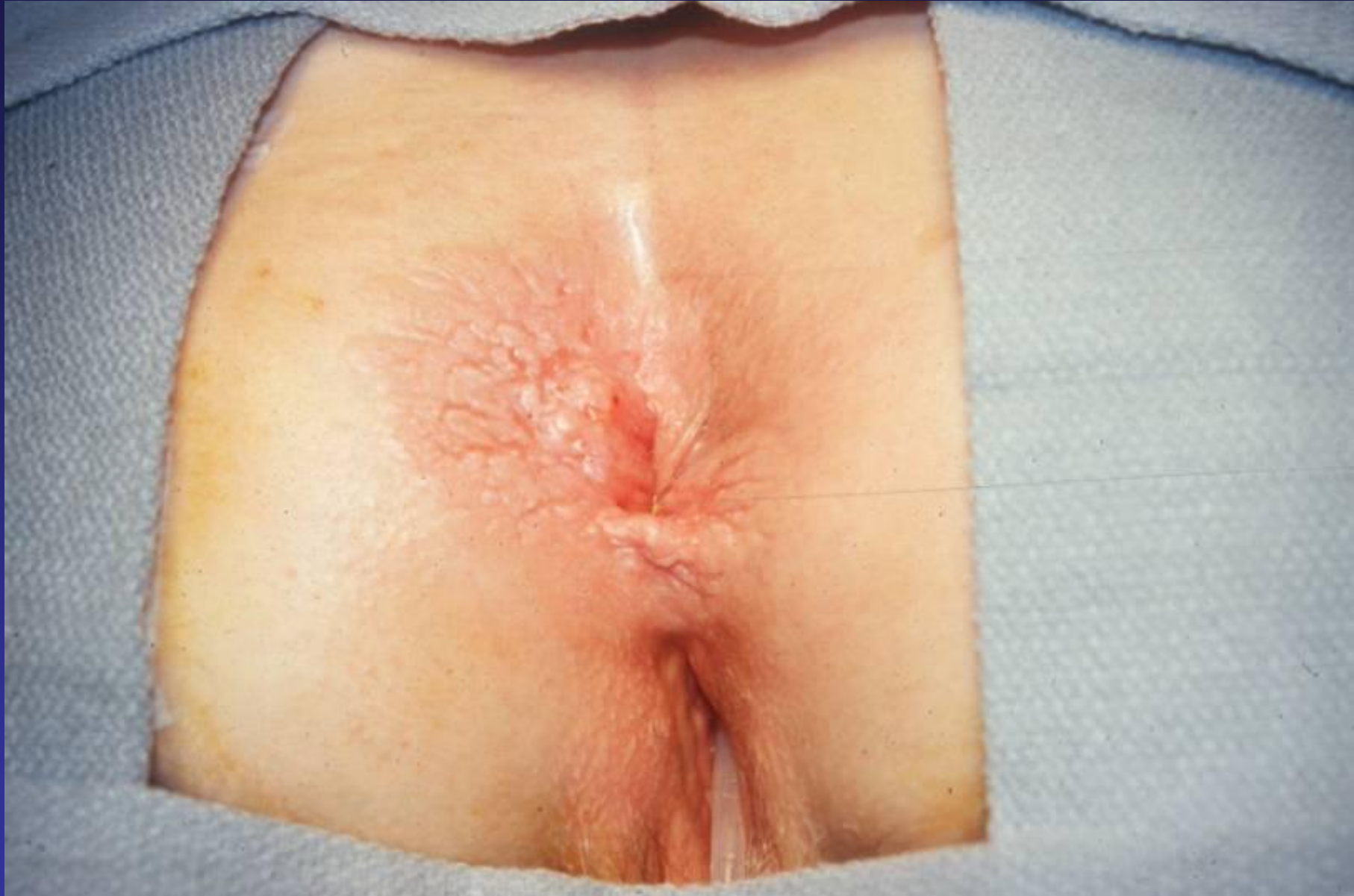


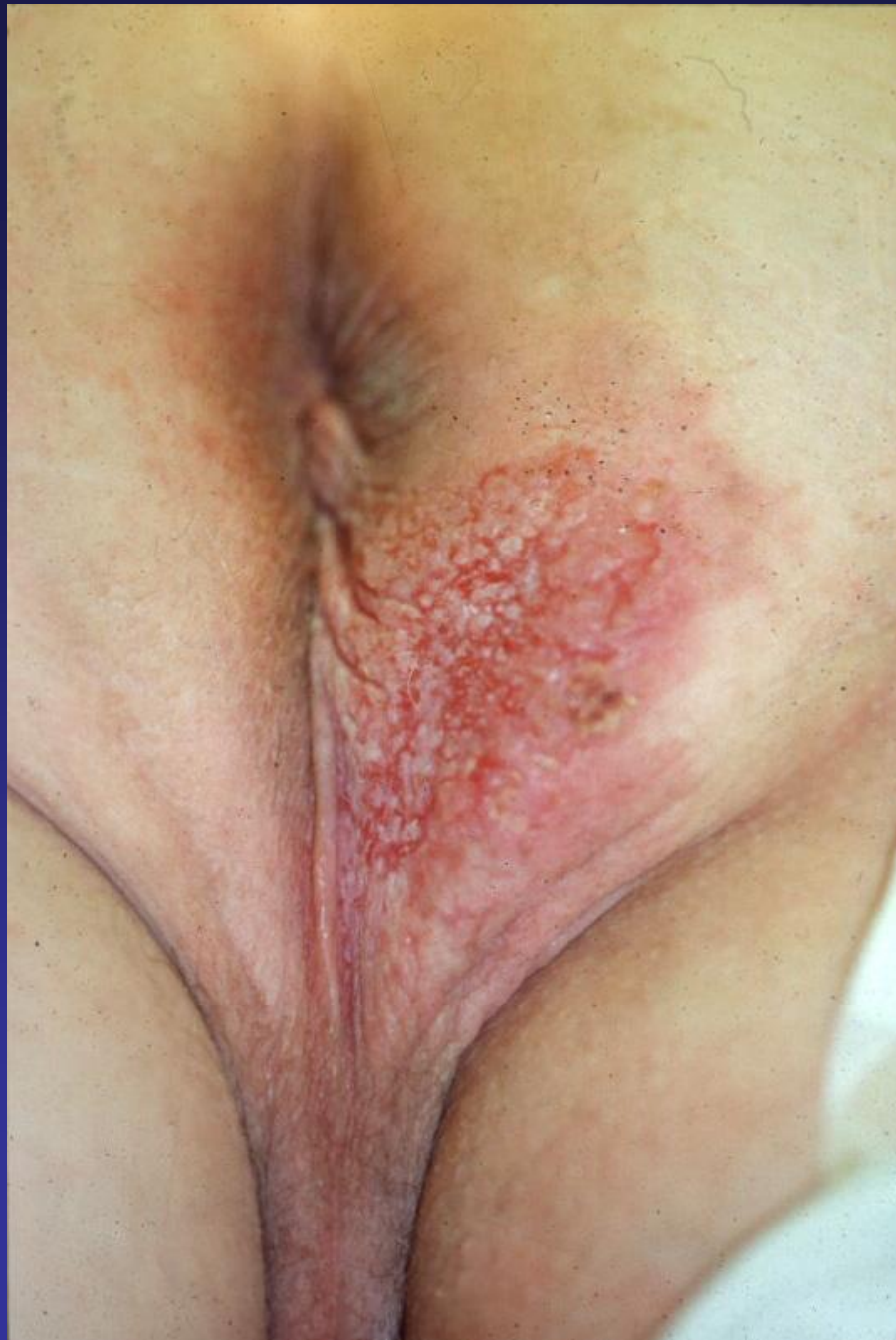









Stuff Happen \$

by Manny Gark



“...and don't forget,
abscess makes the
heart grow
fonder.”

-Groucho Marx



