

Gynecologic Ultrasound

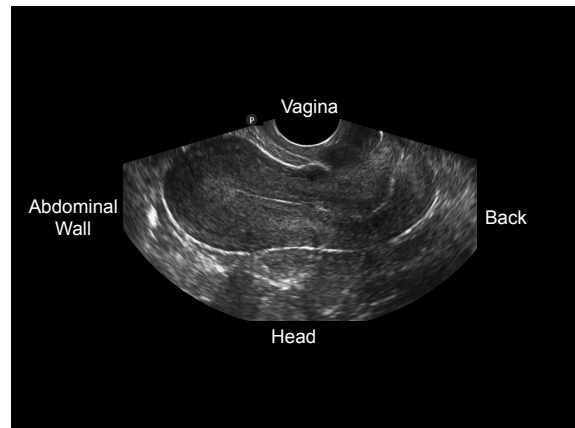
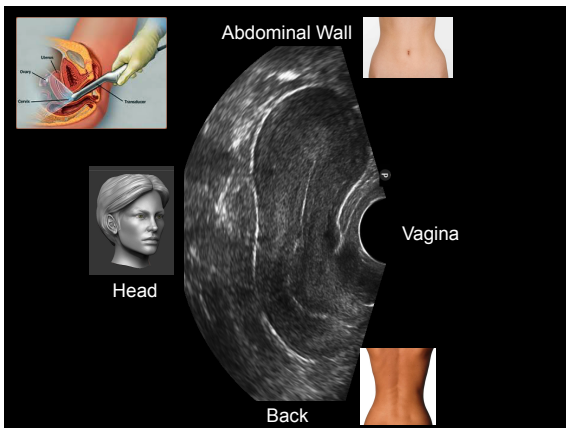
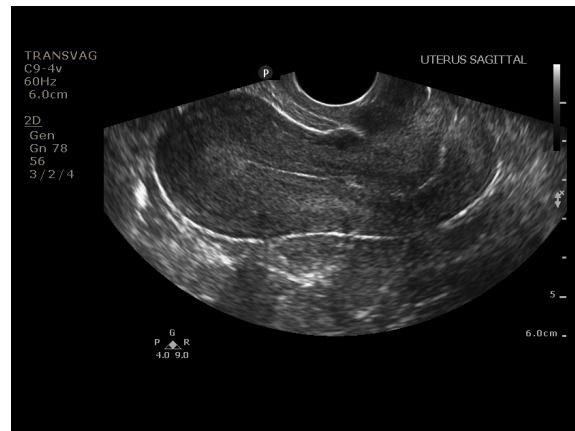James M. Shwayder, MD, JD
Professor and Chair
Obstetrics and Gynecology
University of Mississippi Medical Center
Jackson, Mississippi

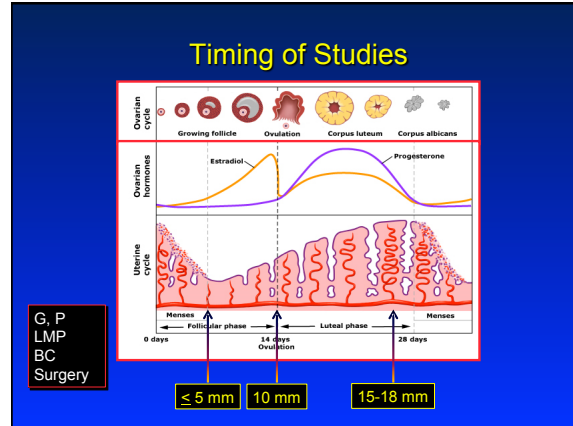
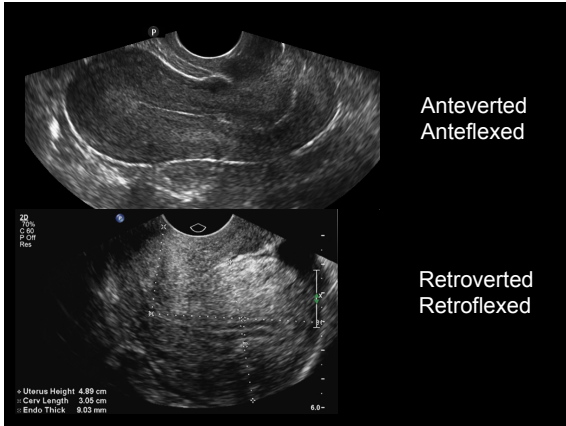
Gynecologic Ultrasound

James M. Shwayder, MD, JD

Disclosures: None

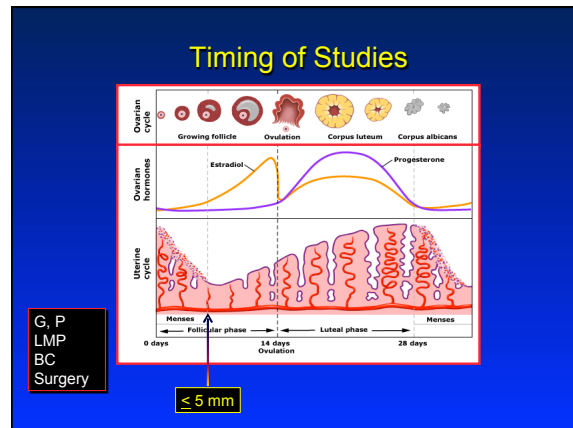
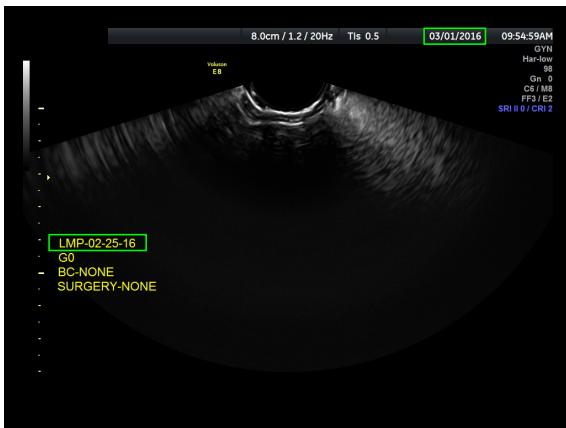
Performing Ultrasound

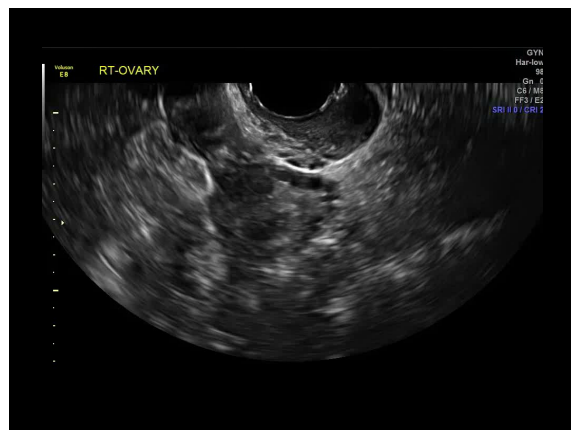
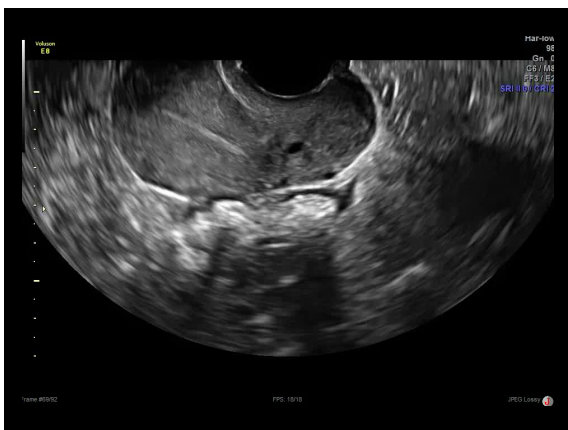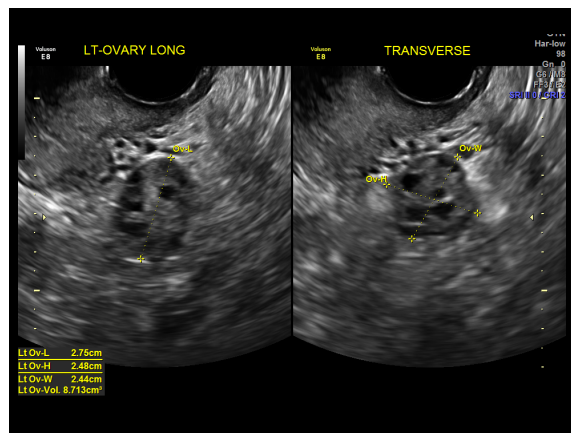
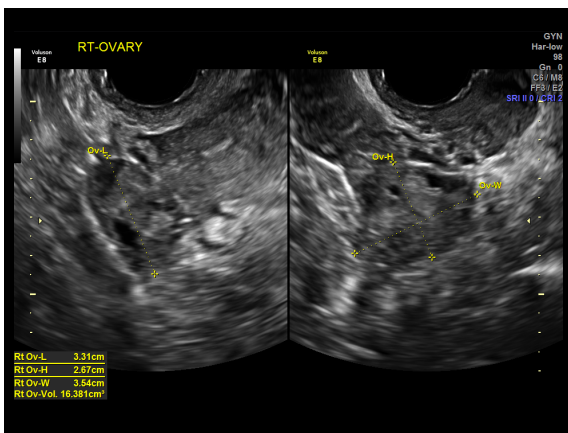
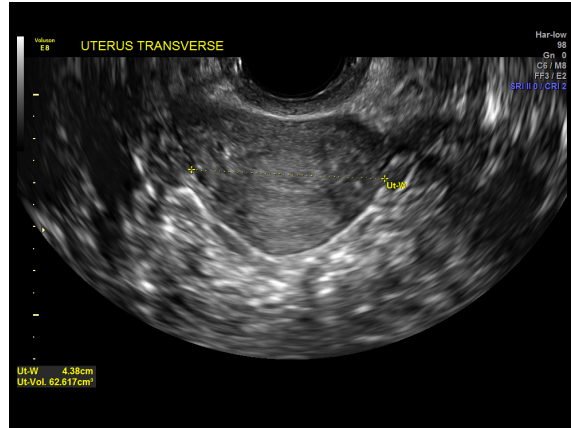

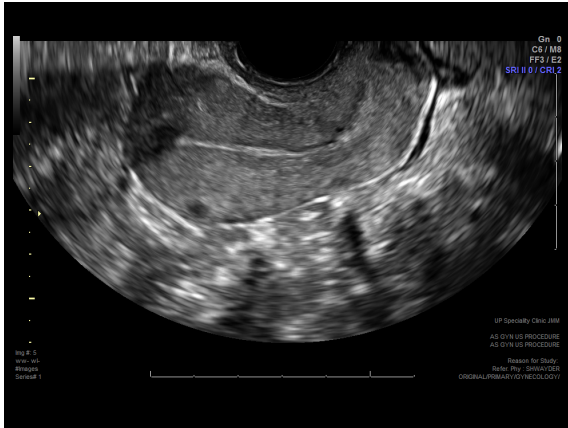
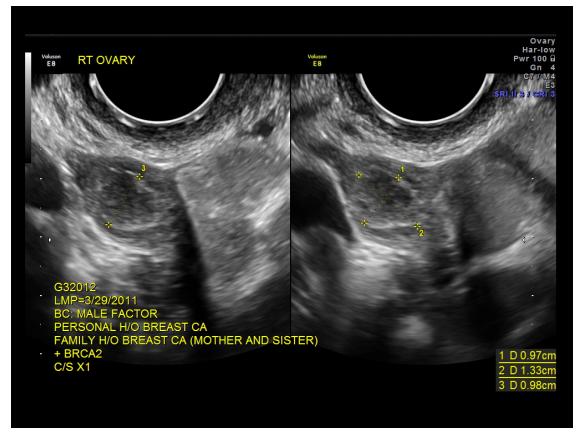
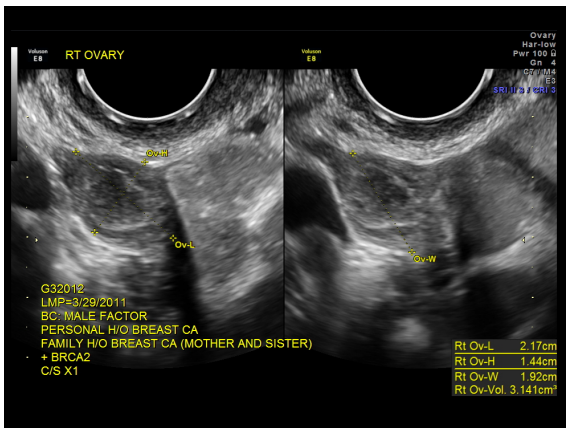
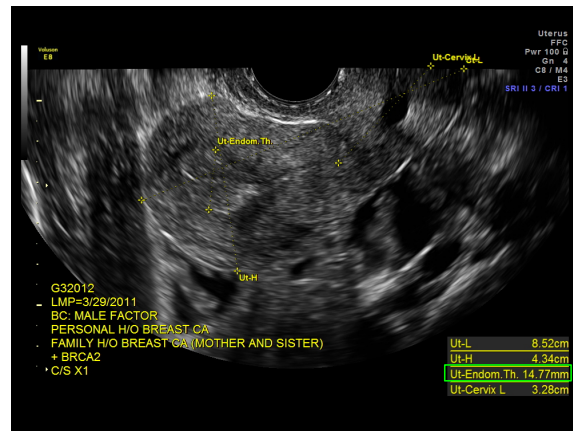
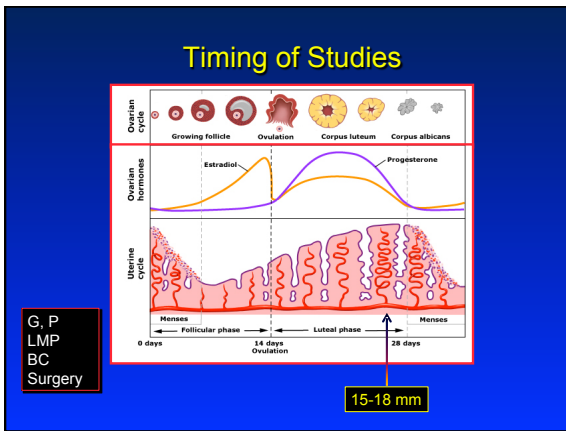


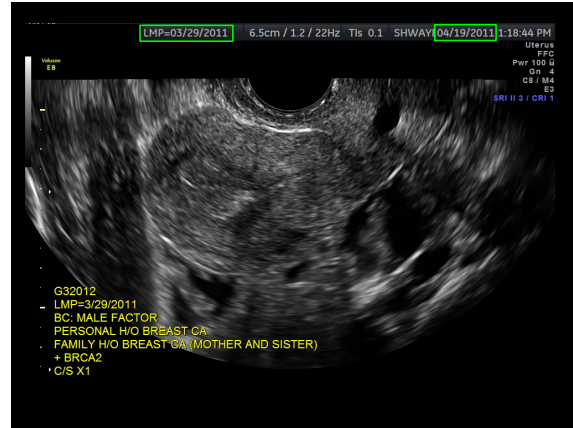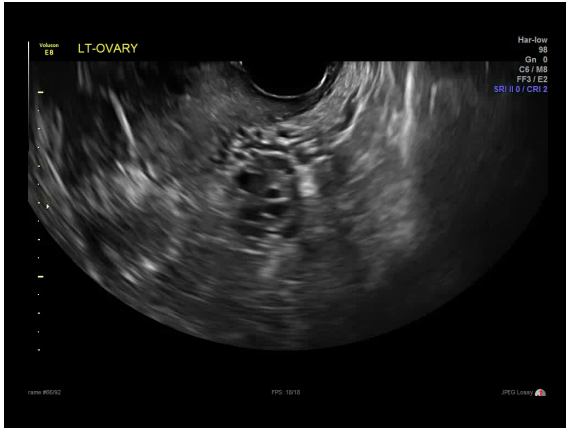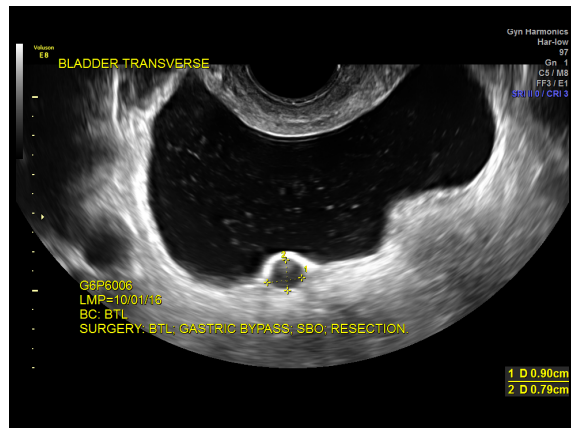
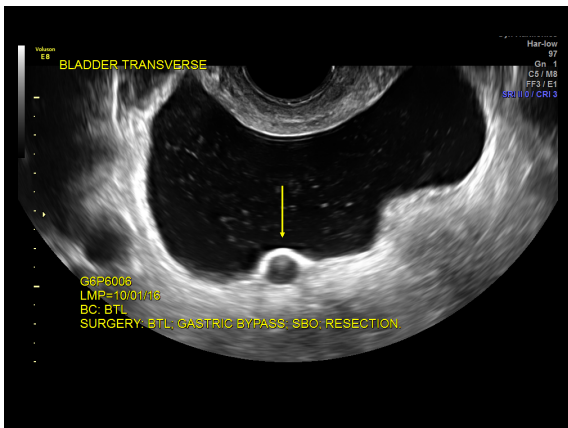
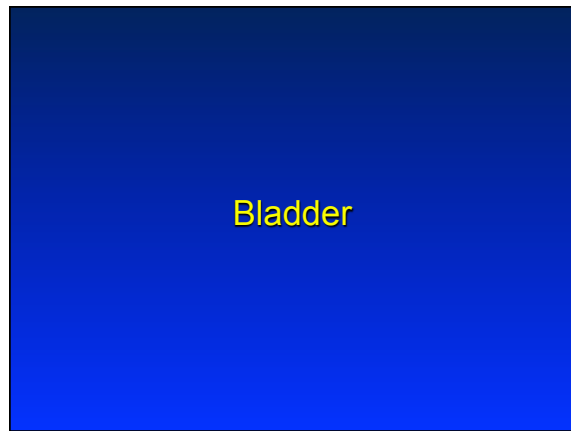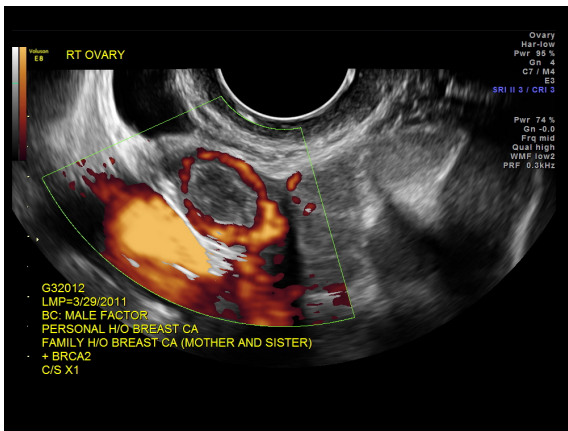
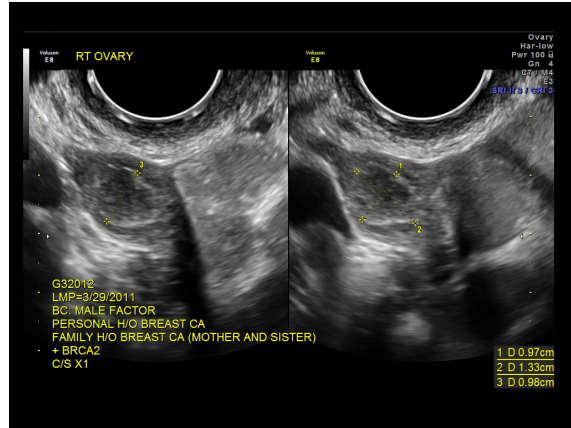
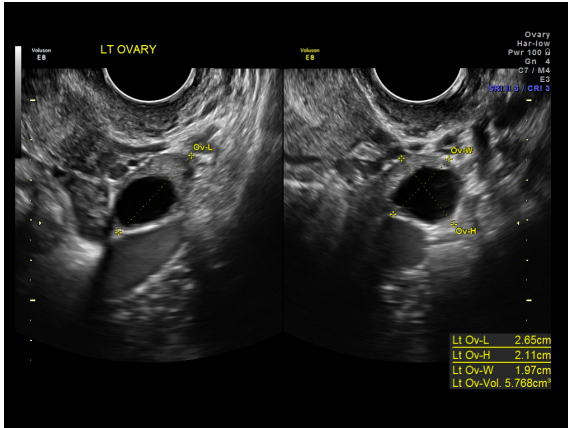
- ### Timing
- No suppression or irregular
 - At the end of menses
 - At the end of a withdrawal bleed
 - Suppression (LARC, OBCP, Depo-P)
Menopausal patients
 - Timing of the study is not critical

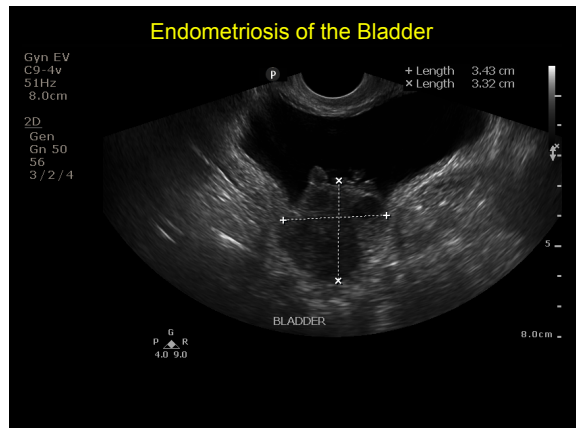
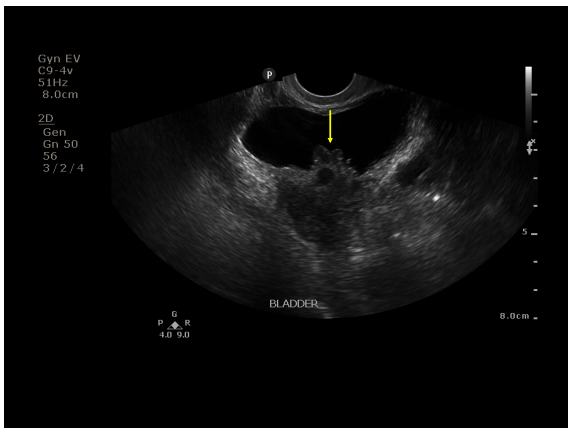
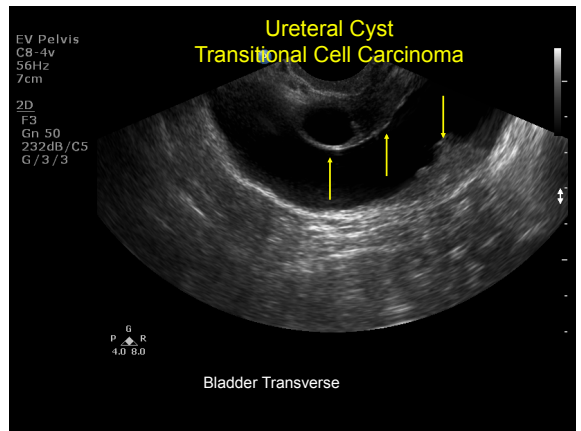
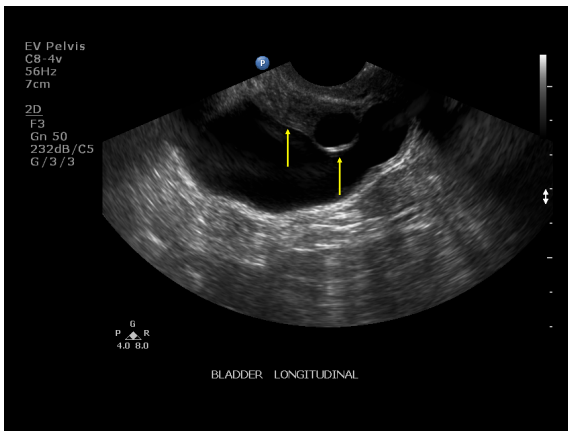
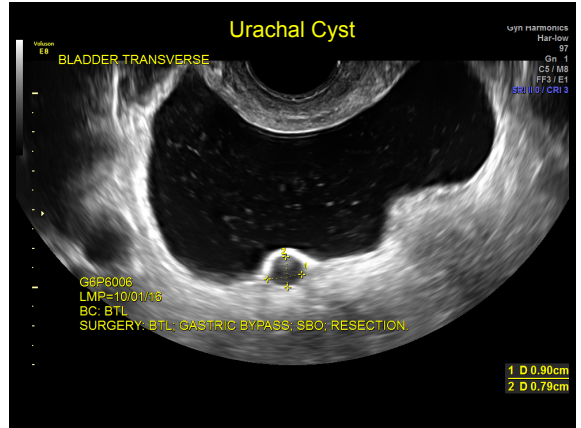
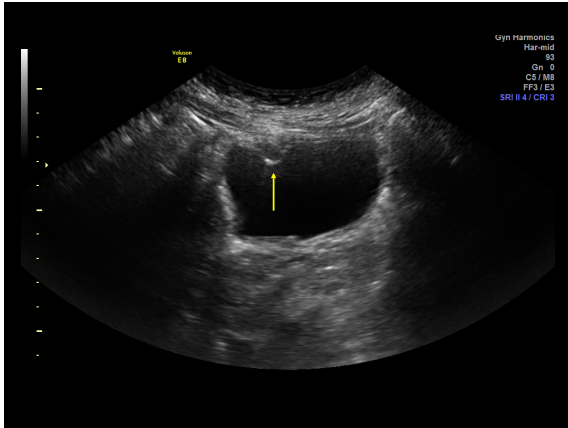
Normal Ultrasound











Leiomyosarcoma

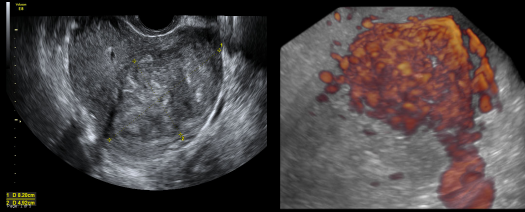
- **Prevalence**
 - 1 in 360 to 1 in 7400¹
- **Mortality**
 - 0.085% Open hysterectomy
 - 0.077% Laparoscopic hysterectomy
 - 17 more women would die from open surgery annually

J. Brown. JMIG 2014;21(6):970-71.

Color flow Doppler

- Typically flows around a leiomyoma
- Allows visualization of the anatomic location of flow
- Assists in identifying the primary vessel feeding the myoma
- Leiomyosarcoma may have bazaar flow pattern

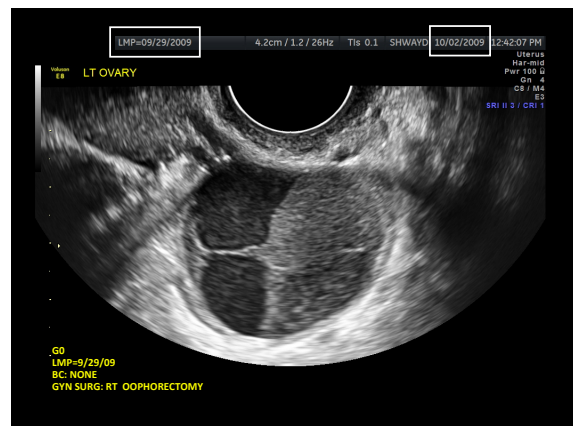
Color flow Doppler

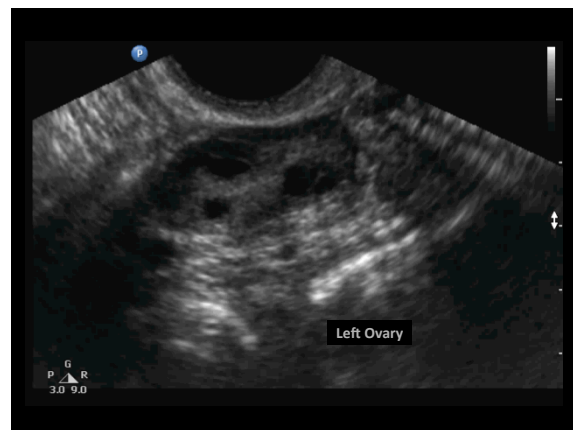
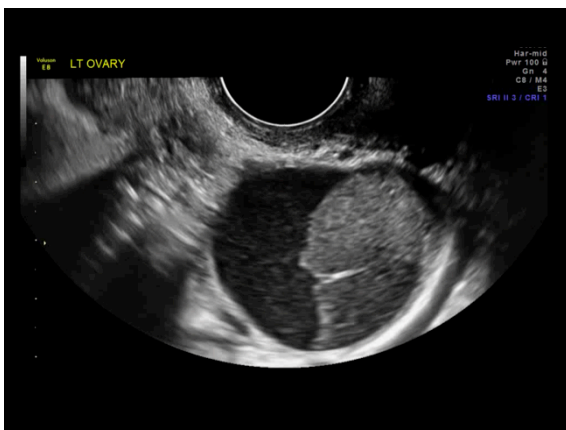
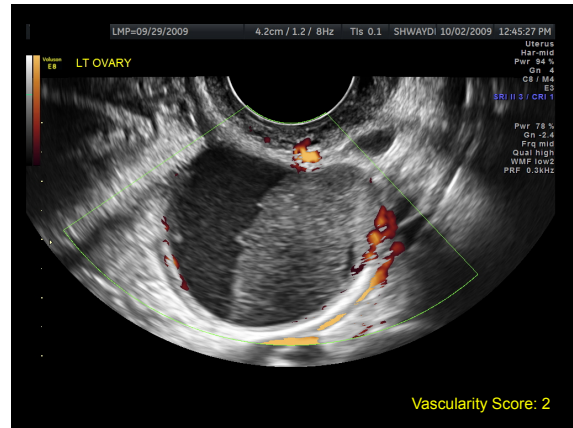
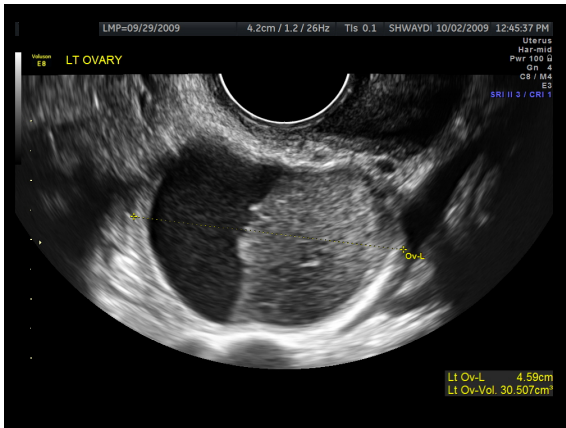


Adnexal Masses

Infertility - Mass

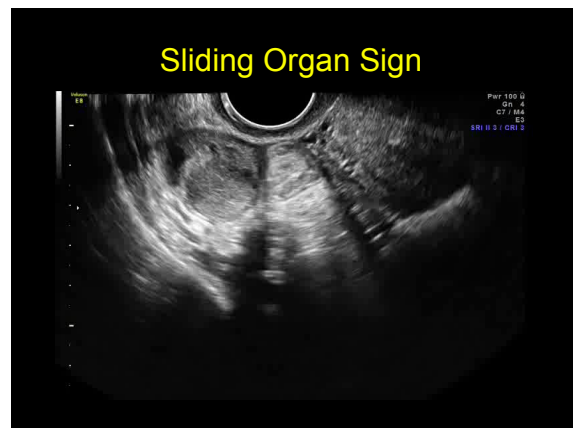32-year-old G0 presents for baseline ultrasound for ovulation induction.

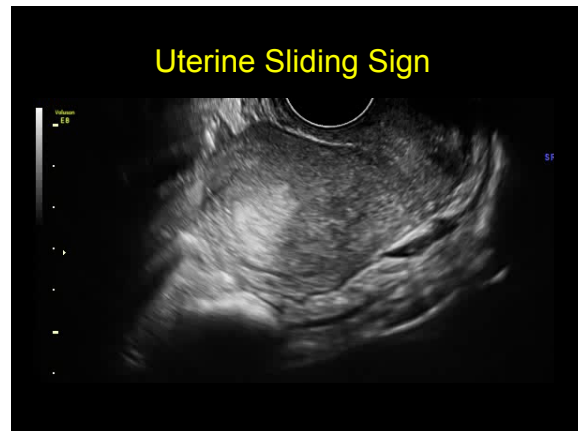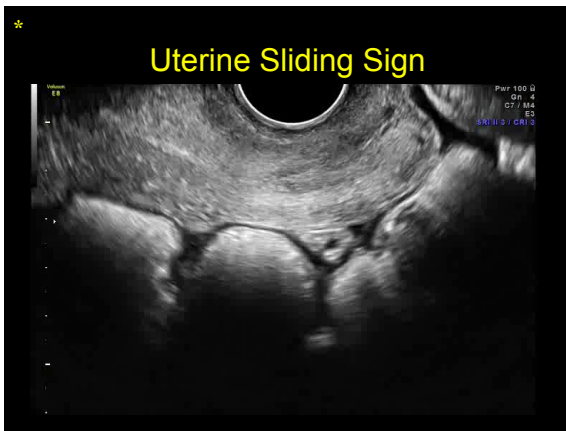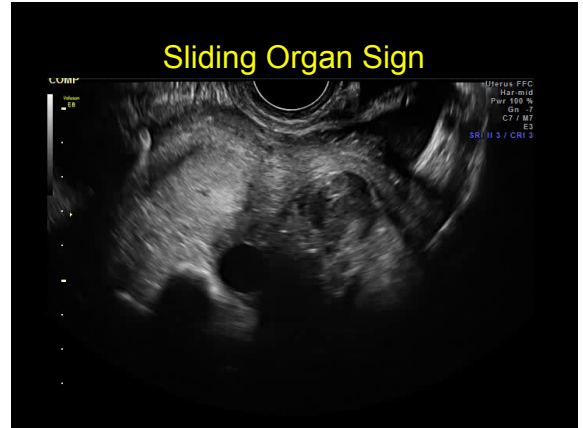
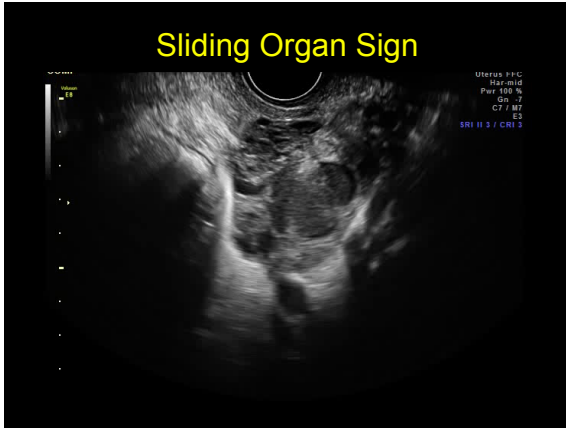




26 y.o. G0P0

- Primary dysmenorrhea
- Dyspareunia
- Dyschezia
- Anteverted uterus – fixed
- Fixed adnexa

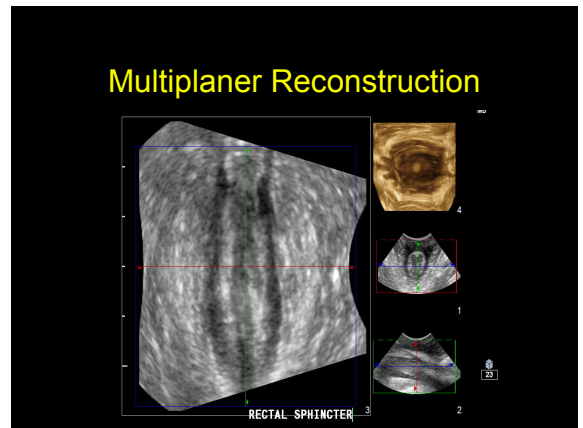


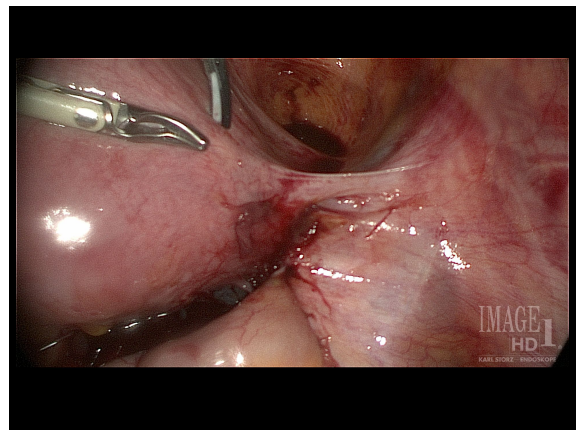
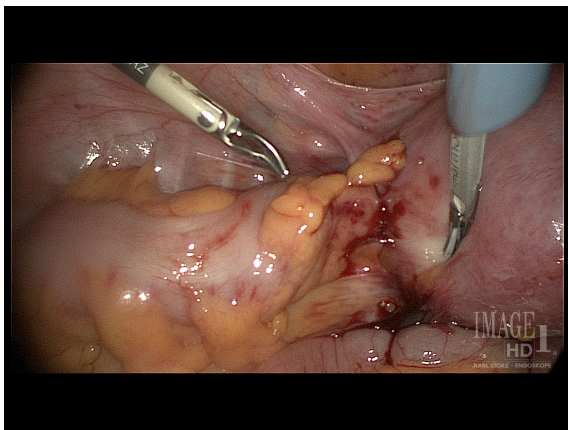
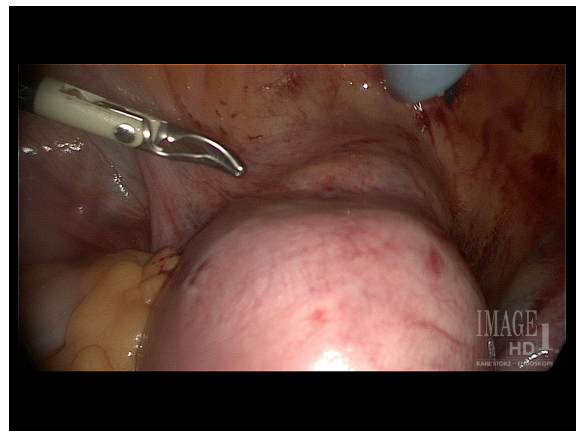
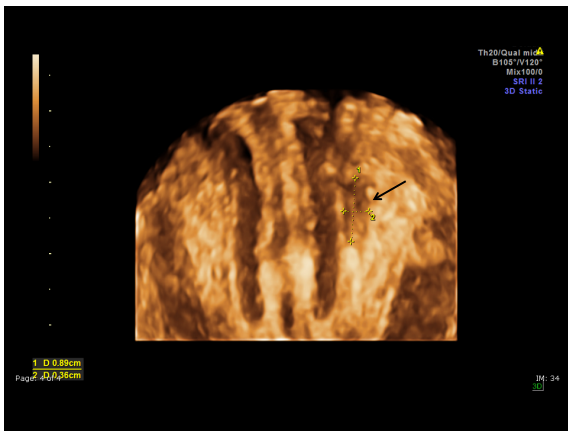
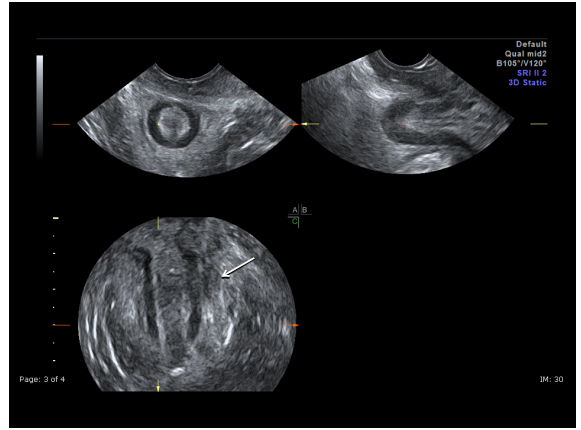
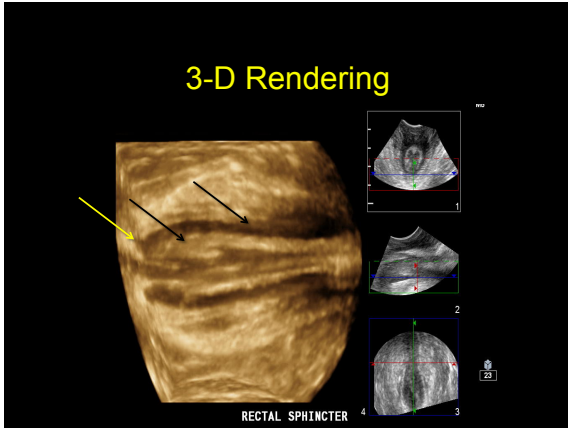


Uterine sliding sign Negative (no sliding)

Author	#	Sensitivity %	Specificity %	PPV %	NPV %	Accuracy %
Hudelist et al.	117	85	96	91	94	93.1
Reid et al.	100	83.3	97.1	92.6	93.2	93.0

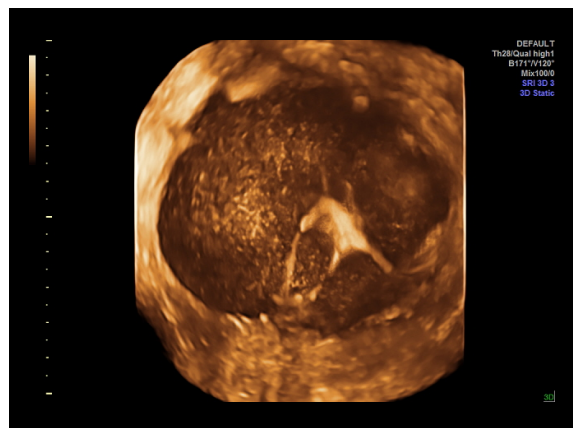
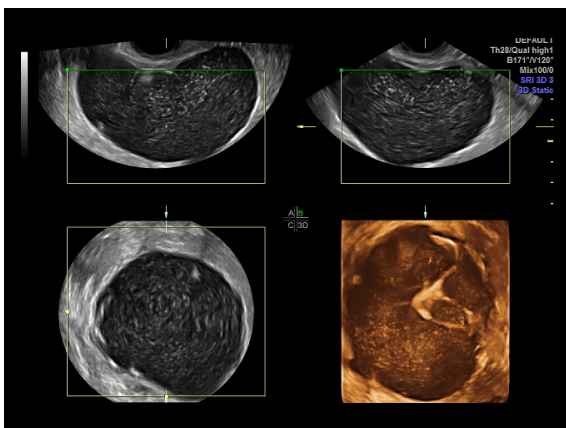
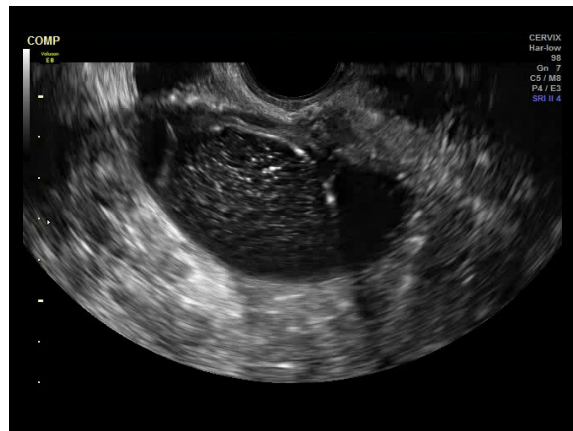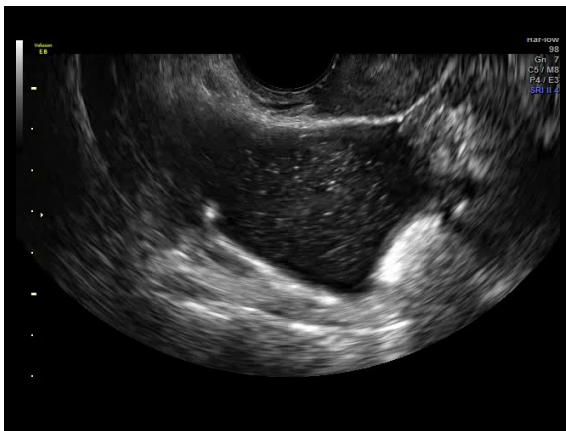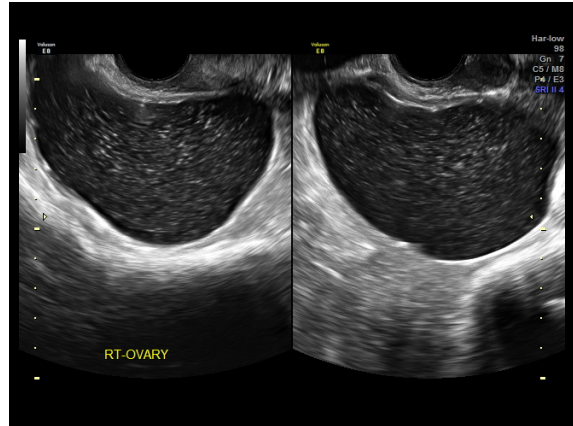
Hudelist et al. Ultrasound Obstet Gynecol 2013;41:692-695.
 Reid et al. Ultrasound Obstet Gynecol 2013;41:685-691.

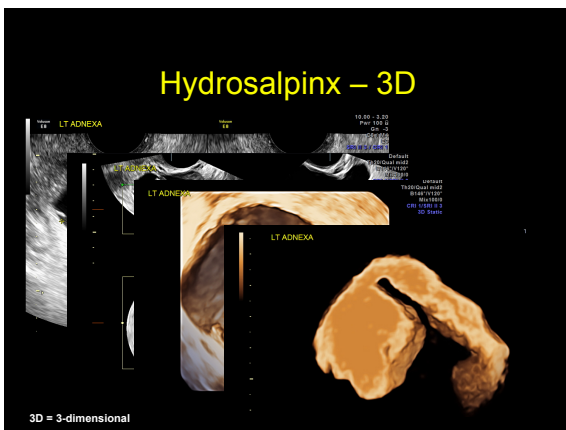
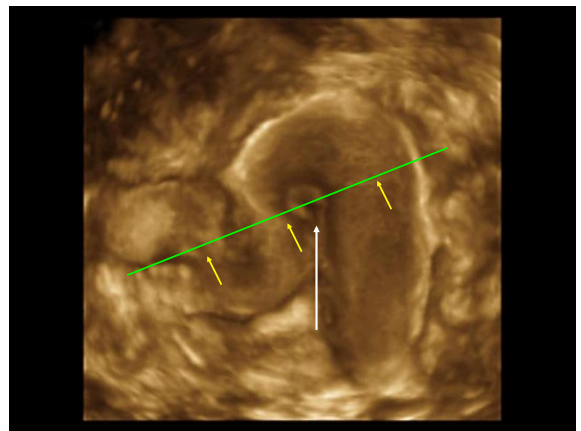
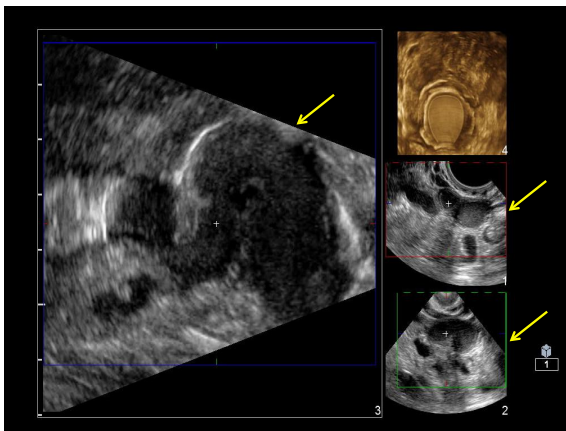
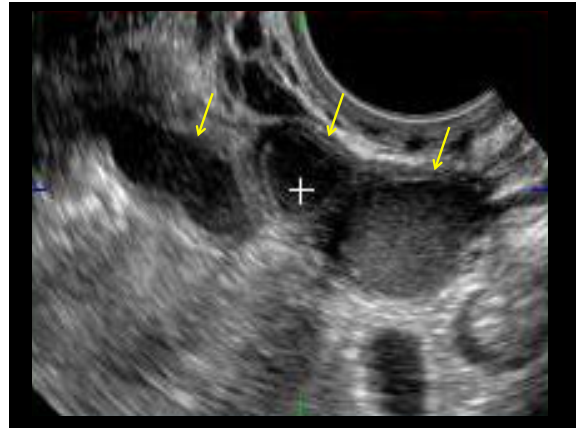
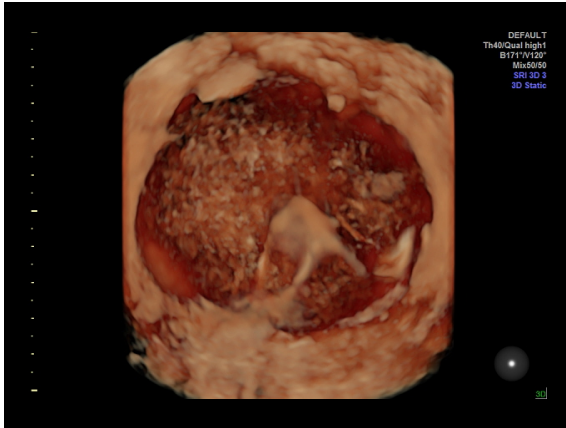




35 y.o. G4P0040

- Right ovarian cystic mass
- Medical conditions
 - HIV
 - H/O stroke (cocaine)
 - Asthma
 - Hypothyroidism
 - Hearing loss
- CA125 = 20.4





28 y.o. G3P2012

- c/o cramping pain, worse with her menses
- BC: IUD x 1 year
- hCG: negative
- Exam
 - Uterus: Anteverted, normal size, with mild tenderness
 - IUD strings not visible
 - Adnexa: "right adnexal mass"

